This is a digital copy of a book that was preserved for generations on library shelves before it was carefully scanned by Google as part of a project to make the world's books discoverable online.

It has survived long enough for the copyright to expire and the book to enter the public domain. A public domain book is one that was never subject to copyright or whose legal copyright term has expired. Whether a book is in the public domain may vary country to country. Public domain books are our gateways to the past, representing a wealth of history, culture and knowledge that's often difficult to discover.

Marks, notations and other marginalia present in the original volume will appear in this file - a reminder of this book's long journey from the publisher to a library and finally to you.

Usage guidelines

Google is proud to partner with libraries to digitize public domain materials and make them widely accessible. Public domain books belong to the public and we are merely their custodians. Nevertheless, this work is expensive, so in order to keep providing this resource, we have taken steps to prevent abuse by commercial parties, including placing technical restrictions on automated querying.

We also ask that you:

+ *Make non-commercial use of the files* We designed Google Book Search for use by individuals, and we request that you use these files for personal, non-commercial purposes.
+ *Refrain from automated querying* Do not send automated queries of any sort to Google's system: If you are conducting research on machine translation, optical character recognition or other areas where access to a large amount of text is helpful, please contact us. We encourage the use of public domain materials for these purposes and may be able to help.
+ *Maintain attribution* The Google "watermark" you see on each file is essential for informing people about this project and helping them find additional materials through Google Book Search. Please do not remove it.
+ *Keep it legal* Whatever your use, remember that you are responsible for ensuring that what you are doing is legal. Do not assume that just because we believe a book is in the public domain for users in the United States, that the work is also in the public domain for users in other countries. Whether a book is still in copyright varies from country to country, and we can't offer guidance on whether any specific use of any specific book is allowed. Please do not assume that a book's appearance in Google Book Search means it can be used in any manner anywhere in the world. Copyright infringement liability can be quite severe.

About Google Book Search

Google's mission is to organize the world's information and to make it universally accessible and useful. Google Book Search helps readers discover the world's books while helping authors and publishers reach new audiences. You can search through the full text of this book on the web at `http://books.google.com/`

LANE MEDICAL LIBRARY STANFORD
2 45 0175 6594

LANE
MEDICAL LIBRARY
SEAL OF THE LELAND STANFORD JUNIOR UNIVERSITY
SEMPER VIRENS
1885
Gift
Dr.Gaber's Library

R. P. Gobin

A

Case of a boy fourteen years of age. Comminuted fracture of the surgical neck of the humerus (X-ray taken five weeks after the injury). Notice rotation of the head of the bone, callus, fragment between shaft and epiphysis (C. B. Porter).

B

After operation. Silver wire seen *in situ* (C. B. Porter). Same case as that of figure A.

C

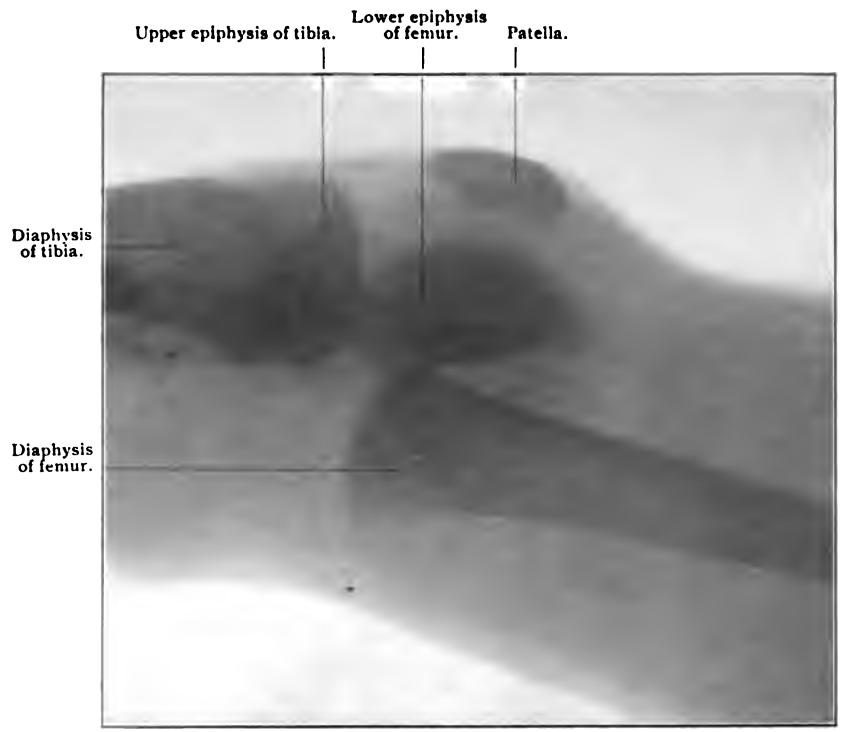

Separation of the lower femoral epiphysis in a boy aged eleven years, taken before operation. Open incision, reduction, recovery with a useful knee (see p. 315). (Scudder.)

THE TREATMENT

OF

FRACTURES

BY

CHARLES LOCKE SCUDDER, M.D.

ASSISTANT IN CLINICAL AND OPERATIVE SURGERY, HARVARD UNIVERSITY MEDICAL SCHOOL

SURGEON TO THE OUT-PATIENT DEPARTMENT, MASSACHUSETTS GENERAL HOSPITAL

Third Edition, Thoroughly Revised

With 645 Illustrations

LANE LIBRARY

PHILADELPHIA AND LONDON

W. B. SAUNDERS & COMPANY

1902

Copyright, 1900, by W. B. Saunders

Copyright, 1901, by W. B. Saunders & Company

Copyright, 1902, by W. B. Saunders & Company

Registered at Stationers' Hall, London, England

LANE LIBRARY

TO

ARTHUR TRACY CABOT, A.M., M.D.

PREFACE TO THE THIRD EDITION

In this edition several new but not uncommon fractures are described. A chapter on gunshot fractures of the long bones is added. A careful review of the reports of surgeons in the field during recent wars, together with the very great assistance afforded by Mr. Makins' valuable systematic contribution to gunshot fractures—"Surgical Experiences in South Africa,"—has made it possible to present concisely important facts regarding fractures of bone produced by the small-caliber bullet. Through the courtesy of Mr. Makins and his publishers I am able to illustrate this chapter with satisfactory plates. The general text of the book has been carefully reviewed. A carefully prepared index is added.

I wish to thank Drs. Putnam, Walton, Bullard, and Paul for reviewing the chapters upon fractures of the Skull and Spine. Photographs are introduced in place of many of the drawings. The uses of plaster-of-Paris as a splint material are more fully illustrated.

The kindness and liberality of the publishers have again enabled me to enhance the value of the book through freedom of illustration.

Charles L. Scudder

Boston, Mass., *August, 1902*

101344

LAME LIBRARY

PREFACE TO THE FIRST EDITION

THE general employment of anesthesia in the examination and the initial treatment of fractures, especially of those near or involving joints, has made diagnosis more accurate and treatment more intelligent. The application of the Röntgen ray to the diagnosis of fracture of bone has already contributed much toward an accurate interpretation of the physical signs of fracture. This greater certainty in diagnosis has suggested more direct and simpler methods of treatment. Antisepsis has opened to operative surgery a very profitable field in the treatment of fractures. The final results after the open incision of closed fractures emphasize the fact that anesthesia, antisepsis, and the Röntgen ray are making the knowledge of fractures more exact, and their treatment less complicated. The attention of the student is diverted from theories and apparatus to the actual conditions that exist in the fractured bone, and he is encouraged to determine for himself how to meet the conditions found in each individual case of fracture.

This book is intended to serve as a guide to the practitioner and student in the treatment of fractures of bone. In the following pages many of the details in the treatment of fractures are described. So far as possible these details are illustrated. A few very unusual fractures are omitted. Mechanical simplicity is advocated. An exact knowledge of anatomy combined with accurate observation is recognized as the proper basis for the diagnosis and treatment of fractures. The expressions "closed" and "open" fracture are used in place of "simple" and "compound" fracture. "Closed" and "open" express definite conditions, referring to the freedom from, or liability to, bacterial infection. The old expressions are misleading despite their long usage. Theories of treatment are not discussed. Types of

dressings for special fractures are described. Many illustrative clinical cases are omitted purposely.

The tracings of the Röntgen rays, which have been very generally used to illustrate the sites and the displacements of fractures, have been the subject of careful study. Each tracing represents the combined interpretation of the plate made by skilled observers who were in every instance familiar with the clinical aspects of the case. The writings of many who have contributed their experience to the literature of fractures have been consulted. Those to whom I feel indebted for suggestions are mentioned in the section on Bibliography. References to literature are not made in the text.

I take this opportunity to extend my thanks to the members of the Surgical Staff of the Massachusetts General Hospital for their courtesy in permitting me to study cases of fracture of the lower extremity in the wards of the hospital, and to Professor Thomas Dwight for the use of valuable anatomical material. I also thank Dr. F. J. Cotton for an untiring interest in the production of most of the drawings, and in the search for fracture literature. The half-tones are made from photographs taken under the direct superintendence of the author. Due credit for illustrations not original is given next the legend.

I wish to thank Mr. Walter Dodd for his courtesy and interest connected with the production of the Röntgen-ray plates, and Dr. H. P. Mosher for kind assistance.

The chapter on the Röntgen ray is written by Dr. E. A. Codman.

CHARLES L. SCUDDER

189 BEACON STREET, BOSTON, MASS.

April, 1900

TABLE OF CONTENTS

CHAPTER I — PAGE

Fractures of the Skull 17
Fractures of the Vault 24
Fractures of the Base 26
Treatment 34
Later Results of Fracture of the Skull 38

CHAPTER II

Fractures of the Nasal Bones 44
The Nasal Septum 47
Treatment 49
Fractures of the Malar Bone 52
Treatment 55
Fracture of the Superior Maxilla 56
Treatment 57
Fractures of the Inferior Maxilla 59
Treatment 61

CHAPTER III

Fractures of the Vertebræ 72
Treatment 81

CHAPTER IV

Fractures of the Ribs 94

CHAPTER V

Fractures of the Sternum 100

CHAPTER VI

Fractures of the Pelvis 102
Treatment 105
Rupture of the Urethra 107
Rupture of the Urinary Bladder 108

CHAPTER VII

Fractures of the Clavicle 110
Treatment in Adults 113
Treatment in Children 117
Operative Treatment 120

CHAPTER VIII

PAGE

FRACTURES OF THE SCAPULA 121
Treatment 123

CHAPTER IX

FRACTURES OF THE HUMERUS 125
Fractures of the Upper End of the Humerus 125
Diagnosis 129
Treatment 140
Fracture of the Upper End of the Humerus with a Dislocation of the Upper Fragment 146
Fractures of the Shaft of the Humerus 147
Fractures of the Shaft with Little Displacement 151
Fractures of the Shaft with Considerable Displacement 156
Fractures of the Shaft in the New-born 158
The Musculospiral Nerve in Fracture of the Humerus 159
Malignant Disease Associated with Fracture of Bone 162
Fractures of the Elbow 162
Diagnosis 169
Treatment 181

CHAPTER X

FRACTURES OF THE BONES OF THE FOREARM 192
Fractures of Both Radius and Ulna 192
Treatment 201
Nonunion of Fractures 212
Fractures of the Olecranon 214
Treatment 217
Tetanus 223
Colles' Fracture 223
Diagnosis 231
Treatment 236

CHAPTER XI

FRACTURES OF THE CARPUS, METACARPUS, AND PHALANGES 246
Fractures of the Carpus 246
Fractures of the Metacarpus 249
Fractures of the Phalanges 257
Open Fractures of the Phalanges 259

CHAPTER XII

FRACTURES OF THE FEMUR 260
Fracture of the Hip or Neck of the Femur 260
Treatment 269
Operative Treatment 277
Fracture of the Neck of the Femur in Childhood 277

PAGE

Fracture of the Shaft of the Femur 280
Treatment 283
Subtrochanteric Fracture of the Femur 299
Supracondyloid Fracture of the Femur 300
Ambulatory Treatment of Fracture of the Thigh 303
FRACTURE OF THE THIGH IN CHILDHOOD 309
Separation of the Lower Epiphysis of the Femur 314
Treatment 318
Traumatic Gangrene 321
Septicemia 321
Malignant Edema 321
Fat Embolism 322

CHAPTER XIII

FRACTURES OF THE PATELLA 324
Treatment 329
Open Fracture of the Patella 338
Operation in Recent Closed Fractures of the Patella 342

CHAPTER XIV

FRACTURES OF THE LEG 346
Treatment 356
Fractures with Little or No Displacement 357
Fractures with Considerable Immediate Swelling 359
Fractures Difficult to Hold Reduced 370
Treatment of Open Fractures of the Leg 374
Thrombosis and Embolism 383
POTT'S FRACTURE 384
Treatment 386
Open Pott's Fracture 398

CHAPTER XV

FRACTURES OF THE BONES OF THE FOOT 400
Fracture of the Astragalus 400
Open Fracture of the Astragalus and Os Calcis 404
Fracture of the Metatarsal Bones 405
Fracture of the Phalanges 406

CHAPTER XVI

ANATOMICAL FACTS REGARDING THE EPIPHYSES 407

CHAPTER XVII

GUNSHOT FRACTURES OF BONE 413
Treatment 419

CHAPTER XVIII PAGE

THE RÖNTGEN RAY AND ITS RELATION TO FRACTURES 425
BY E. A. CODMAN, M.D.

CHAPTER XIX

THE EMPLOYMENT OF PLASTER-OF-PARIS 441

CHAPTER XX

THE AMBULATORY TREATMENT OF FRACTURES 462

BIBLIOGRAPHY 471

INDEX 475

THE

TREATMENT OF FRACTURES

CHAPTER I

FRACTURES OF THE SKULL

It is unwise to consider the treatment of fracture of the skull apart from a more or less systematic review of traumatic lesion of the brain.

The skull is the brain's protection. In cases of fracture of the skull the injury to the brain is of paramount importance. The immediate damage to the brain may be caused by direct pressure of bony fragments, by pressure due to hemorrhage from torn vessels within the skull, by bruising of the brain itself, or by cerebral edema. Great interest attaches to serious head-injuries, not only because the brain may be damaged, but more especially because the lesions are often obscured by an intact scalp. A proper determination of the conditions existing after a given head-accident necessitates careful observation of symptoms, combined with good judgment in interpreting the signs present.

Concussion and Contusion of the Brain.—A concussion and a contusion of the brain associated with minute bruising of brain-tissue will exist after all serious injuries to the skull.

The symptoms of concussion are varied according to the severity of the injury. Following slight concussion, the individual is stunned by the accident; there is simple vertigo, possibly mental confusion lasting but a short time. After severe concussion there will follow a momentary loss of consciousness, or there may be unconsciousness of longer duration. Vomiting may occur. Head-

ache will probably be present. Following a still more severe concussion, the patient will be profoundly unconscious for a long period. The sphincters may be relaxed; hence involuntary micturition and defecation will occur when the bladder and rectum become overdistended. Retention of urine and feces is the sign immediately after the injury. Incontinence is the evidence of overdistention of the viscus in these cases. The pulse will become feeble and slow along with the general systemic depression. The pupils still react to light. The temperature will be subnormal. It is impossible clinically to distinguish between concussion and contusion of the brain. The pathological differences are more or less artificial.

Laceration of the Brain.—If there is laceration of the brain, the symptoms of concussion will be present to a marked degree, and will be characterized by immediate, pronounced, and long-continued unconsciousness. After recovery from the initial shock of the accident fever will be present, which may rise to 103° or 104° F. Concussion alone is never associated with feverishness. Early fever is a sign of laceration. Mental irritability and restlessness will mark returning consciousness. If the motor areas of the brain are involved, signs of irritation will appear—namely, muscular twitchings and spasms according to the motor centers implicated.

Compression of the Brain.—Slight hemorrhages do not cause symptoms of compression; neither do slight depressions of the cranial bones. Before symptoms of compression appear, the cranial contents must be impinged upon to a very considerable extent. If the compression is sudden and limited, there is an irritation of the parts involved, which is manifested by restlessness and delirium and by twitching of certain groups of muscles; the pulse is hard and slow. If the compression is gradual, whether it be localized or diffused, the brain accommodates itself for some time to the new conditions; the appearance of the symptoms of local pressure is delayed, although they may be relatively sudden in their onset. Following the muscular spasms and twitchings due to the sudden onset of pressure there may appear symptoms of paresis and paralysis. Loss of power in the face or arm or leg indicates a lesion about the fissure of Rolando, upon the opposite

side. Loss of power, for example, in the right arm and right leg indicates that the brain lesion is about the fissure of Rolando upon the left side of the brain. If there is pressure upon the third nerve at the base of the skull, dilatation of the pupil upon the side opposite to the pressure will be noticed. This pupil will not react to light. As the pressure of the hemorrhage increases, the symptoms will again become more general; convulsive movements of the limbs and body appear, and the drowsiness or stupor increases to profound unconsciousness; the pulse becomes rapid and small; and the respiration frequent,

Fig. 1.—Fracture of skull with middle meningeal hemorrhage. Compression of brain by blood.

Fig. 2.—Fracture of skull with depressed fragments. Compression of brain by bone.

shallow, and sighing, or it passes into stertor and Cheyne-Stokes' breathing as the condition becomes immediately grave; the temperature rises high. Focal symptoms may exist from pressure by bone or blood-clot, apart from loss of consciousness.

Extradural Hemorrhage (see Figs. 1, 2).—A most important symptom of intracranial hemorrhage is the interval of consciousness that exists from the time of the injury to the onset of unconsciousness. This period of consciousness may be preceded by the temporary or prolonged unconsciousness of concussion. Unconsciousness in cases of intracranial hemorrhage is due to an increase

of the intracranial pressure caused by the presence of free blood. An interval of consciousness exists in these instances in from one-half to two-thirds of all cases. In the cases of hemorrhage which occur without an interval of consciousness (unconsciousness coming on immediately upon the receipt of the injury) it must be that the injury is so severe that the unconsciousness caused by the concussion and laceration of the brain is continuous with the unconsciousness from hemorrhage. The unconsciousness of concussion is continued over into the coma of compression. The duration of the interval of consciousness may vary within very wide limits; it may be a few moments, it may be three months.

Fig. 3.—Frontal section of skull. Middle meningeal hemorrhage. The dura bulges inward toward skull cavity (diagram).

Fig. 4.—A case of rupture of middle meningeal artery. Preparation of dura viewed from outer side (Warren Museum).

The sources of intracranial hemorrhage, whether from the middle meningeal artery (see Fig. 3) or its branches (see Fig. 4), from the middle cerebral arteries, from the veins of the pia mater, from the sinuses of the brain, or from lacerated brain-tissue, can not be easily differentiated short of operative procedure. There is one condition which is not to be overlooked in connection with the question of hemorrhage—namely, the period of semiconsciousness which sometimes follows concussion and laceration, and gives rise to the suspicion of some more serious gross lesion. To illustrate: A young girl received a severe blow upon the head. A true period

of unconsciousness followed. There were no external evidences of hemorrhage. Convulsive movements, deviation of the eyes, and disturbance of the pupils were absent. The breathing was regular and of normal character. Notwithstanding the absence of other untoward symptoms, complete consciousness did not return for a number of days or even of weeks. In such a case, after a number of days the question naturally presents itself, Have we not to do with a hemorrhage, and should not trephining be considered? The absence of all symptoms excepting the unconsciousness should lead to the suspicion that we have to do with a mental state rather than with a gross lesion. Hysteroid semi-consciousness (Walton) supervening upon a blow is not to be

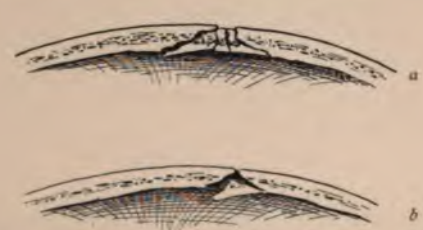

Fig. 5.—Splintering of inner table; cross-sections; diagrammatic: *a*, Usual form of punctate fracture; *b*, shows that a linear fracture may be much more extensive internally than externally.

mistaken for the deepening unconsciousness which indicates hemorrhage.

Subarachnoid Serous Exudation (Cerebral Edema).—A severe blow upon the head, with or without fracture of the skull, may result in a local bruising and in congestion and swelling of the brain-tissue, with serous exudation into the subarachnoid space, either with or without edema of the brain-substance. If this accumulation of fluid occurs over the motor area, localized symptoms, as if of hemorrhage, may appear. The lesion is usually self-limited, the resulting paralysis disappearing in the course of a few days. The careful observation of the onset and sequence of the signs of compression is of the very greatest importance, for it is by a proper interpretation of these localizing symptoms that the surgeon is led to operate, and then is enabled to remove the compressing blood-clot or the depressed fragment of bone.

Fig. 6.—Case of compound depressed fracture of the frontal bone. Note extent of depression. Recovery (Harrington).

Fig. 7.—Normal skull. Note relations of facial bones in connection with figs. 16 and 18.

THE FRACTURE OF THE SKULL

Whether the wound of the bone is compound or simple, open or closed, is of comparatively little importance, because of the very general recognition and employment of aseptic and antiseptic methods. A knowledge of the nature of the fracture will help

Fig. 8.—Depressed fracture of frontal bone from front, showing depression of fragments (Warren Museum, specimen 7951).

Fig. 9.—Same as figure 8; inner surface from below; shows excess of bone-formation.

Fig. 10.—Depressed fracture of right frontal bone: *a*, Point toward vertex; *b*, anterior corner; *c*, lower outer end (Warren Museum, 4721).

Fig. 11.—Same from within; letters as in figure 10. Fracture shows depression without much new bone-formation (Warren Museum, 4721).

in determining the injury to the brain. If there is a perforating fracture, or if the fragments are comminuted or depressed, then it is highly probable that a tremendous or sharply localized force has been exerted upon the bone, and that, in consequence, the injury to the underlying brain is serious. It is a generally accepted fact that the skull may be simply contused and the great

lateral sinus ruptured, with resulting fatal hemorrhage. It is likewise true that the bone may present but a fissure, but if that fissure crosses the middle meningeal artery, or any of its branches, they may be torn across, and the consequent hemorrhage and associated intracranial pressure will prove disastrous unless checked by surgical interference. On the other hand, the bone in the frontal region may be greatly damaged, literally crushed, and yet no grave symptoms arise (see Fig. 6). The extent of the bone-lesion is, however, of the greatest importance.

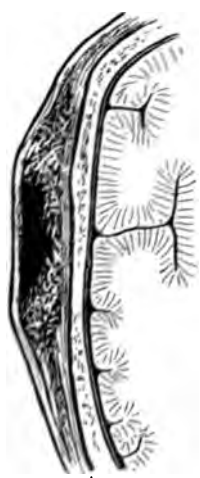

Fig. 12.—No fracture of skull. Hematoma of scalp, the depressed center and firm edge of which often simulate fracture.

Fractures of the Vault of the Skull (see Fig. 8).—Fractures of the vault of the skull without involvement of the base are much more unusual than is generally supposed. More than two-thirds of all fractures of the vault are associated with fracture of the base of the skull (see Figs. 8, 9, 10, 11). Evidences of fracture of the vault are determined by sight and touch. A wound in the scalp may disclose the fractured bone. Whether this is a mere fissure or a single or a comminuted fracture, whether depressed or not below the general surface of the normal skull, can be determined only by careful inspection. A fissure of the bone may be difficult of recognition. It must be remembered in this connection that blood can not be wiped from a fissure, whereas from the normal suture lines it can readily be wiped away. Blood may be seen escaping through a fissure. Torn periosteum must not be confused with a fissure of the bone.

A hematoma of the scalp may suggest a depressed fracture of the skull (see Fig. 12). The center of the blood-tumor is soft; the edges are edematous and hard. If the finger be pressed firmly into the soft center, an intact skull generally will be felt. The uniform edge of a hematoma is unlike the irregular jagged edge of a fracture. It is sometimes impossible to distinguish between a hematoma and a fracture of the skull. The symptoms of general disturbance are of course more marked and prolonged

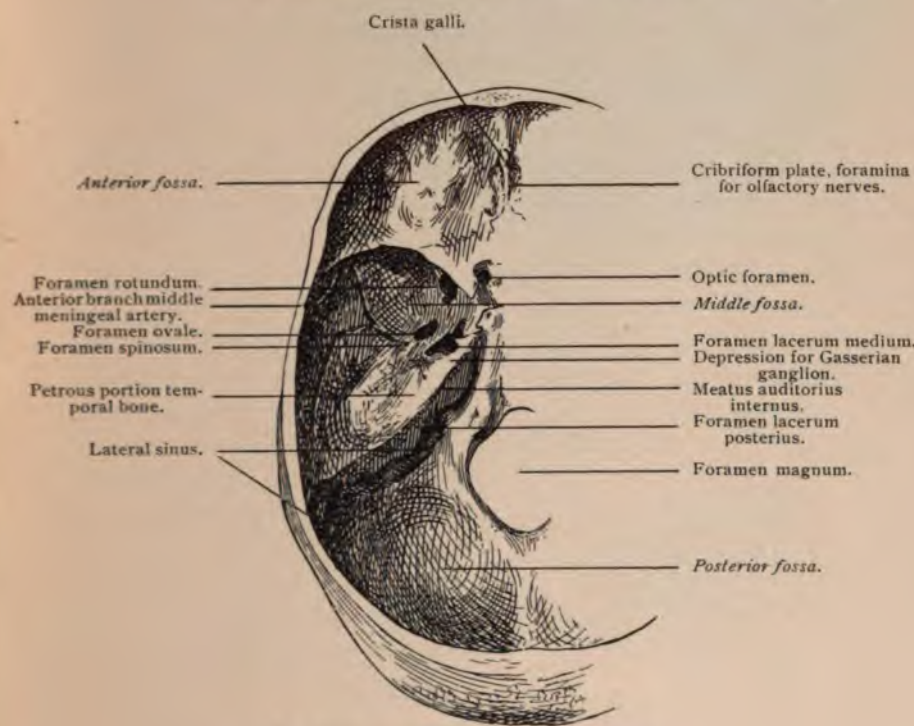

Fig. 13.—Base of skull, from inside and above.

Fig. 14.—Punctate fracture entering posterior fossa. From the punctate depression a line of fracture extends downward and backward (Warren Museum, specimen 965).

Fig. 15.—Inner view of figure 14, showing comminution of inner table of skull.

in the case of a fracture of the skull than when only a hematoma is present.

Fracture of the Base of the Skull (see Figs. 13, 14, 15).—It is not uncommon to discover that what in the vault appears to be a simple fissure continues down to and involves the base of the skull. Fractures of the base of the skull are usually regarded, and rightly so, as more serious than fractures of the vault. A greater trauma being necessary to cause the fracture, the cerebral disturbance is more pronounced and vital parts are endangered. These fractures of the base often open into cavities which it is impossible to keep surgically clean—namely, the cavities of the nasopharynx and the ear. The danger of septic infection, therefore, in such fractures is very great. About eighty-five per cent. of basic fractures originate in the vault—*i. e.*, are caused by an extension of a linear fracture of the vault to the base. A few basic fractures are due to forces acting from below and thus causing a penetration of the base of the skull by other bones. The facial bones may be forced up into the anterior fossa (see Fig. 16). The articular process of the inferior maxillary bone may be pushed up through the glenoid fossa of the temporal bone (see Fig. 17) into the middle fossa by a blow upon the chin, particularly if the jaw is relaxed. The vertebral column may be forced up into the posterior fossa through a fracture of the occiput.

Fig. 10.—Fracture of base of skull; impaction of nasal and part of ethmoid bones, which project into the interior of the cranium. Male, aged twenty-eight; diagnosis, fracture of nose. Died of meningitis (after Helferich).

Symptoms of Fracture of the Base.—Hemorrhage may take place from the ear, from the nose, from the mouth or be noticed under the conjunctivæ. Occasionally blood is seen in all four situations. Hemorrhage may occur beneath the pharyngeal mucous membrane. Escape of cerebrospinal fluid from the ear and nose may be noticed. Brain-tissue sometimes escapes from the skull and is seen lying in the external auditory meatus or near a wound which communicates with the fracture of the skull. Injuries may occur to the third, fifth, seventh and eighth nerves.

Associated with these local signs may be the general signs of concussion or laceration of the brain.

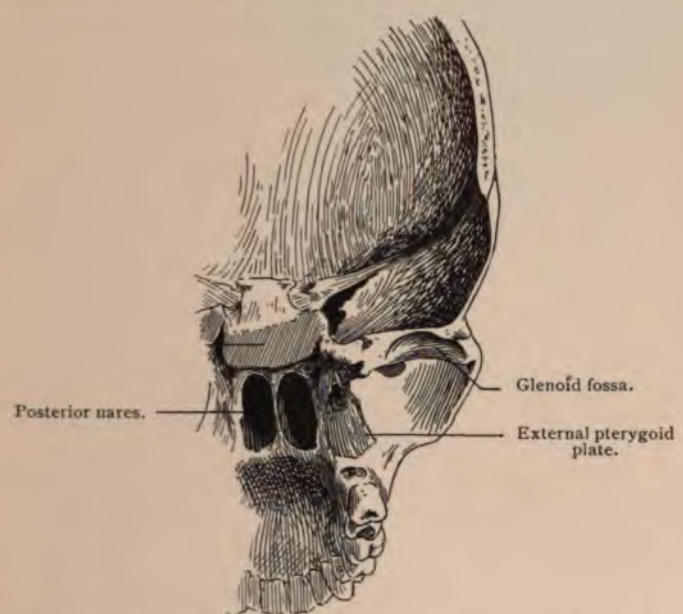

Fig. 17.—Showing thinness of the roof of the glenoid fossa, which is occasionally broken by the condylar process of the inferior maxilla when a blow is received on the jaw.

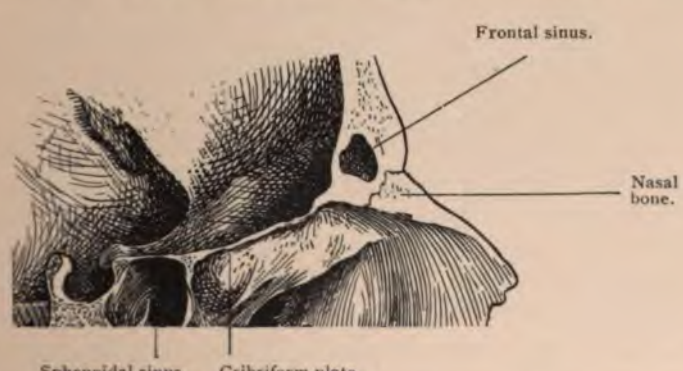

Fig. 18.—Median section. Anterior portion of skull, showing thinness of the ethmoid plate, which alone separates the cavities of nose and skull.

If the orbital plate of the frontal bone is broken, blood will gravitate into the orbit; ecchymosis of the lids and subconjunc-

tival hemorrhage will appear. There may be greater tension of the eyeball upon the affected side, detected by palpating the globe through the closed lid. Subconjunctival hemorrhage may appear from a fracture of the malar or superior maxillary bones.

If the cribriform plate of the ethmoid is fractured, hemorrhage from the nose will occur (see Fig. 18). Impairment of the sense of smell may exist if the olfactory nerves become involved in the fracture. Blood may trickle from a fracture of the base into the pharynx, be swallowed, and later vomited. Epistaxis, of course, may be due to a blow upon the face without fracture of the base. If inspection discloses a broken nose or ecchymosis of the face or

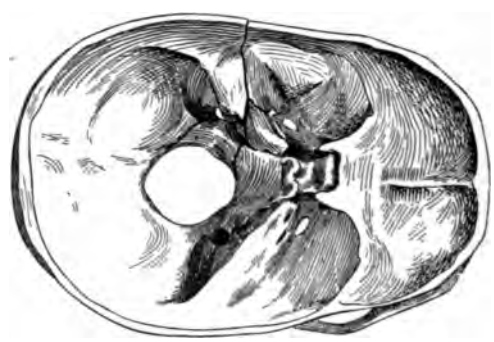

Fig. 19.—Fracture of the base of the skull, involving the middle and posterior fossæ on the left (Warren Museum, 5106).

the skin of the forehead, it is very probable that the minor accident has occurred.

Most fractures of the base involve the middle fossa. If the petrous portion of the temporal bone is fractured, several important signs appear (see Fig. 19). If the tympanum is torn, hemorrhage from the external auditory meatus is sure to follow. If this hemorrhage is continuous, it is significant; if it is trifling and temporary, it is probably unimportant and may be local. Cerebral tissue may escape from the nose, thus establishing the seat of the lesion. Cerebrospinal fluid may likewise escape from the ear. Cerebral tissue may also appear at the external auditory meatus. Any of these signs is conclusive evidence that the base of the skull is fractured and that there is a lesion of the brain. Lesions of the facial (seventh) and auditory (eighth) nerves lying

within the bones occur. Lesions are likewise reported of the fifth nerve, because of its lying upon the fractured petrous portion of the temporal bone. Subconjunctival hemorrhage may appear, owing to the blood working its way forward through the sphenoidal fissure and the optic foramen. A primary profuse watery discharge from the nose or the ear is probably cerebrospinal fluid.

Fig. 20.—The three fossæ of the base of the skull.

A watery discharge appearing late after such an injury is likely to be serum from a blood-clot. The optic nerve may be involved in the injury with resulting blindness.

If the posterior fossa (see Fig. 20) is involved in the fracture, there may be hemorrhage into the pharynx. Ecchymosis under the pharyngeal mucous membrane may be present without actual rupture of the mucous membrane. A fullness may be detected

by palpation in the posterior wall of the pharynx, if the hemorrhage there is considerable. Ecchymosis just in front of the mastoid process, or a hematoma and puffy swelling over the seat of the fracture, may determine its location.

Unconsciousness Resulting from Other than Surgical Causes.—There are certain conditions associated with loss of consciousness and delirium which must be differentiated from traumatic intracranial lesions. These conditions are (*a*) the coma from opium-poisoning; (*b*) the unconsciousness in uremia; (*c*) the loss of consciousness from apoplexy; (*d*) alcoholic coma; and (*e*) hemorrhagic internal pachymeningitis.

Coma from Opium-poisoning: The patient can be aroused unless the poisoning is extremely profound, and can be made to understand, and will even reply to an inquiry. The face at first is pale, later it is flushed and swollen. The skin is warm and moist. The respiration is slow. The temperature is subnormal. The pulse is slow and full. The pupils are strongly, immovably, and symmetrically contracted. The reflexes may be absent.

The Unconsciousness in Uremia: The patient can not be aroused. The face is white, edematous, and puffy. The breath has a sweetish odor. The respiration is frequent and irregular. The temperature is normal. The pulse is rapid. The pupils are dilated and sluggish. The urine usually contains albumin.

The Unconsciousness from Apoplexy: The patient can not be aroused. The respiration is slow, irregular, and stertorous. The temperature is subnormal at first; if a fatal termination is probable, the temperature is high. The pupils are dilated. Unilateral paralysis of the face and the extremities usually is present. The affected extremities are warmer than those of the other side. The limbs may be relaxed, but in watching the patient carefully evidences of hemiplegia will appear. The history of previous hemorrhages may be discovered pointing to hemorrhagic internal pachymeningitis.

Alcoholic Coma: The patient can be aroused by pressure upon the supra-orbital nerves—sometimes, however, with great difficulty. The breath may be alcoholic. The face is flushed. The respiration is regular. The pulse is rapid. The temperature is normal or low. The pupils are normal. There is an absence of

the positive signs of a cerebral lesion. The temperature in cerebral laceration is elevated. Alcoholic delirium will present an elevated temperature, but along with the elevated temperature of a lacerated brain there will be symptoms characteristic of a damaged brain.

Hemorrhagic Internal Pachymeningitis: The occurrence of apoplectic seizures during the course of this disease makes it important that it be recognized in connection with the distinctly traumatic hemorrhages under consideration. The characteristic course shows an acute diffused affection of the brain, usually in an elderly man and with severe symptoms. An acute attack is followed by a fair recovery and by intervals of comparative health. During these intervals of comparative health the patient has some headache, slight diminution of intelligence, impairment of memory, drowsiness, partial paralysis of the limbs (usually unilateral), disturbances of speech, and sudden mental excitement without cause mixed with symptoms of paralytic dementia. Evidences of a sudden and increasing compression are headache, drowsiness, loss of consciousness, some fever, a pulse of compression, and sometimes initial symptoms of irritation. The diagnosis is assisted by the etiology and history of the case. In middle meningeal hemorrhage a blow is necessary to cause alarming symptoms, whereas in hemorrhagic pachymeningitis a very trivial injury or none at all is common. The longer duration of the symptoms would help to decide against middle meningeal hemorrhage. There is often a rigidity of the limbs in hemorrhagic pachymeningitis which is absent in middle meningeal hemorrhage cases.

When called upon to see a case of head-injury, it must be remembered that the lesion can not always be determined by the first observation of the patient. It is absolutely necessary that there be, upon the part of the physician, a clear understanding of the method of onset and the sequence of symptoms from the receipt of the injury. Isolated signs are of less importance than relative symptoms.

Examination of the Patient.—The following comprehensive method of examining an individual who has received a severe injury to the head should be carefully followed, bearing in mind always the possible cranial and intracranial lesions, and remem-

bering that a fracture of the skull as such is of secondary importance, that an injury to the intracranial vessels is serious, and that a lesion of the brain itself is most important.

If with brain symptoms there is no visible injury to the skull, the head should be shaved to facilitate careful examination. Acute localized pain suggests the seat of fracture.

When was the accident? How much time has elapsed between the accident and the first accurate observation?

What was the accident? Was it a fall or a blow?

What is the age of the patient? Are the arteries atheromatous, and therefore easily ruptured by trivial injury? Is it the skull of a child—which is softer and less brittle than that of an adult?

What was the condition of health previous to the accident? Was it poor—suggestive of kidney-disease and uremia? Was the man alcoholic, or is the present condition masked by alcohol taken subsequent to the accident?

The General Condition of the Patient: If unconsciousness is present, was its onset immediate, or was there a lucid interval after the accident? Has the unconsciousness been continuous, and is it deepening or lessening?

What are the evidences of shock present? What is the condition of the pulse, of the respiration, of the skin? What is the temperature taken in the rectum? Has vomiting occurred? Have there been involuntary dejections? Has there been involuntary micturition?

The Local Condition: The wound of the scalp or skull or brain may be evident. If hemorrhage is present, what is its source? Is it from the nose, the mouth, the ear, or into the orbit? When did the hemorrhage occur? What was its amount? Was it continuous or not? Palpation should be made of the skull, the neck, the face, the spine, the jaw, and the temporo-maxillary joint.

Are any localizing signs present? What is the condition of the pupils, and of the muscles of the face, the arms, and the legs? What is the condition of the reflexes and of the respiration? Does hemiplegia, either partial or complete, exist?

Finally, the whole body should be examined systematically for any other injuries than those to the head and to the nervous

system. Associated injuries, if discovered, may assist in interpreting the nature of the cerebral injury.

A diagnosis must be based upon all available evidence. One will have to consider concussion and laceration of the brain and pressure upon the brain by serum, blood, and bone. The important signs to be studied in diagnosis are the different aspects of unconsciousness; the relative and actual conditions of the respiration, pulse, and temperature; the occurrence of hemorrhage; restlessness and muscular twitching; localizing signs of pressure. If the symptoms are not positive, if there is no history of trauma, if the history of a lucid interval preceding unconsciousness is doubtful, or if there is no history at all, then the diagnosis will be most difficult. It is when positive symptoms are absent that one must particularly consider those conditions already mentioned in which coma is a prominent sign—namely, opium-poisoning, uremia, apoplexy, alcoholism.

General Observations.—An unconscious man having a scalp wound and a breath smelling of liquor is not, necessarily, drunk. He may have an intracranial lesion. Multiple lesions may be present in any case. A diffuse lesion may obscure a localized lesion. Not only must the location of a lesion be determined, but also its character, if possible. The symptoms must be recorded in the order of their appearance. The manner in which various symptoms develop should be noted. The danger to the brain is greatest in perforating and sharply depressed fractures. Slight fissures may be associated with extensive hemorrhages. Great comminution of bone may be devoid of much danger. In cases of compound fracture fissures apparently closed afford the possibility of cerebral and meningeal infection through dirt having entered when the fissure was open.

Unconsciousness and a superficial head-lesion, with or without fracture of the skull, must make one suspicious of an intracranial lesion. An immediate loss of consciousness indicates a diffused contusion or concussion of the brain. If the primary unconsciousness is prolonged, probably hemorrhage has occurred, or possibly a serous exudation with its resulting pressure upon the brain. If there is a conscious interval preceding the unconsciousness, a hemorrhage is probable. Momentary unconsciousness

means concussion. Recurring unconscious periods indicate hemorrhage. Deepening unconsciousness indicates increasing intracranial pressure—probably hemorrhage. Immediate profound unconsciousness suggests hemorrhage from the rupture of an intracranial sinus.

The temperature in all intracranial lesions is usually slightly above normal. Intoxication and shock depress the temperature. In a small intracranial hemorrhage there will be a slight rise of temperature, perhaps to 99° F., following the initial drop a few hours after the injury. In cerebral laceration one finds a higher initial temperature than in hemorrhage, and in fatal cases the temperature remains elevated. If the temperature rises quickly and early, a considerable laceration is present; if after several hours of unconsciousness the temperature remains about 99° or 99.5° F., there is probably a hemorrhage rather than a severe direct lesion; if, on the other hand, the temperature rises higher, there is a cerebral lesion, alone or associated with a hemorrhage. If the temperature does not rise very high and advances rather slowly, there is a contusion or a concussion with slight laceration or a slight hemorrhage. A slow, full pulse with stertorous respiration suggests pressure; it may be from extradural hemorrhage. Early and very slow respiration is associated with pressure upon the medulla.

Paralysis of the limbs and the face is characteristic of serous exudation, hemorrhage, or bony pressure. Irregular muscular contractions suggest laceration of motor areas. Mental disturbance may be due to cerebral lesions. That brain-tissue escapes from the ear does not necessarily signify that the patient will not recover. Fractures of the base of the skull occur without marked symptoms and recover without the necessity of operation.

Treatment.—There are cases of injury to the skull so serious that it is evident that operation will be of no avail. There are cases of simple concussion in which only careful nursing is demanded. There is a large and increasing number of serious head-accidents in which operative interference will prove of great value. The collapse from shock may be well nigh complete, but restorative measures are not to be neglected upon this account. If hemorrhage is suspected, stimulation of the circulation must be

very guarded. The patient should be placed horizontally, with the head slightly raised, and kept quiet. The whole body should be wrapped in warm blankets. Warm water-bottles should be put on the outside of the bed about the patient not next the skin, one at each foot, three along each side of the body. The water in these bottles should be comfortably warmed—110° F. Hot water is never to be used. Patients under these circumstances are insensible to heat, and severe burning of the skin may occur if very hot water is used in the bottles.

If there are no indications for immediate operation, and localizing symptoms are absent, the patient is to be treated symptomatically. The pulse is to be carefully watched to detect variations in strength, rate, and rhythm. The character and frequency of the breathing are to be likewise noted. Gentle stimulation subcutaneously by sulphate of strychnin ($\frac{1}{60}$ of a grain), administered as needed, will often steady a pulse remarkably. A special nurse or an intelligent watcher should be with the patient constantly, to note any localizing signs of pressure, such as twitching of the muscles of the face or limbs and variations in the pupil, to record movements of the limbs, and to make hourly observations of the pulse, temperature, and respiration, and any variation in consciousness. These observations will be of inestimable value in determining diagnosis, prognosis, and treatment.

The various cavities exposing the brain to infection should be cleansed.

The Nose.—The nose should be douched with boric acid solution (1 : 30), and plugs of sterilized absorbent cotton should be placed in each nostril.

The Ear.—The ear should be douched with boric acid solution (1 : 30), and dried carefully with small wisps of cotton. Boric acid powder should then be blown gently into the external auditory meatus. A bit of sterilized gauze or absorbent cotton may be left in the meatus.

The Scalp.—The directions for cleansing the scalp pertain to cases with or without scalp wounds associated with important cerebral symptoms. The whole scalp should be shaved, scrubbed with hot water and soap, with chlorinated soda solution (1 : 20), with boiled water, and then with corrosive sublimate solution

(1 : 1000), and covered with a dressing of sterilized gauze that has been moistened in a solution of corrosive sublimate (1 : 5000). The wound of the soft parts should be carefully irrigated with sterilized salt solution, and sponged and swabbed with great care with corrosive sublimate solution (1 : 5000). The swabs used should be tiny ones, so as to reach to the smallest recesses of the wound. Corrosive sublimate solution should not be allowed to touch the brain-tissue.

The Mouth.—Thorough cleansing, with corrosive sublimate solution (1 : 3000), of the teeth and tongue and all the folds of the mucous membrane about the lower and upper jaws is important. The swabbing of the tonsils and the posterior pharyngeal wall, the care of the nose and the ear,—these procedures will reduce to a minimum the chances of infection. The nose and mouth will require constant attention. The ear will require at least daily cleansing. The frequency of the cleansing required will depend very largely upon the amount of moisture and discharge from the part involved. If the packing of cotton soon becomes moistened, the douching should be repeated, and fresh, dry packing should replace the old.

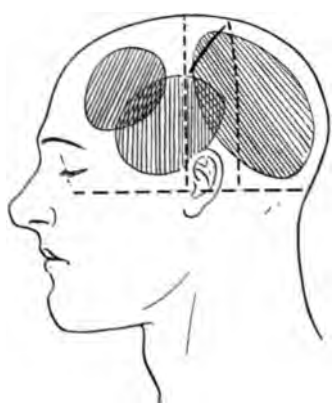

Fig. 21.—Sites where extradural hemorrhage is usually found.

If there is great restlessness, it may be necessary to restrain the patient, that he may not harm himself. This is done by means of a sheet folded and passed about the bed and body of the patient.

Operative interference is demanded in penetrating or sharply depressed fractures, in all compound fractures, and in all simple fractures with symptoms of intracranial hemorrhage increasing in severity or distinctly localized (see Figs. 21, 22, 23). Operation should be undertaken in these cases for three distinct reasons: to insure cleanliness, to elevate and, if necessary, remove bony fragments, and to check hemorrhage. The details of operative treatment must necessarily be omitted.

All cases of injury to the head, even cases of simple nondepressed fracture of the skull without symptoms, are to be watched with great care by trained observers for at least one month following

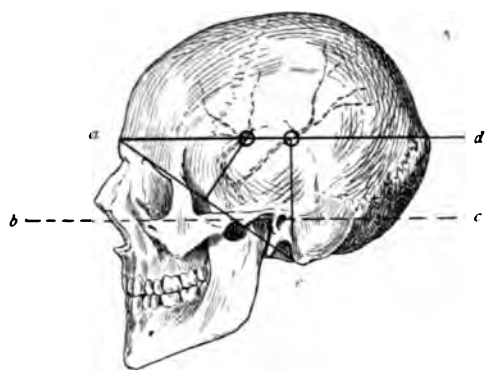

Fig. 22.—Location of *anterior* branch of middle meningeal artery. Draw a line from the glabella backward (*a d*), parallel to the line *b c*, from the lower edge of the orbit through the external meatus. Line from glabella to mastoid, *a e*. From the middle of this last line, a line drawn perpendicular to it will intersect the line *a d* at about the site of the artery. A line running from the front of the mastoid perpendicular to the line *b c* intersects *a d* at about the site of the posterior branch.

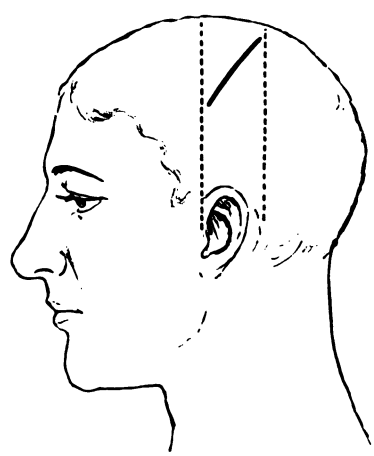

Fig. 23.—Perpendicular lines from the mastoid and from just in front of the ear include the motor area of the central convolutions. The fissure of Rolando is shown.

the accident, and then are to be seen at intervals for many months afterward. The reason for this prolonged observation is that meningeal hemorrhage may develop in the immediate future, and

that after an interval of months a brain-abscess may manifest its presence.

In fracture of the base with pronounced symptoms, drainage of the fossa involved, whether anterior, middle, or posterior, should be considered. It has occasionally been of service.

Prognosis.—The prognosis of head-injuries is the prognosis of their complications and sequelæ. Prolonged unconsciousness is not usually dangerous in itself. Late unconsciousness is dangerous. The severity rather than the form of the lesion is to be made the basis of prognosis. The temperature is of great value in prognosis. By its persistent depression the danger from primary shock is gauged; a little later in the course of the case the amount of hemorrhage is judged by it; later still, its rapid and progressive rise will denote the magnitude or severity of a meningeal or cerebral lesion. A temperature as high as 105° F. is of grave prognosis. A sudden rise of temperature late in the progress of a case, probably due to a meningitis, or a continued subnormal temperature at any time after the reaction from the primary shock, is always an unfavorable sign. Symptoms often change suddenly in cases apparently doing well. One's prognosis must, therefore, always be guarded.

LATER RESULTS OF FRACTURE OF THE SKULL

Very little is known of these cases in this country. Dr. Bullard, of the Boston City Hospital, has contributed so valuable a paper upon this subject that the results are here stated: Seventy patients were examined after having had fracture of the skull: 37 presented no symptoms when examined some time later. The most frequent consequences were headache, deafness, dizziness, and inability to resist the action of alcohol on the brain. Out of 15 cases in which operation (trephining) was performed, 12 had no resulting symptoms; in one case it was doubtful whether the symptoms present were due to injury; in one case the symptoms were slight (headache rare, tension over the wound while lying in bed). The other case was deaf, but had no other trouble.

Dr. Bullard concludes, so far as these statistics lead, that those cases in which trephining was performed have shown much better

results, so far as the symptoms previously mentioned are concerned, than those in which no operation was performed.

CASES OF HEAD INJURY

The following cases, related in some detail, illustrate a few of the varieties of injuries to the head from a clinical standpoint:

CASE I.—*A fall upon the head.—No visible evidences of injury.—An interval of consciousness followed by unconsciousness.—Localizing signs of pressure.—Diagnosis, middle meningeal hemorrhage with fracture of skull.—Operation.—Fracture and hemorrhage found.—Recovery.*

M. A. B——, sixty-nine years old, a spinster, fell, upon being struck by a coasting-sled, one and one-half hours previous to the examination.

Examination.—She does not know of the accident which has befallen her. She talks coherently. She recognizes her sister. There is slight shock. The pulse is 64 and of fair strength; the respiration is 16; the temperature is 97.5° F. There is bleeding from the right ear. There is some dry blood about the nostrils. There is no visible external injury. There is no paralysis. All the superficial reflexes are present. The pupils are contracted equally and react to light. The patient is not very restless, although she talks considerably and affirms again and again that she is not hurt.

The ears were washed out carefully and treated antiseptically.

She vomited two or three times during the night. She was quite restless, moving and turning in bed. She slept two or three hours altogether. There were no evidences of intracranial pressure in the morning. At about noon of the second day she talked a little incoherently. She did not answer questions as readily as in the morning.

At 3 o'clock in the afternoon of the second day examination finds the pupils equal and reacting to light. She understands what is said to her, but does not talk coherently or distinctly. There is almost complete paralysis of the right arm. There is paresis of the right leg. The face is not paralyzed. The pulse has increased in rate to 85 and is particularly full and bounding. The knee-jerk is much less active upon the right than upon the left side.

At 4.30 P.M., one and one-half hours after the previous observation, all the symptoms were considerably intensified. The face was uneven, the wrinkles being most marked on the left. The breathing was becoming labored and almost stertorous. It was hard to arouse the woman. She moved the left arm freely. The right arm she moved slightly or not at all. There were no abdominal reflexes active. Bleeding from the right ear continued to a slight extent all day.

A diagnosis of middle meningeal hemorrhage on the left side was made. Immediate operation was decided upon.

Under ether anesthesia an elliptic incision was made upon the left side of the head, beginning just in front of the ear, and was carried

up across the temporal muscle and down to the zygoma of the same side. A quarter-inch trephine was used. The hemorrhage was found to be from a branch of the middle meningeal artery, and from within the dura, which was lacerated. A large clot and much fresh blood were lying over the temporal and parietal regions. This blood was carefully sponged away. The middle meningeal branch was tied with a silk ligature. Gauze wicks were placed well down deep toward the base of the skull. The dura was not sutured. The bleeding vessels of the diploe were stopped with wax. The skin flap was replaced and sutured, leaving a small gauze drain down to the dura.

The pulse was poor, and there was evidence of considerable shock at the conclusion of the operation. Proper stimulation with strychnin and enemata of salt solution and brandy had a good effect. The temperature rose to 110° F. during the night, but dropped immediately and gradually came to normal.

Fig. 24.—Case I. Line of incision shown.

The following day unconsciousness was present, the paralysis was unrelieved, the breathing was stertorous and puffing.

The second day after the operation the gauze drain was removed and two smaller gauze drains were inserted. Some signs of consciousness appear. She takes notice of people coming into the room.

The fifth day following the operation she notices friends. The paralysis is still present.

The sixth day after the operation she moves the right leg a little. No articulate speech is present. Understands questions and grunts in answer to all questions. She can express no idea in words.

The tenth day after the operation she moves the right arm. The mental condition is clearer.

On the eighteenth day she moves the right leg, and the arm has more power.

The thirtieth day was an important one for the patient. She walked alone for the first time since the accident.

One year after the accident the patient is found to be having occasional attacks of dizziness, accompanied by "falling-fits." She is perfectly sane, and talks, often very well; then there come times of difficulty in talking, when she can not find the right word to express herself. Just after one of these attacks of fainting, etc., talking is less easy.

Three years after the operation the following examination was made: The speech is thick, slow, and with effort. The facial muscles of the left side are stiff and slightly drawn; they do not move so well as on the right side. The left nasolabial fold is more accentuated than the right. The left eyebrow is lower than the right. The patient thinks that she can hear better with the right ear than with the left. The right hand gets cold "and does not look natural." The right forefinger is often whiter than the other fingers of the right hand. It is difficult to pick up needles or pins with the fingers of the right hand. There is no increase in the wrist-jerks. The knee-jerk is slightly greater on the right side than on the left.

The patient says she is enjoying excellent health, eats and sleeps well, and is out of doors much of the time. She is taking bromid of potassium regularly once a day in small doses. About once a month she has a fainting or "weak spell." These attacks are growing less pronounced and less frequent.

Fig. 25.—Case II. Open depressed fracture of the skull: *X*, the mid-point between glabella and inion; *A*, middle of depressed bone.

This case illustrates the important fact that after a severe head injury with almost no external visible sign, the patient should be kept under very careful observation through the hours immediately succeeding the accident. Relative symptoms are of far greater importance in head injuries than isolated observations. Bleeding from the ear as a symptom in head injuries does not necessarily imply fracture of the petrous portion of the temporal bone. Rupture of the tympanum may cause bleeding from the ear. There was no fracture of the skull detected after careful examination in this case.

The interval of consciousness in this case was a somewhat short and hazy one. Immediately after the accident the woman was dazed, and at no time was she herself mentally. It is to be remembered in this connection that the interval of clear consciousness may be so masked by the symptoms of concussion as to be completely overlooked.

CASE II.—*An open depressed fracture of the skull.—Absence of unconsciousness.—Paralysis of one-half of the body.—Operation.—Recovery.*

This case illustrates that consciousness may be unimpaired following an injury to the head severe enough to cause paralysis.

A boy, nine years old, was struck on the head by a brick falling from a height. He was seen immediately after the injury and found to be conscious. He answered questions naturally. There was a large

scalp-wound over the parietal bone and a little anterior to the parietal eminence to the right of the median line. The bone beneath the scalp-wound was fractured and depressed into the brain-substance. The left arm and the left leg were completely paralyzed to motion. The right pupil was dilated; sensation was present. The right upper eyelid drooped. There was a scar in the right cornea. Immediately after the injury the temperature was 96° F., the pulse was 74, the respiration was 26. When examined one hour after the accident the pulse had fallen to 68, he had vomited once, and had been somewhat nauseated.

The operation of elevation of the depressed fragments of bone was done under ether. The fragments of bone removed were about the size of a silver half-dollar. There was no fissure in the skull. The

Fig. 26.—Case III.

dura mater was torn and the brain slightly lacerated. Upon elevating and removing the depressed bone hemorrhage occurred from the vessels of the dura mater. The depressed bone was not replaced. The dura was left open and the cavity was drained by a wick of gauze, which was removed upon the third day.

A few hours after the operation the boy was perfectly conscious as before the etherization, the pupils were normal, and motion had returned in the paralyzed limbs.

Three weeks after the operation a small, granulating wound remained and there was a slight tendency to hernia cerebri.

Four months following the accident the boy's condition is as follows: The wound is nearly healed and continues to discharge at times. He walks naturally. There is no paralysis of arm or leg. No mental symptom is present.

The interesting and unusual fact in this case is that after a blow sufficiently severe to cause a depressed fracture of the skull and paralysis of one-half of the body the patient remained conscious.

The exact location of the injury to the head and brain is shown in figure 25.

CASE III.—*A blow upon the head.—Unconsciousness immediate.—Slight bulging of right eye.—Middle meningeal hemorrhage.—Fracture of skull.—Operation.—Recovery.*

Examination found edema of the right temporal region. Unconsciousness present. An interval of consciousness was absent. Slight bulging of the right eye.

Operation in the right temporal region. A skin-flap was made over the fracture and edematous area. A fracture was detected running from about the middle of the temporal ridge an inch back of the coronal suture outward and forward across the squamous part of the temporal bone to a half-inch behind the pterion.

The bone anteriorly to the fracture was depressed. The trephine was applied over the depressed portion behind the coronal suture. Upon exposing the dura no pulsation was seen. The dura was dark in color. A slight amount of extradural blood escaped. On following the fracture down to the base of the skull the dura was found lacerated, the anterior branch of the middle meningeal artery was torn, and blood-clot and lacerated brain-tissue were present. The anterior branch of the middle meningeal artery was tied and the hemorrhage ceased. The blood-clots were removed, the exposed area was cleansed with boiled water, and gauze drainage introduced. All the gauze was removed in four days. No unusual symptoms attended convalescence. Recovery was complete in three months (see Fig. 26).

This case is of interest because no fracture was detected before the operation, and it was supposed that the bulging of the eye indicated an increase of intracranial pressure, which proved to be true.

The method of operating was comparatively simple, in that the fracture was followed down until the bleeding vessel was found. This necessitated the free removal of bone below the trephine opening.

There was no interval of consciousness in this case, and the conditions found easily explained its absence. The man was suffering from concussion and laceration of the brain as well as from intracranial pressure, and the interval of consciousness was obscured by the presence of the concussion. The recognition of an interval of consciousness is of very great importance. If, however, the interval of consciousness is not present, as in the case reported, intracranial pressure from hemorrhage can not be said to be absent, for concussion attendant upon the injury may mask the interval of consciousness which might have been present had the injury been less severe.

CHAPTER II

FRACTURES OF THE BONES OF THE FACE

FRACTURES OF THE NASAL BONES

Anatomy.—The anatomical relations of the nasal bones (to the perpendicular plate of the ethmoid, the vomer, the cartilaginous septum, the superior maxillary bone, and the frontal bone) make their fracture of far greater importance than a mere superficial disfigurement of the face would indicate (see Fig. 27). The

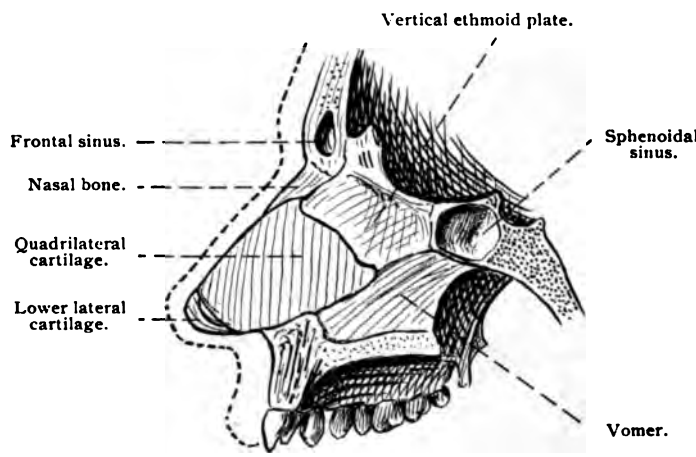

Fig. 27.—Median section of nose.

site of the fracture is usually near the lower edge of the bone. Most fractures of the nasal bone are open through either the skin or the mucous membrane. In nearly all nasal fractures the cartilage of the septum is more or less injured. The upper lateral cartilages may be torn from their attachments to the nasal bones, simulating fracture of these bones. The resulting deformity of this accident is well illustrated in figure 28. A high fracture of the nasal bones with lateral deformity is shown in figure 30: the nasal bone of one side has been impacted with the frontal bone,

Fig. 28.—Separation of cartilage from nasal bones (Harrington).

Fig. 29.—Fracture and lateral displacement of each nasal bone.

Fig. 30.—Case of fracture of nasal bones. Lateral displacement (Harrington).

Fig. 31.—Fracture and lateral displacement of each nasal bone. Side view of figure 29.

and the nasofrontal articulation upon the opposite side has been separated. Figures 29 and 31 show a case in which, by a direct blow squarely upon the nasal bones, the bones were separated and one was laid on one nasal process of the superior maxillary bone and the other was laid upon the corresponding bone. The septum was intact, as is shown by the persistence of the natural position of the tip of the nose. Figures 32 and 33 show a syphilitic nose, the septum gone, and the nose fallen in. The contrast in these two cases is instructive.

Fig. 32.—Syphilitic deformity (Harrington).

Fig. 33.—Syphilitic deformity (same case as Fig. 32).

Symptoms.—Pain, swelling, crepitus, and deformity are usually present. The subcutaneous swelling is often so considerable as to obscure deformity. Gentle pressure is often sufficient to detect crepitus in this fracture, when a firm grasp determines little or nothing.

Complications.—Through infection of the internal or the external wounds suppuration begins, abscesses form, and necrosis of bone and liquefaction of cartilage may occur. Emphysema may be noticed if the fracture is open into the nasal cavity (see

Fig. 34). It will disappear after a few days untreated. The lachrymal duct may be obstructed if the nasal process of the superior maxillary bone is involved. The nasal bone may be forced up into the floor of the anterior fossa of the skull, and cerebral complications arise (see Fig. 16). If the deformity following fracture of the nasal bones is not corrected, there is great likeli-

Fig. 34.—Case of open fracture of the nasal bones. Emphysema over the forehead and the upper part of the face.

hood of trouble, either immediately or in after years, because of damage to the nasal septum.

The Nasal Septum in Fracture of the Nose (see Figs. 35, 36, 37, 38, 39).—The starting of the quadrilateral cartilage of the septum at some of its bony attachments may be evident at once after the fracture of the nose as a marked dislocation, or no change may be seen until long afterward, when a ridge due to inflammatory thickening is found along the previously loosened border. The

septum may be dislocated from its attachment to the superior maxilla, and deviate into one nostril or the other like a curtain. The commonest dislocation occurs at the junction of the cartilage of the septum with the vomer and the ethmoid.

Lesions of the septum due to fracture occur usually in the posterior two-thirds of the cartilaginous and in the anterior half of the bony septum. Fractures rarely extend through the septum to the posterior nares. In fractures of the nasal bones with little displacement the septum may show no changes. Even with considerable depression and comminution of the nasal bones, the septum as a whole may appear unchanged, the lesions of the septum being confined to bowing or tearing at the seat of fracture. When the nasal bones are much deviated, the free edge of the septum deviates with them. Fractures of the nasal bones may

Fig. 35. Fig. 36. Fig. 37. Fig. 38. Fig. 39.

Figs. 35-39.—The septum in fractures of the nose (Mosher).

occur alone or in combination with fractures of the septum. Severe cases of broken nose usually combine the two conditions. Fractures of the septum which admit of classification follow one of two types—horizontal fractures or vertical fractures. The vertical fracture is much the rarer. It may occur anywhere in the course of the cartilaginous septum, but when situated well back, is to be distinguished from dislocation of the cartilage. The horizontal fracture produces a gutter-like deformity roughly parallel with the floor of the nose. The convexity appears in one naris, the concavity in the other. Closely allied to these last two fractures are the sigmoid deviations, in which the relation to fracture is unsettled. They are so common that they are mentioned for the sake of completeness. The name describes them. They occur in the same two types as the angular variety.

Treatment.—The nasal cavity should be inspected by mirror and light to determine any lesion of the septum. Cocain anesthesia is necessary for this examination. If a deviation is found, it should be corrected along with the correction of the external nasal deformity. For this, primary anesthesia will be needed, as the manipulation is extremely painful. By external manipulation combined with elevation of the fragments and internal pressure with *Roe's elevator* (see Fig. 40) the deformity usually can be overcome. Any strong, narrow, and thin instrument will be of service as an elevator. For fractures high up with displacement, gauze

Fig. 40.—Fracture of nasal bones. Elevation of depressed bone by instrument introduced into the nostril.

packing carried well up will be required to retain the elevated bones. For lower deviations the *Asch tube* will be needed. If the nose is crushed, it will be necessary to model the nose over the Asch tube, one being placed in each nostril to preserve the contour and lumen of the nose. If there is no tendency for the deformity to recur, the use of splints is not indicated. Care must be exercised to avoid sudden pressure on the nose from the rough use of the pocket handkerchief. In the treatment of these cases special cleanliness, perfect drainage, and frequent dressings are important. If there is a recurrence of the external deformity,

LANE LIBRARY

localized pressure may be exerted in various ways, all of which are more or less unsatisfactory.

The tin splint fixed to the forehead by a circular plaster band is of service. This tin splint (see Fig. 41), made from ordinary sheet tin, consists of a forehead and a nasal portion. The nasal portion may be twisted or bent laterally to secure the desired pressure upon the nose, the counterpressure being obtained through the fixation secured by the adhesive plaster band. Repeated adjustments of this splint are needed to make the splint of continued efficiency; with all care, however, the tin splint is not generally effective.

Fig. 41.—Fracture of nasal bones. Tin nose-splint applied.

The use of adhesive plaster strips (after Davis) from cheek or malar bone to nose with small compresses is of limited value.

Cobb's nasal splint, shown in figure 42, is expensive, but is very satisfactory for making direct pressure upon the nasal bones. The splint is made of a band of steel, fitted to the head like the hat-band of a hat. To this band are attached an arm and a pad with screw adjustment. A strap over the head and one beneath the chin prevent downward and upward displacement.

Coolidge's Splint (see Fig. 43).—This consists of a tin pad for the forehead with strap encircling the forehead for the retention of the pad in position. To the lower border of the pad are soldered two wire arms upon which slide two small felt pads. The arms can be bent so that counterpressure may be obtained upon the firm parts of the face, while direct pressure with the other pad is brought to bear upon the nose. This splint is inexpensive and is efficient.

The nasal cavity should be cleansed at least twice daily with antiseptic douches. Seiler's tablets, one tablet dissolved in a quarter of a tumbler of warm water, used with the Birmingham glass douche, make a satisfactory wash. The external wounds should be dressed according to general surgical principles. It is well to remember in this connection that suppurating wounds do

YALE LIBRARY

far better if dressed frequently than if left to accumulate purulent discharges.

After a blow upon the nose, even if there is no immediate deformity, the nose should be examined to determine the presence of swelling upon the cartilaginous septum. Even a slight blow upon the nose may cause a hematoma of the cartilaginous septum (see Fig. 44). This hematoma is liable to become infected and to suppurate. Considerable destruction of cartilage may follow, resulting in marked disfigurement of the nose.

Fig. 42.—Cobb's splint applied to a case of fracture of the nose. The head-band is so adapted to the shape of the head that it remains fixed and offers a point of counterpressure.

The involvement of the base of the skull adds a serious element to an ordinary simple accident (see Figs. 16, 18).

The **prognosis** as regards the resulting deformity must always be guarded. Union usually takes place within two weeks of the accident and is firm in one month. In treating fracture of the nose it is important to be ever mindful of hematoma of the septum, and of abscess of the septum resulting from the hematoma. The external deformity that follows fracture does not tend to increase, but the internal deformity does. It is, therefore, of even more importance to correct the internal deformity than the external. Unless both are corrected, the nose may be straight but obstructed.

FRACTURES OF THE MALAR BONE

Examination.—Palpation of the malar bone is somewhat difficult. The best method of doing it is to stand behind the sitting patient (see Fig. 45), and to feel both malar bones at the

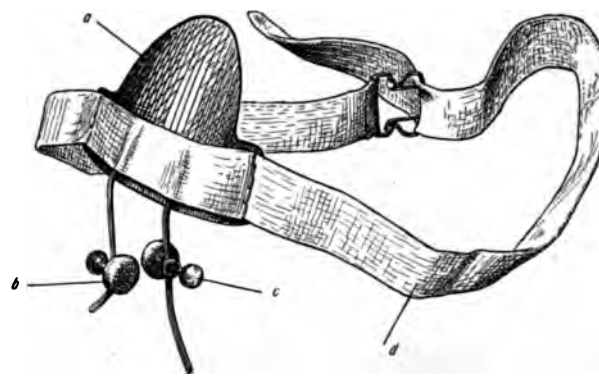

Fig. 43.—Coolidge's nasal splint: *a*, Forehead plate; *b*, pad; *c*, screw controlling position of pad; *d*, head-strap.

Fig. 44.—Hematoma of the nasal septum (after Roe).

same time—the left one with the left hand, the right one with the right hand. The malar process of the superior maxilla is felt inferiorly by pushing the skin of the cheek upward. The orbital part of this process is felt superiorly at the middle of the inferior border of the orbit. Following the orbital margin out-

ward and upward, the orbital border is palpated up to the frontal process. Following the malar process of the superior maxilla backward, the free inferior border of the malar is felt continuous backward with the zygomatic process. Starting on the frontal process, the posterior border of the malar may be palpated downward and backward to the upper border of the zygomatic process of the temporal bone. The inferior surface of the malar may be felt by placing the fingers, palm upward, in the superior sulcus of the cheek and following backward until the coronoid process of the lower jaw is felt. In the case of a fracture that is as often

Fig. 45.—Proper position from which to palpate the malar bones. The fingers touch the inferior borders, the thumbs the posterior borders, of the malar bones.

unrecognized as is this one it is important to be very familiar with the details of the outline of the bone.

Symptoms.—Fracture of the malar bone is caused by a severe blow upon the cheek. It is rather unusual to find a fracture of the body of the bone. More often there is a fracture of one of its processes, the line of fracture being continuous with a fracture of some adjoining bone. The malar is depressed as a whole, or tilted inward toward the zygomatic fossa because of a loosening of one or more of its articulations or because of a fracture or crushing of the superior maxilla. The deformity consists of a depression to the outer side of and below the eye. The line of fracture or separation can sometimes be palpated. Mobility and crepitus are rarely obtained. If the depression of the malar or of an asso-

Fig. 46.—Depressed fracture of the left malar bone. Note swelling of the left cheek and slight hollow outside left orbit (Warren).

Fig. 47.—Depressed left malar bone. Same case as figure 46. Note depression behind and below left orbit (Warren).

ciated fracture of the zygomatic arch impinges upon the space in which the coronoid process moves in the opening of the mouth, the motions of the lower jaw will be restricted (see Fig. 48). The limitation of motion of the lower jaw may be temporary or permanent, depending upon whether it is due to hemorrhage and swelling or bony pressure. The coronoid process of the lower jaw may be fractured by the same force which fractured the zygoma or malar. Localized subconjunctival hemorrhage may appear if the orbit is involved. If the floor of the orbit is frac-

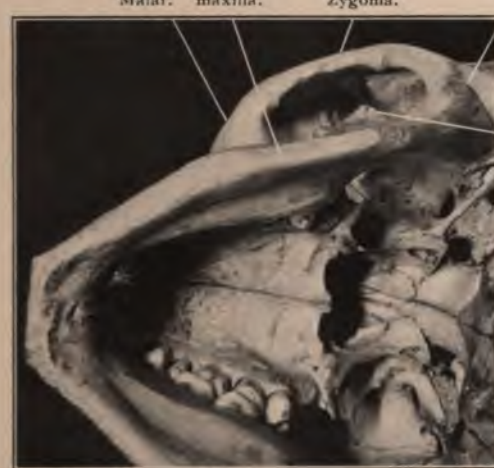

Fig. 48.—Note relations of coronoid of inferior maxilla to zygomatic process and malar bones; the space on either side of the coronoid process is filled by muscle.

tured so that the infra-orbital nerve is implicated, there will appear prickling sensations throughout the area of distribution of that nerve—namely, along the upper gum, the skin of the cheek, of the nose and of the upper lip.

Treatment.—It is oftentimes impossible completely to correct the deformity except by operative means. If any interference with the movements of the lower jaw persists after the acute swelling disappears,—that is, after two weeks,—or if it is very evident at the outset that the limitation of motion is due to the depression of bone, then operative interference is demanded. Before a cut-

ting operation is resorted to an anesthetic should be administered and an attempt made by pressure with a blunt instrument under the malar from inside the cheek to raise the depressed fragment. If this can not be effected, a small incision should be made at the most advantageous point, avoiding making the fracture an open one. Through this incision access is gained directly to the bone. By means of a narrow periosteum elevator, retractor, hook, or a screw elevator, the fragment can be raised into its normal position.

Union occurs in two weeks. There is no tendency to a recurrence of deformity, therefore no retentive apparatus is necessary.

The surgeon is not uncommonly asked to remove the slight depression attending a healed fracture of the malar bone. This may be most difficult. It should be attempted, however, as in fresh injuries, without a cutting operation, or by an incision within the mouth through the mucous membrane, or, if necessary, by an external incision.

FRACTURE OF THE SUPERIOR MAXILLA

Fracture of the superior maxilla occurs so frequently from a bicycle injury that it may properly be called the bicycle accident. The blow causing this fracture is usually not in the direction to damage the base of the skull, but to tear the bones of the face. The nasal process of the superior maxilla may be broken when the nasal bone is fractured. The anterior wall of the antrum may be broken by the same blow. The alveolar process may be broken. The damage to the bones of the face, and particularly to the upper jaw, is associated with injuries to various contiguous bones. Blows result in many irregularly disposed fractures.

The diagnosis is made by inspecting the mouth, nose, and cheek. These fractures being open, there is little difficulty in detecting them. A very careful inspection should be made, with an anesthetic if necessary, to determine the extent of the lesions. Emphysema and great swelling of the face occur. There may be no wound of the skin. Whether the injury to the upper jaw is associated with injury to the base of the skull or not can be determined in the absence of visible signs by the subsequent develop-

ment of cerebral symptoms. Necrosis of bits of bone is rare after upper-jaw fractures, excepting fracture of the alveolar border. Hemorrhage may be considerable, but it is easily controlled by pressure. The infra-orbital nerve may be damaged. The lachrymal canal may be temporarily compressed or obliterated.

Treatment.—If there is no wound of the skin and much depression of the jaw, so that the face is knocked in, it will be necessary to devise some method of elevating the depressed bone and of restoring the normal contour of the face. To avoid a visible scar, the mucous membrane should be incised on the inner side of the upper lip, and the fragments elevated by an instrument introduced through the incision. As little bone as possible should be removed, so as to leave sufficient support to the soft parts of the cheek after healing. Only thus can a falling in of the cheek be prevented. If access through the mouth is unsuccessful, it may be necessary to incise the skin over the fracture. This, of course, is to be avoided if possible. The accidental wounds should be thoroughly and vigorously swabbed with a solution of corrosive sublimate (1 : 5000). The use of tiny swabs of gauze held by forceps will facilitate this procedure. The avoidance of sepsis in these cases is of paramount importance. If the wounds become septic, there is great danger of an extension of the inflammatory process to the deeper parts or even to the meninges of the brain. Lacerations of the soft parts—lips and cheeks—may have their edges approximated to secure less scar than if left unsutured. Loose small bits of bone should be removed with forceps and scissors. Loosened teeth should be left in good position in their sockets. A mold of the lower jaw should be taken in composition or plaster-of-Paris, if possible, by a competent dentist, and a rubber splint made from this mold to fit the teeth and alveolar border of the lower jaw. When this splint is applied, its upper surface may be brought up against the teeth of the upper jaw and held snugly in apposition by an external bandage, as in fracture of the lower jaw. This splint will materially assist in reducing the displacement of the upper-jaw fragments. It may be possible for a dentist to apply a splint directly to the alveolar margin and teeth of the upper jaw. If this is possible, greater security of fragments will be obtained than by any other method

of treatment. The physician may greatly assist in immobilizing the fracture, until a permanent dressing is applied, by making quickly a temporary splint of dental wax or dental composition, and applying it to the teeth and alveolar margin of the upper jaw. This composition is softened and made malleable by placing it in hot water; it can then be molded on the jaw, and in two or three minutes is firm (see Fracture of the Lower Jaw).

After Care.—Six weeks to two months will be necessary to insure firm union and freedom from complications. The swelling associated with the reparative process will gradually subside. Great care must be exercised in the nursing of the patient after this injury, as the element of shock is an important one to be considered. Strychnin sulphate ($\frac{1}{60}$ of a grain), given two or three times daily, is indicated if there is evidence of shock following the accident. This should be continued each day for as long a period as shock is evident.

Proper nourishment under these adverse conditions of administration is to be given careful consideration. Liquids alone are to be used the first week. These may be given by enemata or by the mouth with a tube to the back of the pharynx or by a nasal tube if necessary. Nasal feeding is simply and easily carried out. A rubber tube three feet long is needed, to one end of which is attached a funnel and to the other end a soft-rubber catheter, in size No. 10 F. The patient is half reclining while the surgeon introduces the catheter into the nose until it passes well back and down into the pharynx. The funnel, somewhat elevated a foot or more above the patient's head, is kept filled with the liquid nourishment so that its contents run slowly into the esophagus. A plug of absorbent cotton, moistened with a four per cent. cocain solution, and placed in the nose for a few minutes before feeding, facilitates this procedure.

The nose and mouth should be douched and swabbed regularly each day. This should be done after feeding the patient, and oftener if necessary in order to avoid all odor from the mouth. Listerin, two teaspoonfuls to half a cup of water, is a satisfactory wash for this purpose. The profuse dribbling of saliva which attends this fracture demands drainage of the mouth by wicks of gauze placed in the cheeks and gauze handkerchiefs for keeping

the surrounding parts dry. Wiring the fragments of bone may be necessary if there is great displacement. Wiring the alveolar border to the body of the jaw may be demanded. Suture of the bony fragments with chromicized catgut will often steady them in position until union takes place.

FRACTURES OF THE INFERIOR MAXILLA

With the exception of the superior internal surface of the articular process, practically the whole of the inferior maxilla may be palpated. Fractures of the inferior maxilla are caused by direct

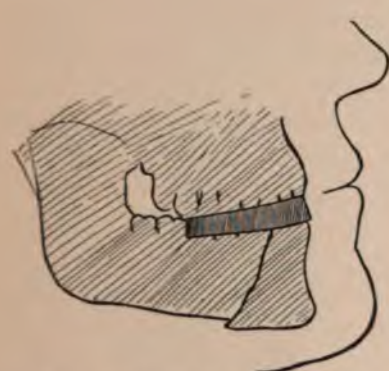

Fig. 49.—Fracture of the inferior maxilla (interdental splint) (X-ray tracing).

Fig. 50.—Fracture of the inferior maxilla in two places. Alinement of teeth perfect (X-ray tracing).

violence. The seat of the fracture will be determined by the force and direction of the blow, by the location of the teeth in the jaw (the jaw being weakest where the teeth have been lost), by the presence of any foreign body between the teeth (such as a pipe), and by the presence or absence of muscular relaxation. Fractures of the base of the skull through blows on the jaw are more likely to occur if the mouth is open. Fractures of the body of the bone are common; of the ramus behind the molar teeth, rather uncommon; of the condyloid and coronoid processes, very uncommon. The seats of fracture of the inferior maxilla are shown in the accompanying illustrations (see Figs. 49, 50, 51, 52).

Excepting those of the condyloid and coronoid processes, fractures of the inferior maxilla almost always open into the mouth. They occasionally open through both the mucous membrane and the skin.

Fig. 51.—Fracture of the inner side of the alveolar process, from a force applied to teeth.

Examination.—Even when the patient can not open the mouth sufficiently to admit the examining finger, palpation of the body and ramus of the jaw, with one finger in the cheek and another finger upon the chin, will often reveal the seat of fracture.

Symptoms.—Pain, crepitus, and abnormal mobility may be present. Immediate swelling of the gum appears at the seat of the fracture. Teeth contiguous to the fracture of the body of the maxilla will be either displaced or loosened. The displacement of the fragments in fracture of the body and ramus will be most

Fig. 52.—Fracture of the lower jaw, showing loss of alinement of teeth.

easily detected by noticing the differences in level of the teeth on each side of the fracture (see Fig. 52). The face appears swollen.

After a few days the submaxillary and adjoining cervical lymphatic glands become enlarged. The salivary secretions are increased in quantity, and because of the disinclination to painful swallowing, the saliva dribbles out of the mouth. If the fracture opens into the mouth, suppuration often appears and pus mingles with the saliva. Particles of decomposing food between the teeth and in the spaces outside the jaw within the cheeks add to the bacterial pabulum. The odor from this mass of foul material is characteristically penetrating and offensive. After a few weeks necrosis of bone may occur at the seat of fracture, with abscess formation. A discharging sinus pointing to the disease appears.

Fig. 53.—Aluminium splint to be placed on teeth. For closed fracture, a continuous capping of gold or aluminium or other metal cemented upon the teeth.

These cervical abscesses, often difficult to manage, occupy the region of the body of the jaw. The submaxillary and upper carotid triangles may be filled by a brawny infiltration associated with necrosis of a fractured jaw. On the other hand, with proper treatment and in less difficult cases the course of the healing process is simple and of easy management. Suppuration is prevented. There is no necrosis, and the repair of the fracture takes place unhindered.

Treatment.—The primary object of treatment is the preservation of the natural alinement of the teeth. This object is attained by a complete reduction of the fragments of the fractured

bone. If a tooth interferes with the perfectly accurate closure of the mouth, and if the adjustment of the fragments is prevented by the position of the tooth, it should be extracted at once. Ordinarily, there is but slight displacement. This displacement can be corrected by digital pressure upon both fragments.

Fracture of the Body of the Jaw.—The simple fracture of the body of the jaw without much displacement may be temporarily treated by the four-tailed bandage, which should hold the teeth of the lower jaw closely in apposition with the corresponding teeth of the unbroken upper jaw. As soon as practicable, a dental

Fig. 54.—Four-tailed bandage for fractured jaw.

splint of rubber or aluminium should be made and applied by a dentist. This aluminium splint fits the crowns of the teeth some distance upon each side of the fracture, and holds the fragments firmly in apposition (see Fig. 53). It also permits of opening and shutting the mouth. The old-time four-tailed bandage and extra-dental splint of millboard (see Fig. 54) is inefficient. As a permanent dressing it should be discarded. It is useful only as a temporary support. In the simple cases, in the absence of a competent dentist to make the aluminium or rubber dental splint, a splint of silver wire passed around many teeth upon each side of the seat of fracture is often efficient. The method of wiring two

adjoining teeth, those on each side the fracture, is unsatisfactory in that the strain loosens the teeth and displacement is easily effected (see Fig. 55).

Fig. 55.—Fracture of the lower jaw. Wiring with silver wire.

Fig. 56.—Hard-rubber splint, with arms and posterior strap.

Fracture of the body toward the angle of the jaw, through the region of the molar teeth, is often less easily held in good position. To the dental rubber splint the dentist should add lateral arms of

wire, held in position by a posterior strap (see Fig. 56). These wire arms increase the efficiency of the dental splint, for a band-

Fig. 57.—Hard-rubber splint, with arms and bandage, applied. Similar to figure 56 (Moriarty).

Fig. 58.—Hard-rubber splint; wire arms and chin-piece held together by metal rods and nuts.

age is passed under the chin between the wires and thus steadies the jaw by upward pressure (see Fig. 57). If a still more efficient method is demanded, the dentist uses an extradental chin-piece

Fig. 59.—Same splint as seen in figure 58; superior view.

Fig. 60.—Front view of splint (figure 58) with mouth closed (Moriarty).

Fig. 61.—Side view of splint (figure 58); arms and chin-piece in position (Moriarty).

Fig. 62.—Splint similar to figure 58. Mouth may be opened without impairing efficiency of splint (Moriarty).

of metal (see Fig. 58), which is adjusted by screws so that firm, evenly graduated pressure upon the fractured jaw is maintained between the inside dental splint and the outside chin-piece. While wearing this splint the mouth can be opened easily (see Figs. 60, 61, 62).

The Making of the Dental Splint.—If an impression is desired of the crowns of the teeth and the adjoining gum, it is best made by using the modeling composition manufactured for the use of dentists. The necessary amount of the composition is dropped into hot water; when soft, the composition is put into the metal

Fig. 63.—Modeling cups: A, Used for the upper jaw; B, used for the lower jaw.

impression-cups (see Fig. 63). The surface of the composition is warmed by holding it over a flame or holding it again in hot water; then the impression-cup containing the softened composition is placed in the mouth and the impression made. Immediately upon the removal of the mold from the mouth the composition cools and hardens. From this mold is made the duplicate of the alveolar border and the teeth in plaster-of-Paris (see Fig. 64). The lines of fracture are clearly indicated upon the plaster cast. With a fine saw the cast is cut upon these lines and the lower teeth are articulated with the plaster cast of the upper jaw, which has been

Fig. 64.—Plaster cast of fracture of the jaw.

Fig. 65.—Plaster cast of lower jaw articulating with upper jaw.

Fig. 66.—Simple vulcanite splint, with boxes vulcanized on each side (Moriarty).

Fig. 67.—Hard-rubber splint in position, upper teeth resting upon it (Moriarty).

made. Plaster cream is used to hold the sawed portions together. In other words, the fracture has been reproduced and reduced in plaster-of-Paris. Both upper and lower casts are then put upon an articulator (see Fig. 65). A vulcanite splint is made from this reconstructed lower jaw, and when this is applied to the fractured jaw as an interdental splint, the deformity is corrected and comfortably prevented from recurring (see Figs. 66, 67).

Fracture of the Ramus of the Inferior Maxilla Just Behind the Molar Teeth.—The displacement is difficult to correct. The fracture is usually oblique from before backward and downward, as seen in the tracing (see Fig. 50). The body of the jaw drops

Fig. 68.—Interdental splint used in fracture of the jaw when no teeth exist in upper alveolar arch (after Moriarty).

downward and backward and the ramus slides forward. No dental splint is practicable, because there are no teeth on one side of the fracture to which the splint could be attached. Etherization will often be found helpful, and at times necessary, in the reduction of this deformity. Reduction is accomplished by pressure backward upon the ramus with the thumb in the mouth and a simultaneous lifting forward and upward of the body of the jaw. Reduction is maintained by an outside pad and metal chin-piece and a buckle and strap splint. This buckle and strap splint (see Fig. 69) is of great advantage because it is easily adjusted, and the amount of pressure can be graduated. It is of importance to

note here that even after this fracture has been reduced and is at the outset apparently held reduced by the bandage, yet it will usually slump away a little and at the end of the first twenty-four hours after setting the fracture the fragments will be found to be partially unreduced. Upon a second application of pressure by tightening the bandage the fragments will come into apposition with comparative ease. By careful and repeated adjustments of the bandage and padding, after a week and a half even in the most obstinate cases, the jaw will be found to be in good position, with the teeth articulating.

Fracture of the Body of the Ramus upon the Same or Opposite Sides of the Inferior Maxilla.—The fracture is difficult to hold

Fig. 69.—Molded leather chin-piece with buckles and straps for graduated pressure upon a fracture of the inferior maxilla (after Moriarty).

fixed. In this case the dental aluminium or rubber splint will be needed, together with the outside pressure made by the metal chin-piece.

Whichever method of treatment is adopted, the fracture at first should be inspected daily in order to insure accurate adjustment of apparatus. The mouth and teeth should be kept scrupulously clean. When practicable, the teeth should be scaled by a dentist before permanent apparatus is applied. Brush and swab with some mild antiseptic wash, such as Listerin, one part in four of water, should be used after taking nourishment and before bedtime and upon rising in the morning. The liquid nourishment of

the patient should be given through a glass tube at first. If it is unwise to open the mouth, a rubber catheter may be used behind the molar teeth. The rubber catheter with a siphon attached is a very satisfactory method of feeding. The general health should receive careful attention. A patient with this fracture is apt to become despondent and anxious about himself, particularly if suppuration exists. The repeated swallowing of foul secretions impairs the appetite, causes indigestion and generally poor health. The loss of variety in diet favors this condition. Out-of-door exercise, plenty of sleep, a mild tonic, such as ferrated elixir cali-

Fig. 70.—If no lower teeth exist, the artificial teeth may be utilized, as seen above, as a splint. Boxes seen on sides of plate, to which arms and chin-pieces can be attached (after Moriarty).

sayæ and sulphate of strychnin, and a little wine, will all assist in restoring and maintaining good health.

Abscesses which appear should be treated by incision, evacuation of their contents, drainage, and antiseptic dressings. Bits of necrosed bone should be removed. Union in fracture of the jaw occurs ordinarily in from three to five weeks. The apparatus is to be worn until the union of the fracture is firm.

Fracture of the coronoid and articular processes is to be treated by simple immobilization of the jaw.

These various methods of immobilization mentioned may fail in some unusual fractures; if so, suturing of the fracture through the bone with silver wire or other material should be undertaken.

CHAPTER III

FRACTURES OF THE VERTEBRAE

Anatomy.—The forked spine of the axis may be felt beneath the occiput upon deep pressure. The spines of the third, fourth, and fifth cervical vertebræ recede from the surface, and can not be felt distinctly. The spines of the sixth and seventh vertebræ project distinctly, and can be palpated. At the bottom of the furrow in the middle line of the back are felt the spines of the dorsal and lumbar vertebræ. The spinous processes from the seventh cervical to the third sacral are rather easily palpated. The spinal cord extends from the lower edge of the foramen magnum to the lower border of the body of the first lumbar vertebra. The phrenic nerve leaves the spinal canal between the third and fourth cervical vertebræ. By palpation through the mouth (see Figs. 71, 72) the bodies of the vertebræ may be felt down to about the upper border of the body of the fifth vertebra. The cervical enlargement of the spinal cord is more marked than the lumbar. It commences at the third cervical vertebra and ends at the second dorsal vertebra. The lumbar enlargement commences at the level of the ninth dorsal vertebra and reaches to the twelfth dorsal vertebra. The spinal cord is well protected from injury (see Fig. 73).

The vertebræ commonly fractured are the fourth, fifth, and sixth cervical, the twelfth dorsal, and the first lumbar. The injury to the vertebræ is caused in one of three ways: by a direct blow, fracturing the arches; by a fall upon either the head or the buttocks, crushing the bodies of the vertebræ; or by forced flexion or extension of the spine, causing a dislocation with or without fracture of the bodies and articular processes. More than one-half of the fractures of the cervical vertebræ are fractures of the spinous processes. More than two-thirds of the cases of fracture of the dorsolumbar vertebræ are fractures of the bodies

of those vertebræ. A dislocation without fracture may occur in the cervical region; it is rare in other regions of the spine.

Fig. 71.—Palpating the bodies of the first and second cervical vertebræ through the mouth.

Fig. 72.—Palpating the bodies of the cervical vertebræ through the mouth. Finger reaches about to the fourth cervical vertebra.

It is important in localizing spinal-cord lesions to know the point at which each nerve arises from the spinal cord, because the point of origin does not correspond with that at which the nerve

emerges from the spinal canal (see Fig. 74). The point of origin is higher than the point of exit. Many of the nerves pass obliquely from the cord, lying still within the vertebral canal after leaving the cord (see Fig. 75). These nerves within the canal are liable to pressure from the vertebral fracture. For example, a fracture of the eleventh dorsal vertebra would injure not only the cord

Fig. 73.—The cord and its membranes in relation to a vertebra (diagram): *a*, Extradural space; *b*, dura; *c*, subarachnoid space; *d*, spinal cord.

Fig. 74.—Frontal section of fourth, fifth, and sixth cervical vertebræ and cord, showing the origins of spinal nerve-roots (after Rüdinger).

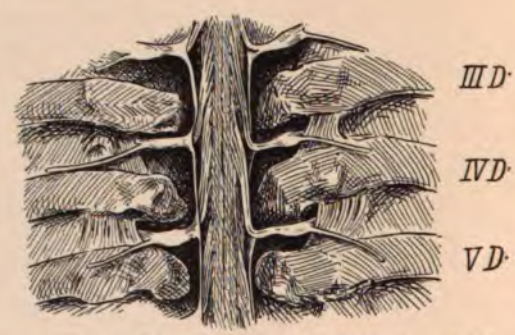

Fig. 75.—Frontal section of third, fourth, and fifth dorsal vertebræ, showing oblique course of nerve bundles running downward (after Rüdinger).

at this level, but in addition might injure the last dorsal and upper lumbar nerves. The lower the spinal nerves arise, the longer is their intraspinal course. The points of origin of the spinal nerves from the cord with reference to the spines of the vertebræ are as follows (see Fig. 76): The eight cervical nerves arise from the cord between the occiput and the sixth cervical spine. The upper six thoracic nerves arise from the cord between the sixth cervical

spine and the fourth dorsal spine. The lower six thoracic nerves arise from the cord between the fourth and tenth dorsal spines. The five lumbar nerves arise from the cord opposite to the eleventh and twelfth dorsal spines. The five sacral nerves arise from the cord opposite to the first lumbar spine. No hard-and-fast rule at present is applicable to the enumeration of the lesions following fractures and dislocations of definite vertebræ. From the combined experience of such clinicians as Gowers, Thorburn, Kocher, Putnam, Dennis, Walton, Bullard, Thomas, and others the following table is constructed, and is valuable for practical use:

TABLE STATING LESIONS FOLLOWING INJURY TO DEFINITE VERTEBRÆ.

Spinal Segments.	Muscles Involved.	Vertebræ Dislocated.	Reflexes Involved.
Cervical:			
First, second, third	[Death].	Skull on atlas, atlas on axis.	
Fourth	Diaphragm.	Axis on third cervical.	Pupil is small and reaction sluggish.
Fifth	Biceps, supinators, deltoid.	Third on fourth.	
Sixth	Pronators, triceps.	Fourth on fifth.	
Seventh	Extensors, flexors of wrist.	Fifth on sixth.	
Eighth and first dorsal	Intrinsic muscles of hand.	Sixth on seventh.	
Dorsal:			
Second to twelfth	Intercostal and abdominal muscles (trunk).	...	Epigastric, abdominal.
Lumbar:			
Second	Cremaster.	Eleventh on twelfth dorsal.	Cremasteric.
Third, Fourth, Fifth	Adductors. Outward rotators. Extensors of thigh, flexors of knee.	Twelfth on first lumbar.	Gluteal. Knee-jerk.
Sacral:			
First	Extensors of foot.	First on second lumbar.	Plantar and ankle-clonus.
Second	Calf muscles.		
Third, fourth, fifth	Perineal muscles.		

Examination of an Injury to the Spine.—Four questions are to be answered: What was the nature of the accident? What does palpation of the spine reveal as to the nature of the lesion? What is the level of the lesion? Is the lesion partial or complete?

General Symptoms Common to Fractures of the Vertebræ.—Signs of shock will be present. At the seat of the bony lesion will be found pain, tenderness, abnormal mobility and sometimes

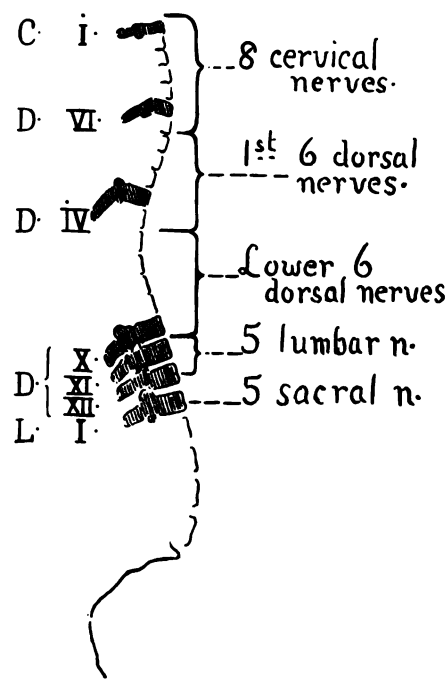

Fig. 76.—Diagram of spinal origin of nerves, according to the level of the spinous processes.

crepitus and deformity. The deformity will ordinarily be a backward bending, or kyphosis, of the spinal column at the seat of fracture, unless there exists a unilateral dislocation, when the deformity will be irregular in appearance. The chief symptoms depend upon the injury done to the spinal cord. In general it may be stated that motor and sensory paralysis, either partial or complete, will be found up to the level of the lesion. The reflexes are ordinarily below the lesion, wanting at first and increased later. If

a complete lesion is present the reflexes will be entirely wanting. Retention, and later incontinence, of urine and feces will exist. Cystitis of the urinary bladder will develop at an early date. Bed-sores and great sloughing areas of skin upon dependent parts will be discovered early. Priapism occurs.

Symptoms of Fracture of the Different Regions of the Spine, the Cord Being Involved.—*Injuries to the Last Dorsal and Lumbar Vertebræ* (see Figs. 77, 78, 79).—The spinal cord ends opposite the lower border of the first lumbar vertebra. Any pressure at this point or below will involve the cauda equina in

Fig. 77.—Fracture of the twelfth dorsal vertebra. Anesthesia to the height of the anterior superior spinous processes in front. Second lumbar nerve involved.

whole or in part (see Figs. 80, 81). Local evidences of the bony lesions may be present. The paralysis of the legs may be partial or complete. The anesthesia of the lower limbs is partial rather than complete and up to the level of the bony lesion. Retention or incontinence of urine and feces exists. The paralyzed muscles rapidly become wasted. Constant pain and hyperesthesia may be present both above and below the lesion. The patellar and plantar reflexes are usually lost.

The prognosis is not altogether unfavorable to recovery. Partial recovery is possible. Later, muscular contractures will exist in the lower limbs, which impede walking. If at the end of six

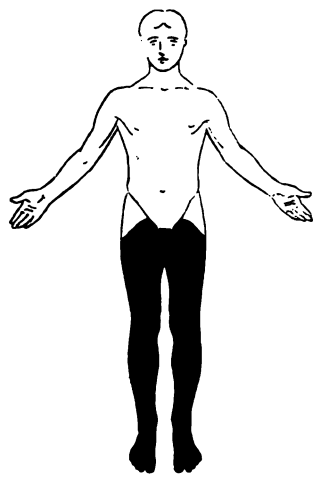

Fig. 78.

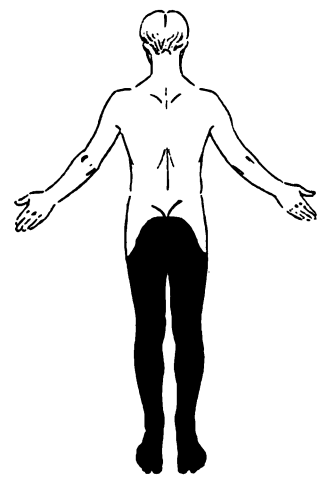

Fig. 79.

Figs. 78, 79.—Fracture of the twelfth dorsal vertebra without involvement of the first lumbar nerve-roots, the ilioinguinal, iliohypogastric, and external cutaneous nerves not being involved.

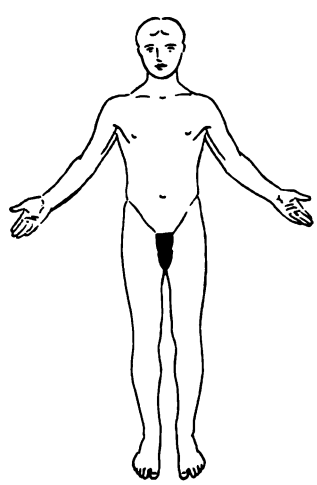

Fig. 80.

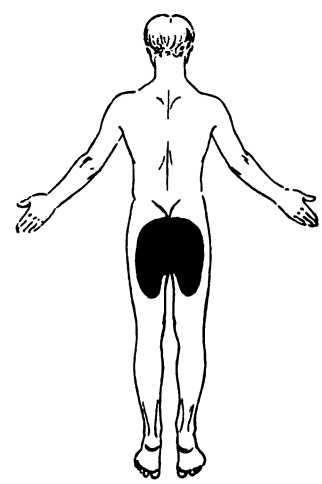

Fig. 81.

Figs. 80, 81.—Injury to the cauda equina, which has involved the third sacral nerves. Fracture of the first lumbar vertebra or the second lumbar vertebra.

weeks evidences of beginning recovery do not appear, or if recovery once begun has ceased, it will be wise to operate upon injuries to the cauda equina.

Injuries to the Dorsal Vertebræ (second to the eleventh) (see

Fig. 82.—Sixth dorsal vertebra fractured. Anesthesia at the level of two inches above the umbilicus. The eighth or ninth dorsal nerve involved.

Fig. 83.—Lesion of spine between fifth and sixth cervical vertebræ. Note position of arms, due to paralysis of subscapularis. Biceps brachialis anticus, supinator longus and deltoid muscles intact. Elbow flexed, shoulders abducted and rotated outward (after Thorburn).

Fig. 84.—Luxation of sixth and seventh cervical vertebræ; typical attitude; center for subscapularis not involved. Contrast figures 83 and 84 (after Kocher).

Fig. 82).—The simple distribution of the spinal dorsal nerves below the first makes the interpretation of injuries to this region much easier than similar injuries to the cervical or lumbar regions. The arms escape paralysis. The motor and sensory paralysis extends ordinarily to the height of the bony lesion. In a few cases

in which the nerve-trunks within the canal are not implicated the level of the paralysis will be lower than the lesion. The patellar reflexes are at first generally lost in the severer types of fracture. If the patient recovers, there will be spastic paralysis if the injury is above the lumbar enlargement. If the lumbar enlargement is involved, there may be great pain in the legs.

Injuries to the Cervicodorsal Region, Opposite the Cervical Enlargement of the Spinal Cord.—The arms escape paralysis, perhaps, at first, but become involved after several days. The paralysis is often partial. Respiration is diaphragmatic only. Pain in the arms is quite constant. If the sixth vertebra is dislocated upon

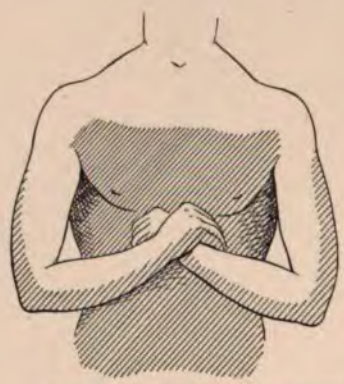

Fig. 85.—Lesion of spine between sixth and seventh cervical vertebræ. Position in case of complete transverse destruction of the cord just below nuclei for subscapularis; areas of anesthesia shown (after Thorburn).

Fig. 86.—Atlas, axis, and third cervical vertebra from the front. Case: man, thirty-eight years of age; fell from a cart. Fracture of odontoid process. Slight hemorrhage into the medulla. Death after forty-eight hours (Cabot).

the seventh, the intrinsic muscles of the hand will be paralyzed. If the fifth vertebra is dislocated upon the sixth, there will appear a characteristic position of the upper extremities (see Fig. 83): abduction of the arms, flexion of the forearms, with rotation outward of the whole extremity. If the injury is above the sixth cervical vertebra, there will be anesthesia of the entire limb excepting the shoulder. The attitude after lesions between the sixth and seventh cervical vertebræ is shown in figure 84. The characteristic attitude in lesions between the sixth and seventh cervical vertebræ is also shown in figure 84.

Injuries to the Midcervical Region.—A lesion of the third cervi-

cal vertebra will involve the phrenic nerve. The diaphragm will be paralyzed. Death will occur within a few hours.

Injuries to the First Two Cervical Vertebræ (see Figs. 86, 87).—If the displacement is slight, life may be spared until sudden displacement occurs or a secondary myelitis causes death. Cases of recovery are recorded. Death usually occurs instantly. Perhaps one person in fifty thus injured recovers (Gowers).

Prognosis.—The prognosis depends upon the amount of injury to the spinal cord. The prognosis is less grave than it was thought to be a few years ago. There is a probability of saving a certain proportion of cases. In general, the nearer the fracture approaches

Fig. 87.—Fracture of the atlas and axis. Man, seventy-four years of age; fall; immediately left arm paralyzed. No loss of consciousness, speech thick. Neck movements normal. Twenty-four hours after the accident, suddenly difficult breathing appeared and death followed (Brooks).

the medulla oblongata and the foramen magnum, the more serious does the outlook become. Patients with fracture in the dorsal and lumbar regions die in the course of months from cystitis, pyelitis, and exhaustion. Patients with fractures in the upper dorsal and lower cervical regions die in a few days or weeks from hypostatic pneumonia. Patients with fractures high up in the cervical region die instantly or in a few hours from shock and direct pressure upon the medulla oblongata.

Treatment.—The object of treatment is to relieve the cord from pressure and to immobilize the fracture. The cord will be uninjured, slightly injured, or injured seriously. If the cord is

uninjured, the bony parts may be left untouched or they may be replaced by manipulation or operation. If the cord is injured, the advisability of operative interference will depend upon whether the lesion of the cord is transverse and complete, or whether it is partial. If there are evidences of a transverse lesion, operation is unavailing and obviously illogical, for the cord can not be repaired. It is necessary, therefore, to distinguish between *the signs of a transverse lesion and those of a partial lesion.* In a complete transverse lesion the history of the onset of the symptoms is a sudden one, the symptoms appear immediately following the fracturing trauma; whereas, if a partial injury is present, an interval will have elapsed before the symptoms develop; the appearance of symptoms is gradual rather than sudden. In a complete transverse lesion the motor paralysis is found to be complete, and the paralyzed muscles are flaccid; whereas if the lesion is a partial one, the motor paralysis is limited, some muscles of the limbs are paralyzed, others are not, and there is often noticed muscular spasm in the affected limbs. In a complete transverse lesion sensation is entirely gone; whereas in a partial lesion some sensation is present. The knee-jerks are variable; in the complete transverse lesion they are absent. In the partial lesion the knee-jerks are apt to be absent at first, and they may return later. In the transverse lesion the paralysis of the bladder and rectum is complete; whereas in the partial lesion paralysis of these organs is not

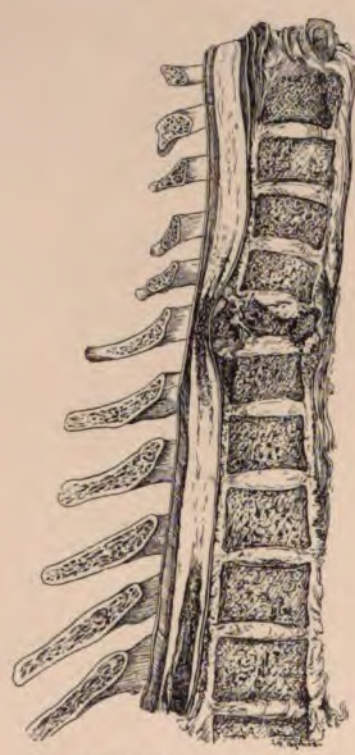

Fig. 88.—Fracture of the cervical spine; cord compressed by bone and blood. Hemorrhage into the cord at the seat of the lesion and below the lesion (Warren Museum). (Drawn by Byrnes.)

Fig. 89.—Spine sawed in sagittal section, showing fracture through the intervertebral disc between the sixth and seventh cervical vertebræ, with dislocation forward of the upper fragment. Partial crush of the cord (Thomas).

Fig. 90.—Spine sawed as before. Fracture of the spinous processes of the seventh cervical and first and second dorsal vertebræ. Fracture of the bodies of the fifth, sixth, and seventh cervical vertebræ with displacement *backward* of the upper fragment. Total crush of the cord. The section passes a little to one side of the cord, which is seen in place, and the staining of the cord by hemorrhage into its substance shows plainly through the membranes, even in the photograph. The spinous processes of the second and third dorsal vertebræ were found fractured at the operation, and were removed (Thomas).

Fig. 91.

Fig. 92.

Figs. 91 and 92.—Spine sawed as before. Fracture of spines of fifth cervical and fourth, fifth, and sixth dorsal vertebræ. Fracture of body of sixth dorsal vertebra. Displacement forward of upper fragment. Total crush of the cord, the softened substance of which has been removed by the saw, leaving only the empty and blood-stained meninges at this point. Figure 91 shows the spine as sawed; figure 92, the same hyperextended, showing the obliteration of the narrowing of the spinal canal (Thomas).

always present. Priapism, sweating, and involuntary muscular twitchings are seen more commonly in case of injury to the spine associated with complete lesions of the cord than in cases with partial lesions of the cord. In partial lesions variations from the

Fig. 93.

Fig. 94.

Figs. 93 and 94.—The two halves of the spine sawed in sagittal section. Fracture of the seventh cervical vertebra, with dislocation forward of the upper fragment. Fracture of the arch of the sixth and of the spine of the seventh vertebræ. Total crush of the cord. The discoloration of the cord from blood shows plainly in the plate (Thomas).

definite types of symptoms are seen. The symptoms are more or less irregular. In total lesions of the cord operation can do no good. The cases of pressure from fragments of bone—that is, those occurring for the most part in the cervical region, in which the laminæ of the vertebræ are fractured—demand operation.

All other cases of bony pressure are those due to dislocation of vertebræ which are remediable either by operation or manipulation. In these cases the prognosis depends upon the damage done the cord.

It is the result of experience that in cases of injury to the spine severe enough to do damage to the cord usually irreparable injury has been done by either a distinct crush of the cord or hemorrhage into the cord. Hemorrhage into the cord takes place often extensively and some distance from the seat of the chief lesion, so

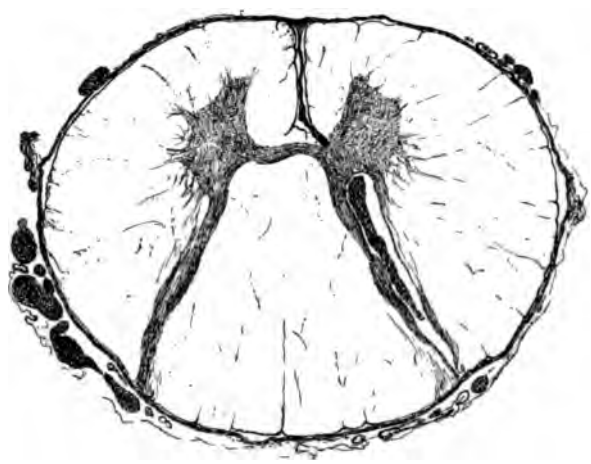

Fig. 95.—Case: Man, fracture of spine; transverse section of spinal cord above the lesion. Hemorrhage into posterior horn (Taylor). (Drawn by Byrnes.)

that even if the seat of the crush of the cord were reached by operation, damaging lesions would still remain unrelieved.

It is also a result of experience that removal by operation of the laminæ and spines of the vertebræ in the suspected region of fracture very rarely—almost never—reveals any remediable condition or affords any evidence of the exact seat of the lesions or their extent. The reason for these facts is that the dura at the seat of a crush of the cord, whether partial or complete, remains intact and untorn, and that extradural hemorrhage is unusual. The surgeon, therefore, after removal of the laminæ, is as much in doubt as he was before. Operation, therefore, in complete lesions holds out no hope of benefit. It is said that the chances of the

symptoms being due to pressure by extradural blood-clot or bone justify operative interference in these apparently hopeless cases. This is true in those cases in which the lesion of the cord is partial, but never when the lesion is completely transverse.

Operative interference, then, may be summarized somewhat as follows:

In partial lesions operation may be demanded; in fracture of the laminæ and spines operation is demanded; in all lesions of the cauda equina operation is demanded; in almost all complete lesions operation is contraindicated.

It is an interesting fact clinically and pathologically that in

Fig. 96.—Case: Man, fracture of spine; transverse section of spinal cord below the lesion (Taylor). (Drawn by Byrnes.)

cords compressed at a definite level with destruction of the cord, at the seat of compression there is often found a hematomyelia (hemorrhage into the substance of the cord) several vertebræ above and below the fracture, thus showing how extensive is the acting force.

A study of the drawings made from actual sections of the spinal cords of cases of fracture of the spine will indicate the different lesions already mentioned.

Figure 88 is from a fracture of the cervical vertebræ, showing destruction of the cord at the seat of the lesion, with localized pressure from bone and blood. Low down is seen an extensive

extradural hemorrhage and a hematomyelia some distance from the original trauma.

Fig. 97.—Case: Man, fracture of spine; transverse section of spinal cord at the seat of lesion (Taylor). (Drawn by Byrnes.)

Fig. 98.—Case: Fracture of the spine; transverse section of spinal cord several segments from the lesion; hemorrhage into the white matter (Taylor). (Drawn by Byrnes.)

Figure 95 is from a dislocation and fracture of the fifth upon the sixth cervical vertebra. There was complete paralysis below the

lesion. Trephining was done. The patient lived without improvement seventeen days. This section of the cord is taken a little above the lesion and shows clearly a hematomyelia of the right posterior cornu.

Figure 96 is taken from a section of the cord of the preceding case a little below the lesion, showing complete destruction of the gray matter of the cord; the dura remained intact.

Fig. 99.—Fracture of lumbar vertebræ (Warren Museum).

Fig. 100.—Partial fracture of twelfth dorsal and fracture of first lumbar vertebræ. Fall of twenty feet on nates. Paraplegia and sphincter paralysis. Death nine months after accident. Died of phthisis. Type of compression fracture (Warren Museum, specimen 941).

Figure 97 is also taken from a section of the cord of the preceding case, but at the seat of the lesion, showing a destruction of the gray and white matter of the cord anteriorly next to the bodies of the vertebræ. The dura remained intact, there being to the operating surgeon no evidence posteriorly of any disturbance having occurred anteriorly.

Figure 98 is a section of the spinal cord of a woman who fell from a trapeze to the net, and fractured and dislocated the sixth

cervical vertebra. Operation was done. She lived three days. A little distance (two segments) from the seat of the lesion, where the cord was crushed anteriorly, was found a hematomyelia of the white matter posteriorly. The dura was intact.

These specimens, which illustrate the common lesions of the spinal cord following fractures and dislocations of the vertebræ, demonstrate the utter futility of operative interference in cases of crush of the cord with signs of a complete transverse lesion.

Fig. 101.—Old fracture of twelfth dorsal vertebra, from fall of thirteen feet; canal narrowed. Total paralysis of motion and sensation below injury. Died two years after accident (Warren Museum, specimen 4629).

Fig. 102.—Fracture of twelfth dorsal vertebra. Laceration of intervertebral disc above twelfth vertebra; crushed by fall of ceiling. Paralyzed from below navel. Paralysis of bladder and rectum. Died nine and a half weeks after the accident.

The Immediate Rectification of the Deformity and Immobilization by the Plaster-of-Paris Jacket.—With our present knowledge of the pathology of these fractures, *and excepting cases of fracture of the vertebral arch alone and pressure upon the cauda equina and partial lesions of the cord,* there can be no doubt that the best treatment for fracture of the vertebræ is by means of expectant methods. The methods are as follows: Immobilization of the part by a plaster-of-Paris jacket applied to the trunk, if there is no deformity. If there is deformity, correction of it and immo-

bilization of the spine in the corrected position. The correction of the deformity must be immediate to avoid irremediable softening of the cord from pressure; and this may occur even within forty-eight hours.

Method of Applying the Plaster-of-Paris Jacket.—This differs in no respect from the usual methods of application, with the exception that the patient should be protected from any unusual or sudden jar or movement. The trunk having been properly protected by a tightly fitting shirt, the patient is carefully placed prone in a hammock. The patient may be placed upon two

Fig. 103.—Fracture of seventh dorsal vertebra, with great displacement of fragments, from a fall of thirty feet. Paraplegia, loss of sensation from nipple down. Sensation later recovered down to navel. Died two months after accident (Warren Museum, specimen 6229).

Fig. 104.—Dislocation forward of sixth cervical vertebra, from fall on head. Total paralysis below nipples. Temperature rose to 110° F. Died eighteen hours after accident. Illustrates displacement of spinous processes (Warren Museum, specimen 4904).

kitchen tables, which are gradually pulled apart, allowing the trunk to be unsupported between the tables until the desired extension is obtained. If the tables are used, great care must be exercised that proper assistants secure the shoulders and hips of the patient during the procedure. Gentle, firm pressure is made upon the projecting vertebral spines until reduction is complete. The jacket, reinforced posteriorly by extra layers of bandage, is then applied. Death may occur instantly during this procedure,

but if gentle measures are used, the likelihood of such a catastrophe will be modified. An anesthetic given to primary anesthesia is often of service. A sufficient number of assistants should be at hand—there should be at least four.

It is, of course, impossible to say what cases will be saved by this means, but it has been proved to be a life-saving measure in a few cases. The patient will be more comfortable and more easily managed after such a procedure. The hopelessness of the results of

Fig. 105.—Fracture and subluxation; cervical vertebræ united (J. Mason Warren collection, Warren Museum) (Walton).

fractured spine justifies the surgeon in undertaking almost any risk.

Cystitis.—Life may be prolonged, if not saved, by the proper treatment of this distressing affection, which is always associated with fracture of the spine. In a number of these cases death is due to a pyelitis and nephritis following a cystitis. These complications may be avoided for a definite time if the bladder is thoroughly drained by urethral catheter or by perineal drainage. The bladder may be kept aseptic by douching regularly with a solution

of boric acid or permanganate of potash and by the internal use of urotropin. Great care should be exercised in the avoidance of bed-sores; it is easier to prevent than to cure them.

Summary of Treatment.—Fracture of the arches of the vertebræ, whether open or closed, should be subjected to operation. Fracture and compression of the cauda equina after six weeks of waiting for spontaneous recovery should be treated by operation. In partial lesions of the cord operation may be demanded. All other fractures showing a complete transverse lesion of the cord should be treated expectantly.

GUNSHOT FRACTURES OF THE VERTEBRAE

These open fractures arrange themselves into three groups for practical purposes.

First group. Those cases in which the viscera of the thorax or abdomen are simultaneously injured.

Second group. Those cases in which the bullet has entered the spinal canal and has injured the spinal cord.

Third group. Those cases in which the spines and laminæ or the arches of the vertebræ are injured.

Treatment.—In all cases the external wound should be carefully cleansed and protected by an antiseptic dressing.

The degree of shock should be observed. Any signs of a lesion of the cord should be recorded. Evidence of damage to the viscera within the chest or abdomen should be sought for.

In the absence of great shock it is wise for the surgeon, under antiseptic and aseptic conditions, to lay open the wound, to thoroughly disinfect it and to attempt to ascertain the condition of the cord and vertebræ. If the symptoms point immediately to a transverse lesion of the cord extensive operation is contraindicated.

The character of the damage done by the bullet to the vertebræ and spinal cord cannot be wholly determined except by operation. In operating there is always the possibility of diminishing the chances of infection through the bullet wound and of relieving pressure upon the spinal cord from blood clot and fragments of bone.

A crushed cord is not incompatible with life. Such a patient may live for several months or even for several years. Operation may prevent death from sepsis, even if a crush of the cord exists.

CHAPTER IV

FRACTURES OF THE RIBS

Anatomy.—Palpation of most of the ribs is comparatively easy. The upper seven ribs on each side articulate with the sternum. The eighth, ninth, and tenth ribs are connected by the costal cartilages anteriorly, but the eleventh and twelfth ribs have no anterior attachment. These lowest ribs are, therefore, less liable to fracture. The first two ribs are somewhat protected by the clavicle from direct violence, although great depression of the shoulder may bring the clavicle to bear directly upon the first ribs, and this may be a cause of fracture. The ribs are so elastic in childhood that fracture then is extremely rare. Direct violence is the common cause of fracture.

Symptoms.—In partial fractures there may be no symptoms. Upon forcible expiration (as in sneezing, coughing, laughing, crying, or in breathing hard) pain may be felt at the seat of fracture. So definite is the pain that the patient may be able to place his finger accurately upon the seat of fracture.

Crepitus is often felt by the patient when moving or making an expulsive effort. Crepitus is elicited for the examiner by firmly placing the palm of the hand flat upon the chest at the supposed seat of fracture when the patient coughs. If crepitus is present at the time of coughing, a slight crunch or click will be felt and sometimes heard. The stethoscope placed near the supposed fracture will often assist in detecting the crepitus. The ribs should be palpated systematically, and the chest slightly compressed between the two open hands anteroposteriorly and laterally to detect crepitus. The natural inclination of the ribs should be borne in mind during palpation. Respiration will be short and catchy, and accompanied by a characteristic grunt.

The attitude and movements of the patient are very deliberate, guarded, stiff, and in severe cases suggest the movements of a child

with acute caries of the dorsal spine. There may be a slight cough.

Complications of Fracture of a Rib.—Injury to the pleura and lung not uncommonly occurs. Its existence is manifested by cough, bloody expectoration, and emphysema. Emphysema may extend over the whole chest and up over the neck and face (see Fig. 106), and even over most of the body. Emphysema unassociated with a wound of the superficial soft parts is of little importance. Pneumothorax may be present. Injury to the heart and pericardium and hemorrhage from an intercostal artery

Fig. 106.—Case: Emphysema following fracture of the ribs on the right side. Note the puffiness of the face—the eyes almost closed (Warren).

are unusual. A dry pleurisy, disappearing rapidly, localized at the seat of fracture, is quite commonly detected by the stethoscope. The relations of a rib to the pleura and intercostal vessels are important in this connection (see Fig. 109).

Treatment.—The complications must be attended to according to medical principles. A cough mixture, if necessary, containing morphin is a great help during the first week. It is difficult to reduce a fracture of a rib and to hold it reduced. The deformity and loss of function consequent upon the union of a fractured rib in malposition is fortunately not very great (see Fig. 110). How-

Fig. 107.—Fracture of ribs. Emphysema general. Adhesive-plaster swathe about chest. Note closure of right eye and puffiness of face and hands (Monks).

Fig. 108.—Same case as figure 107. Emphysema entirely disappeared. Contrast the two appearances (Monks).

ever, the relief of the patient upon the partial immobilization of the fracture is great. By pressure of the hand the ribs may be steadied and the fragments brought into excellent apposition, and by a pad held in place by a swathe of adhesive plaster this apposition can be maintained. The application of an adhesive-plaster swathe is attended with much comfort, and is easily accomplished. The swathe should be broad enough to cover the chest six inches on either side of the fracture of the rib, and long enough

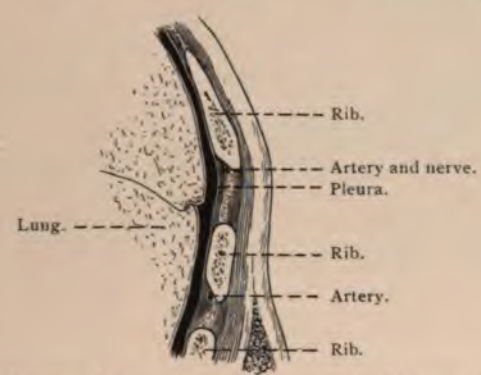

Fig. 109.—Horizontal section of chest-wall. The relation of rib and intercostal vessels and nerve to pleura and lung is shown. Fracture of rib may cause serious injury (frozen section, Professor T. Dwight).

Fig. 110.—Fractured rib, united with displacement (Warren Museum).

to extend three-fourths of the way around the body. It is applied as follows: One end is fixed to the trunk of the patient at the spine, the patient standing erect with the hands upon the top of the head (see Fig. 111). The surgeon, taking the loose end of the swathe and holding it taut, walks around the patient, applying the swathe to the patient's chest while the patient standing turns as if on a pivot toward the surgeon if possible (see Fig. 112). It is important to avoid covering the constantly moving abdomen by the swathe. A swathe made of several long strips of adhesive

Fig. 111.—Fracture of the ribs. Starting the application of the adhesive-plaster swathe to encircle the trunk. Fixation of initial end of the swathe at the spine. Notice that the swathe is held taut as it is applied.

Fig. 112.—Fracture of the ribs. Finishing the application of the adhesive-plaster swathe to the trunk.

plaster, each strip being four inches wide, imbricated in the application, will often prove more comfortable than a single swathe. The comfort attending the wearing of such a swathe speaks much for its efficacy.

Operative Treatment.—If the fracture is comminuted or if there is great displacement that is irreducible by pressure, an incision and elevation of the parts and immobilization by suture are to be considered.

After-treatment.—The upright position will give the most comfort. The swathe should be changed at least once each week. It will require about three weeks for the union to become firm. A cotton swathe may be worn during the third and fourth weeks in place of the adhesive-plaster swathe. At the end of four weeks all swathes may be removed. Massage to the seat of fracture will, after the first week, hasten healing and a restoration of the parts to the normal position. If there have been any pleural or lung complications, great precaution should be exercised in the after-care. The avoidance of exposure to cold and of great bodily exertion for a period of two months or more following recovery from the complication is necessary.

Other injuries, such as strains of the shoulder and back, are likely to appear some days after the acute symptoms of a fracture of the rib have subsided. It is well to examine the patient with a fractured rib for associated injuries. These associated sprains often cause considerable anxiety to the patient for fear that more serious trouble than a broken rib exists. In patients over fifty years old "neuralgic pain" at the seat of fracture will sometimes persist for several weeks after the fracture is firmly united. This may be relieved by applications of moist heat to the affected part and by counterirritation of a more vigorous kind. The use of tincture of iodin and blisters is often a great help. In the aged the shock of the injury is considerable. In feeble persons a pleurisy or pneumonia may prove fatal.

Treatment directed to the removal of the emphysema is ordinarily unnecessary. The emphysema usually disappears in a week or ten days. If the distention of the subcutaneous tissues is extremely painful and increases very rapidly it may be wise to make several antiseptic incisions over them, allowing the air to escape, to relieve the tension of the skin.

CHAPTER V

FRACTURES OF THE STERNUM

It is difficult to palpate the sternum accurately. The episternal notch is felt between the two inner ends of the clavicles. The junction between the first and second portions of the sternum is distinctly felt opposite the second costal cartilage as a ridge. The different sites of fracture are shown in figure 113. The fracture

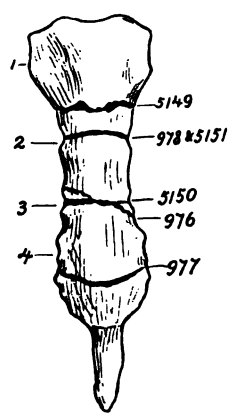

Fig. 113.—Sites of fracture of the sternum (after specimens 5149, 978, 5151, 5150, 976, 977, Warren Museum).

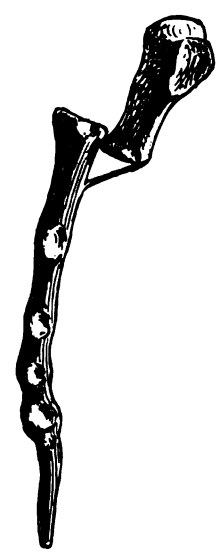

Fig. 114.—Separation of manubrium and gladiolus; displacement of lower portion forward; side view.

that is usually due to direct violence is seated in the upper part of the second portion of the sternum, near the junction of the first and second portions. The upper fragment is displaced backward behind the upper end of the lower fragment (see Fig. 114). The displacement, the abnormal mobility, and possibly crepitus after

each respiratory act or upon coughing, the localized area of pain, all increased by pressure, help to make the diagnosis certain.

The patient stands in a characteristic fashion with body bent forward. It is almost impossible to distinguish a dislocation at the junction of the first and second portions of the sternum from a fracture within the first portion of the sternum. Careful palpation alone and consideration for the age of the patient will enable one to decide. The ossification of the sternum takes place irregularly. At the twenty-fifth year all parts are usually ossified. The lesions sometimes associated with fracture of the sternum—viz., fracture of the ribs and injury to the lungs and heart—are

Fig. 115.—Position in, and method of reduction of, fracture of the sternum. Notice positions of hands of surgeon and assistant.

usually so severe that the patient does not recover from them. If no complicating lesions are present, the outlook for recovery is favorable.

Treatment of Fracture of the Sternum.—Spontaneous reduction has occurred in several instances upon coughing or sneezing. If the patient is placed upon his back with his head extended over the end of the table and the arms are then raised above the head and rotated outward slowly and forcibly, the deformity is sometimes reduced. The body of the patient, meanwhile, is steadied by an assistant. Traction and countertraction are thus made upon the two fragments (see Fig. 115). An adhesive-plaster swathe should be placed about the chest high up, and held firmly in posi-

tion by straps across the shoulders. Union takes place in from three to four weeks. The fracture is not solid for from six to eight weeks. After resting on the back in bed for three weeks the patient may be allowed to be up occasionally with care to avoid violent exertion. For the greatest precaution a Taylor steel back-brace, with apron and head-support, should be used for two months after the patient is up and about. This brace is similar to that used in high dorsal caries of the spine.

Operative Treatment.—Incision and elevation of the depressed fragment have been done successfully, and are to be considered in difficult cases after the shock of the original injury has passed away. Cyanosis and dyspnea may be in part dependent upon the displacement of the sternal fragments. Relief from these symptoms is often immediate upon the correction of deformity.

CHAPTER VI

FRACTURES OF THE PELVIS

THE pelvic bones are generally considered inaccessible (see Fig. 116); but with a systematic anatomical examination, especially if assisted by digital examination by the rectum and the vagina, practically all parts of the pelvic bones may be palpated. Movement of the hip will often determine the integrity of the acetabulum, which is, of course, most difficult to palpate even posteriorly by the rectum. Fractures of the pelvis are occasioned by great violence. Fracture occurs most often in falls from a height, and is due to the sudden pressure upon the pelvis through the thighs and hips (see Fig. 117) or through the spinal column upon the sacrum and sacro-iliac synchondroses. Antero-posterior pressure and lateral compression, as in the car-coupling accident, are common causes of fracture. From a clinical standpoint these fractures fall into two groups—fractures of the individual bones without injury to viscera, and fractures at different points in the pelvic ring usually associated with visceral lesions.

Fractures of the sacrum, the coccyx, the symphysis pubis, and the ischium are extremely rare.

Examination.—The examination should be systematically made in order to cover thoroughly the irregular bones of the pelvis. The ilium of each side should be palpated to detect a fracture of either crest. Then the two ilia should be crowded gently but firmly together in order to determine crepitus due to the presence of fracture elsewhere. Then the pubis and ischium upon the two sides are to be palpated externally as far as is practicable. Finally a careful rectal and vaginal examination should be made of the pelvic bones. The patient should be catheterized to assist in determining the presence of an injury to the urinary tract.

Fracture of the Ilium (see Fig. 118).—This fracture is not unusual. The crest of the ilium is commonly broken. Pain, swell-

ing, crepitus, and abnormal mobility may be present. Localized tenderness at the seat of fracture may be the only sign present. Crepitus, absent at first, may be elicited several days after the

Fig. 116.—Normal pelvis. Note relations of pelvic ring.

Fig. 117.—Fracture of acetabulum; force transmitted through femur (Warren Museum, specimen 1053).

Fig. 118.—Fracture of crest of ilium (Warren Museum, specimen 5938).

injury. There is comparatively little displacement. Union occurs in from three and a half to four weeks. The patient ordinarily requires but restraint in bed. The outlook is for a good

recovery unless there is a visceral lesion. Slight deformity may be noticeable upon full recovery (see Fig. 119).

Fracture of the pubic portion of the ring of the pelvis is the commonest fracture. It is usually associated with other fractures or separations of bony surfaces of the pelvis. Injury to the urethra is not uncommon in this fracture (see Figs. 120, 121).

Treatment.—A snugly fitting swathe encircling the pelvis should be applied to assist in immobilizing the fracture. If the fracture is of the ilium alone, the swathe should be applied loosely enough to avoid displacing the fragment of the crest inward, thus

A. B.

Fig. 119.—Case: Fracture of the crest of the right ilium: A, Deformity due to inward displacement of fractured bone; B, Posterior lateral view (Porter).

causing permanent deformity (see Fig. 119). The patient should, in all cases, except simple fractures of the crest of the ilium, be placed upon a properly fitting Bradford frame. Upon this frame, and in no other way, can the patient be comfortably nursed. The bed-pan can be adjusted with ease and without disturbing the fracture. The bed can be most readily changed and the patient kept clean and comfortable. If it is probable that movements of the hip-joints cause motion at the seat of the fracture, the thighs should be fixed so as to immobilize these joints. The long outside wooden splint extending from the axilla to below the heel and attached at its foot end to a slat at right angles to the long

upright—a T-splint—is the simplest means of securing this immobilization. If the patient is on a Bradford frame, sufficient immobilization is easily accomplished by encircling the thighs separately or together and the frame with a towel swathe. Extension of the limbs by weight and pulley may be needed in

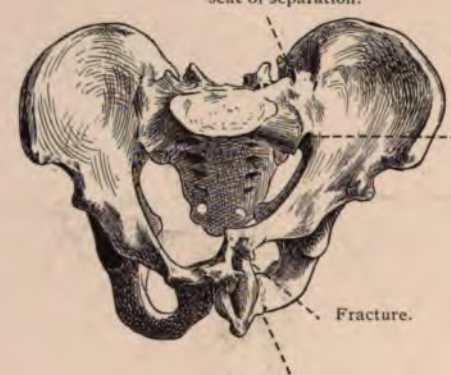

Fig. 120.—Fracture of rami of pubes; fracture and separation at sacro-iliac synchondrosis; much displacement; bony union (Warren Museum).

Fig. 121.—Fractured pelvis: on the right, fracture across pubes and ischium; on the left, fracture involving acetabulum and sacrosciatic notch (Warren Museum, specimen 3857).

addition in certain cases to secure immobilization of the fracture. Wiring or suture of the fractured bones may be entertained and practised. Wiring is indicated if comminution or displacement of fragments is great.

Visceral Lesions.—Associated with fractures of the pelvis there

may be lesions of important viscera. These visceral lesions render fractures of the pelvis of the very greatest seriousness. The trauma causing the fracture may at the same time occasion a rupture of the kidney. The bladder, urethra, or bowel may also be ruptured. The shock associated with a fracture of the pelvis is great. If there is a visceral lesion, the primary and secondary shock will be very great.

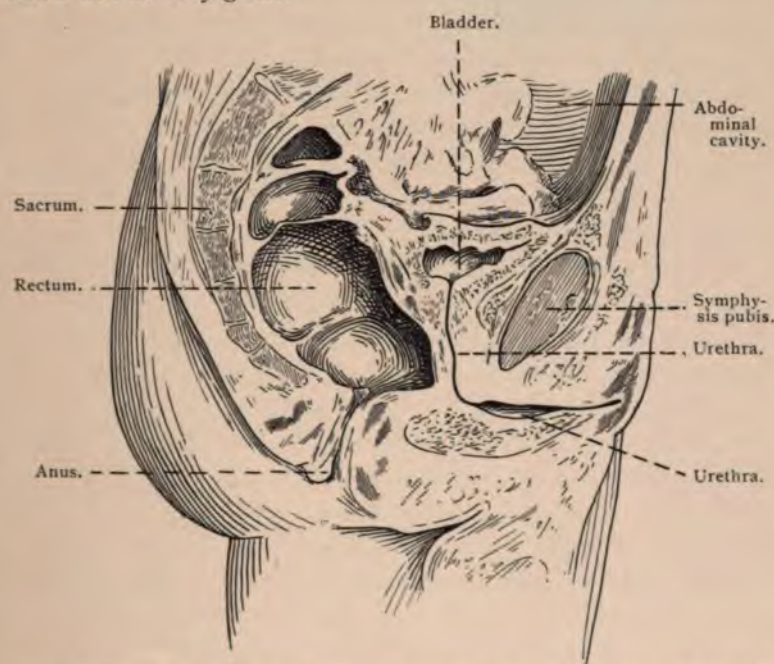

Fig. 122.—Median section of male pelvis. Notice close relation of bladder and urethra to the symphysis pubis. Fracture of pubic bone may injure bladder or urethra (frozen section by Professor Thos. Dwight).

Rupture of the Urethra.—This is sometimes associated with fracture of the pelvis (see Fig. 122). It may be due to the original trauma, as a fall or blow on the perineum, or it may be caused by bony fragments lacerating the urethra, or by a simple separation of the symphysis pubis. Pain at the seat of the lesion, pain upon pressure in the perineum, retention of urine, urethral hemorrhage, swelling in the perineum, usually exist. Under these circumstances perineal section is indicated in order to drain the wounded area and the bladder. If a catheter can be passed to the bladder

and the local swelling does not increase, permanent or interrupted catheterization is indicated. The patient should, however, be watched carefully for the signs of extravasation of urine. If at any time the catheter can not be passed, operation should be done at once, as in the first instance.

If the urethral rupture is caused from above, the inferior surface of the canal may be intact. If so, the passage of the catheter (if difficult) may be facilitated by depressing the instrument slightly, hugging the inferior wall of the urethra.

Rupture of the Urinary Bladder.—This may be either extra- or intraperitoneal. When the bladder is empty, it is low down in the pelvis and can be injured only by a fracture of the pelvis. The rupture of the bladder due to fracture of the pelvis is usually extraperitoneal and it is situated on its anterior surface.

On account of the fracture the patient can not walk. Rupture of the bladder itself might occasion inability to walk, at least any long distance. There is great hypogastric pain, frequent desire to micturate and inability to pass urine. A few drops of bloody fluid escape from the meatus. Dullness may be present in the lower abdomen and loins. Soon after the accident, if not immediately, there is great prostration. Evidences of shock are seen in the pallor of the face, the anxious expression, the feeble pulse, the cold, clammy skin, and feeble voice. The abdomen becomes distended, the temperature rises, and delirium, coma, and death follow with certainty unless operative interference has relieved the condition at a very early hour after the accident. The patient dies from shock, hemorrhage, or septic peritonitis.

If the patient is seen soon after the accident, before untoward symptoms have appeared, and has not micturated for some little time, he should be catheterized. An empty bladder will be found or a small amount of bloody fluid will be withdrawn, which rather confirms the other evidences of ruptured bladder. If there is doubt as to the rupture of the bladder, the symptoms should be watched. The symptoms of rupture may be masked or delayed by the associated lesions. The urine may be tinged with blood because of a contusion of the bladder. The catheter may be passed through the bladder-wall, and be felt to enter the abdominal cavity, evacuating bloody fluid. All fluid

having been removed from the bladder, if a measured amount of sterile water is injected into it, and all that was injected does not return, presumption of rupture of the bladder is very great. Under such circumstances the dull area in the groins and lower abdomen of extraperitoneal rupture will be increased.

Exploratory laparotomy should be done, and if the extravasation proves to be extraperitoneal, drainage of this area is demanded. Temporary drainage of the bladder, either urethral or through perineal section, will be needed to permit healing of the bladder wound. The bladder wound is usually inaccessible to suture in these cases.

Prognosis.—A guarded prognosis should always be given in any case of fracture of the pelvis. Fractures of the iliac crest ordinarily recover in a few weeks. In fractures complicated by rupture of the bladder or bowel the prognosis is extremely grave.

CHAPTER VII

FRACTURES OF THE CLAVICLE

Anatomy.—The clavicle is subcutaneous throughout its whole length (see Fig. 124). The acromioclavicular joint is at its outer end. The sternoclavicular joint is at its inner end. The clavicle

Fig. 123.—Normal left clavicle viewed from above.

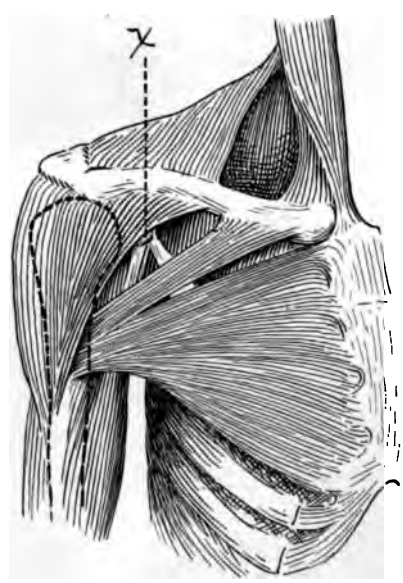

Fig. 124.—Muscles arising from and attached to the clavicle, showing the muscular plane in which the clavicle lies. X points to the coracoid process.

lies in a muscular plane made up of the trapezius and sternocleidomastoid muscles above, and the deltoid, pectoralis major, and subclavius muscles below (see Fig. 124). It is important to

recognize the situation and the direction of the acromioclavicular joint in order to discriminate between a fracture of the outer end of the clavicle and one of the acromial process. It is likewise important intelligently to palpate the normal shoulder, to determine that the acromial process does not form the outer limit of the shoulder, but that it is formed by the greater tuberosity of the humerus.

Symptoms.—The common seat of fracture is in the middle third of the bone (see Figs. 125–128 inclusive). The shoulder, having lost the support of the clavicle, falls forward and drops inward, consequently the outer fragment that moves with the

Fig. 125.—Fracture at the inner and middle thirds of right clavicle from above (Warren Museum, specimen 1214).

Fig. 126.—Fracture toward middle of clavicle, a little to the inside (common site). Right clavicle from above (Warren Museum, specimen 987).

Fig. 127.—Fracture at the outer and middle thirds of left clavicle from above (Warren Museum, specimen 987).

Fig. 128.—Fracture at the outer end of clavicle. Left clavicle from above (Warren Museum, specimen 7900).

shoulder drops below the inner fragment and overlaps it in front. The inner fragment, having attached to it the sternocleidomastoid muscle and being comparatively free to move, is drawn slightly upward. The attitude of the patient is characteristic (see Figs. 129, 130): he stands with the head inclined to the injured side, thus relaxing the pull of the sternocleidomastoid muscle upon the inner fragment. The shoulder upon the side fractured is depressed; the elbow and forearm upon this same side are supported by the well hand. This is the attitude of greatest comfort. The shoulder—*i. e.*, the space between the base of the neck and the greater tuberosity of the humerus—is shortened upon the injured side (see Fig. 141). If the fracture lies within the limit of the

coracoclavicular ligament or outside of it, there will be no appreciable displacement (see Fig. 131). The diagnosis under these circumstances will be difficult. Localized pain and the disability of the arm will suggest the lesion present.

Fracture of the Clavicle in Childhood.—More than one-third of all fractures of the clavicle occur in children under five years of age. A trivial injury is the usual cause of the fracture. A little child may fall from a low chair or out of bed and fracture the bone. The fracture is almost always incomplete or greenstick.

Fig. 129.—Case: Comminuted fracture of the left clavicle. Attitude characteristic; deformity visible; wired (Mixter).

The child cries upon moving the arm. Lifting the child by placing the hands in the armpits causes pain. The arm of the injured side may be used as naturally as the other or there may be some disability, perhaps simply a disinclination to use the arm. If the fracture is greenstick, a tender swelling appears at the seat of the fracture. If the fracture is complete, an unevenness will be felt at the seat of fracture according to the amount of displacement. The displacement is usually slight in childhood. The characteristic attitude seen in adults (see Figs. 129, 130) is much less marked in children, and if the fracture is greenstick, there is

no tilting of the head and depression of the shoulder. If the child, as so often occurs, persistently holds the head so that a careful examination is impossible, then it is best to place the child on its back, and while its legs and arms are held firmly, the head and shoulder may be gently and gradually separated. The examination can then be completed.

Fig. 130.—Attitude characteristic of a recent fracture of the right clavicle.

Fig. 131.—Diagram of the ligaments attached to and near the clavicle on its under surface: *a*, Rhomboid; *b*, conoid; *c*, trapezoid; *d*, coraco-acromial.

Treatment in Adults.—The displacement should be corrected and the corrected position maintained (see Figs. 132, 133). The indications are to carry the shoulder, and with it the outer fragment, upward, outward, and backward.

The Recumbent Treatment.—The displacement is most satisfactorily corrected by the patient lying recumbent upon a firm

Fig. 132.—Fracture of the clavicle. Method of correction of falling inward and downward of shoulder, in overriding of fragments previous to the application of the modified Sayre dressing.

Fig. 133.—Fracture of the clavicle. Same as figure 132. Posterior view, showing extreme backward position of shoulders.

Fig. 134.—Fracture of the left clavicle. Modified Sayre dressing. Towel circular of upper arm held by adhesive plaster. Adhesive-plaster strap ready.

Fig. 135.—Fracture of the left clavicle. First adhesive-plaster strap applied. Shoulder carried backward. Fixed point established above middle of humerus.

Fig. 136.—Fracture of the left clavicle. First adhesive-plaster strap applied. Second adhesive-plaster strap being applied. Hole in plaster for olecranon visible. Note pad for wrist and folded towel protecting skin of arm and chest.

Fig. 137.—Fracture of the left clavicle. First and second adhesive-plaster straps applied. Pad in left hand. Shoulder pulled backward and elevated.

mattress. The weight of the shoulder in this position does not impede reduction, as in the upright position, but assists it. A firm and small pillow should be placed between the shoulders. The shoulders fall backward of their own weight over the pillow carrying the outer fragment backward at the same time. Padding of the fragments of the clavicle, the application of pressure to the elbow, may be more satisfactorily accomplished in the recumbent than in the upright position. Union ordinarily occurs within three weeks. At the time of union or shortly after the patient may be allowed up with a simple retentive dressing, a sling, and a swathe. The bed treatment is hard to enforce because the fracture is the cause of so little real permanent disability. If there is much displacement and deformity can not be corrected and held properly, the bed treatment is indicated. In the simultaneous fracture of both clavicles the recumbent bed treatment is the best (see Operative Treatment of Fracture of the Clavicle).

The Modified Sayre Dressing.—The shoulder and arm are unwieldy in adults. It is, therefore, necessary in treating a fracture of the clavicle by an ambulatory method to secure a very firm hold upon the shoulder in order to maintain the clavicular fragments in a good position.

The modified Sayre adhesive-plaster dressing is the best. It is applied as follows: Provide three strips of adhesive plaster, four inches wide, and long enough to extend once and a half around the body. The skin surfaces that are to come in contact—namely, the axilla and chest and forearm—are separated by compress cloth and powder. A dressing towel, folded like a cravat, is snugly pinned high up about the upper arm (see Fig. 134). This towel may be held neatly by a strip of adhesive plaster. One end of the first adhesive strap is fastened loosely about the towel-protected arm with a safety-pin. While an assistant holds the shoulder well back the arm is carried backward, and held by the fastening of the first adhesive strap about the body (see Fig. 135). This affords a fixed point at the middle of the upper arm. The second strap, with a hole in it to receive the point of the elbow, is started upon the posterior surface of the injured shoulder (see Fig. 136) and carried under the elbow of the injured side and over the well shoulder (see Fig. 137). The forearm is flexed, and rests upon

the chest. In applying this second strap the shoulder is raised and the elbow is carried forward, thus forcing the shoulder slightly upward and backward of the fixed point used as a fulcrum (see Fig. 138). A third strap may be placed around the trunk and arm to steady all in good position. Over this dressing may be put a Velpeau bandage for the comfort of the support which it affords (see Fig. 139). The adhesive plaster may be covered with

Fig. 138.—Fracture of the right clavicle. Modified Sayre dressing. Posterior view. Shoulder elevated and pulled backward. Folded towel seen in axilla for protection to skin.

Fig. 139.—Fracture of the clavicle. Method of application of a Velpeau bandage. Note the order and direction of the turns 1, 2, 3, 4, and 5. Note position of the forearm and arm of the uninjured side.

bits of gauze bandage, in part to protect the skin from undue chafing, sufficient plaster surface remaining uncovered to prevent the straps from slipping. Occasionally, pads (see Fig. 140) upon the clavicle may be used to correct the deformity, but the bone is so subcutaneous that the skin can not bear great pressure without damage. If pads are used, they must receive frequent inspection.

Treatment in Children.—The skin of the child must be pro-

tected by powder and careful drying before the arm is done up. If it is a greenstick fracture and there is slight deformity, this deformity should be corrected by pressure with the thumbs. An anesthetic should be used. After the deformity is corrected and in cases without deformity it is necessary simply to restrain the movements of the arm for two weeks. This is best accomplished by a cotton swathe about the body and upper arm, held by straps

Fig. 140.—Fracture of the clavicle and subluxation of the acromioclavicular joint. Notice elevation of shoulder by pressure on the flexed elbow and counterpressure on the clavicle by a bandage and a pad (×) placed internal to the acromioclavicular joint.

over the shoulders and by a cravat sling. In warm weather and also in cool weather, for that matter, the arm is to be inspected frequently, as often as every third day, when all the dressings are removed, the parts bathed with soap and warm water, powdered, and the simple retentive dressing reapplied. With this care only can chafing be avoided. If it is a complete fracture, the modified Sayre adhesive-plaster dressing should be used as in adults. The

skin is to be carefully protected, and the dressing m
watched. It requires but forty-eight hours for gr
occur with the resulting discomfort and the slow l
often results. If union is firm after two weeks or tw and
a half, the plaster dressing should be removed and the shoulder put up in a simple retentive swathe and sling, at first, inside the clothes; after three weeks, outside the clothes. In very active children the sling should not be removed until four weeks have elapsed. Massage should be given to the forearm, elbow, and

Fig. 141.—Fracture of the right clavicle. Shortening of the shoulder.

shoulder after the first week, together with passive motion of the elbow. In both children and adults the adhesive-plaster dressing should be reapplied at least once every ten or twelve days. If the dressing chafes or slips, it may need more frequent renewal.

Prognosis.—Useful arms and shoulders usually result after fracture of the clavicle. Almost all complete fractures of the clavicle with displacement of fragments, after repair has taken place, show unmistakable evidences of deformity at the seat of fracture, of shortening of the width of the shoulders, and in many

instances in children of a slight lateral deformity of the spinal column (see Fig. 141). Fractures within the coracoclavicular ligament having little displacement of fragments show no resulting deformity. Very great deformity does not preclude a useful arm. An ununited fracture of the clavicle is unusual; it may exist and cause no especial inconvenience; it may be unknown to the patient. An ununited fracture of the clavicle with considerable callus-formation may simulate malignant disease of the bone. Laboring men are rarely kept from their work more than two months. Fractures of the clavicle in young children, if carefully treated, should unite with practically no deformity or disability. Greenstick or incomplete fractures may show a general bowing of the whole bone, which it has been impossible to correct.

Operative Treatment.—In recent fractures: If there is great displacement which can not be held reduced, if sharp fragments threaten vessels or nerves, if there is pressure upon either nerves or blood-vessels, if the fracture is a comminuted one, and if the bone is fractured in two or more places (multiple fractures), it is wise to consider operative measures. The fragments can be exposed, replaced, and held in position by suturing. Good results follow this treatment. After operation for fracture of the clavicle a simple retentive dressing of a swathe and cravat sling will be needed. It should be worn for at least three weeks.

In Ununited Fractures.—If the cause of delayed union of the fracture is a misplaced bony fragment, an interposed strip of fascia or periosteum, or an interposed subclavius muscle, operative interference may be undertaken with a reasonable expectation of securing a good result. If, on the other hand, nonunion has existed for a long period (a year or more), it is highly probable that the ends of the fragments will be so attenuated that refreshing these ends for suture would shorten the fragments to such an extent that suture would be impracticable.

CHAPTER VIII

FRACTURES OF THE SCAPULA

THE spine and acromial process, the coracoid process, and the vertebral and axillary borders of the scapula can be palpated with comparative accuracy. Fracture of the scapula is of rather unusual occurrence, and always follows great violence (see Figs. 142, 143, 144).

Fracture of the body of the scapula is transverse between the axillary and vertebral borders or comminuted in various directions (see Figs. 145, 146).

Crepitus, abnormal mobility, local swelling, and tenderness are present. Pain is felt upon attempting to abduct the arm. It may be impossible to raise the arm to the head.

Fracture of the Acromial Process of the Scapula.—The epiphysis of the acromion unites with the scapula about the twentieth year. If there is a fracture present, and not a separation of the epiphysis, which sometimes occurs, the line of fracture is ordinarily outside the acromioclavicular joint. A fracture may occur through the acromion nearer to the spine of the scapula.

Localized pain, swelling, and tenderness, and a flattening of the shoulder are present. Crepitus may at times be felt. If the fracture is inside the acromioclavicular joint, the flattening of the shoulder will be considerable. The head of the humerus is felt in the glenoid cavity, thus ruling out a dislocation.

Fracture of the neck of the scapula is most unusual. If present, it may be mistaken for a dislocation of the humeral head.

The acromial process is prominent. The upper arm is lengthened. On lifting the arm forcibly upward with the elbow flexed, the deformity is corrected, and crepitus is detected. The deformity recurs if this upward pressure is removed. The reappearance of the deformity and the crepitus serve to distinguish this injury from a dislocated shoulder. In a thin person palpation of the edges of the glenoid cavity itself will prove rather satisfactory;

Fig. 142.—Normal scapula. Axillary view.

Fig. 143.—Normal scapula. Ventral view.

Fig. 144.—Normal scapula. Dorsal view.

the crepitus and abnormal mobility can thus be more accurately located.

Treatment in General.—Immobilization of the whole upper extremity, except the forearm and hand, is necessary. Localized pressure may assist in retaining fragments in place.

If there is fracture of the body of the scapula, the forearm should be flexed to a right angle and held in a sling. The skin-surfaces coming in contact should be protected by powder and compress cloth. A swathe of cotton cloth should be fastened

Fig. 145.—Fracture of the body of the scapula. Bony union with moderate displacement (Warren Museum, specimen 8111).

Fig. 146.—Multiple fractures of scapula. Railroad accident. Man, forty-three years of age. Lived one day (Warren Museum, specimen 6028).

about the upper arm and trunk. If the cloth swathe is not sufficient to hold the scapula steady, a swathe of adhesive plaster should be used, broad enough to extend from the acromion to the elbow.

Fracture of the Acromial Process: The skin-surfaces must first be protected from chafing. The forearm being flexed, pressure upward should be made upon the elbow, so as to lift the arm and relax the pull on the small acromial fragment. At the same time counterpressure is made upon the inner fragment and incidentally

upon the inner shoulder (see Fig. 140). This pressure and counterpressure will hold the part reduced. The bandage must be inspected frequently each day, in order to detect and to relieve too great pressure upon the elbow and bony parts of the shoulder.

Union will take place in from three to four weeks. It is extremely difficult to maintain the reduction of the fragment of the acromion by any apparatus. The one previously suggested meets the indications better than any other. Massage will materially assist in hastening the absorption of blood and will relieve pain. No very great functional disability results if union occurs with bony displacement.

CHAPTER IX

FRACTURES OF THE HUMERUS

FRACTURES OF THE UPPER END OF THE HUMERUS

Anatomy.—The clavicle may be felt throughout its entire length from sternum to acromion. The acromial process of the scapula articulates with the outer end of the clavicle. This acromioclavicular joint has an anteroposterior direction, and if the line of this joint is continued anteriorly, it will pass down the

Fig. 147.—View of bones of the shoulder from above. Notice acromioclavicular joint, its relations to bicipital groove and coracoid process. The point of the shoulder is made by the great tuberosity of the humerus.

front of the upper arm (see Fig. 147). The outer edge of the acromion is continuous downward and backward with the spine of the scapula. The great tuberosity of the humerus projects beyond the acromial process, and is covered by the deltoid muscle. The point of the shoulder itself is made by the humerus and not by the acromion (see Figs. 147, 149).

Examination of the Shoulder.—The uninjured shoulder should be examined before the injured shoulder. In injuries doubtful in character, associated with much swelling of the shoulder, and which are painful upon gentle manipulation, the examination should be made with the aid of an anesthetic. Great

Fig. 148.—Transverse section of trunk, showing obliquity of shoulder-joint in relation to chest, and the inclination of the glenoid cavity.

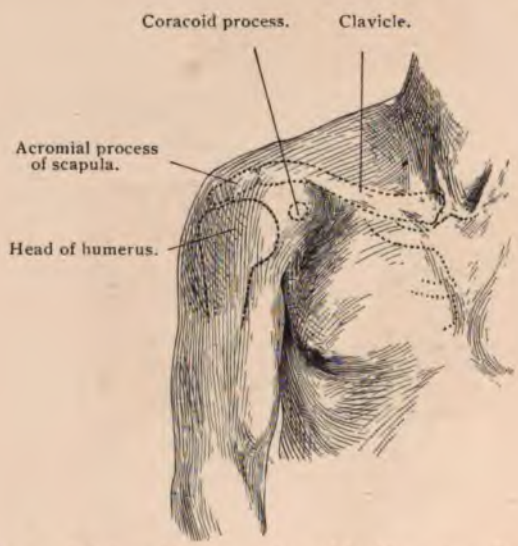

Fig. 149.—Relations of bones to surfaces of shoulder region. Great tuberosity of humerus projects beyond the acromial process of scapula. Relations of coracoid to clavicle and head of humerus (compare with Fig. 155).

swelling suggests great trauma; absence of all swelling appreciable to the eye suggests slight trauma.

For the examination the patient should be seated upon a rather high stool, so that the shoulder comes to an easy level for manipulation. The shoulder should be grasped, so that the head of the humerus can be felt between the fingers and thumb of one hand

Fig. 150.—Examination of shoulder. Method of palpating head of humerus with thumb and fingers. Elbow grasped by other hand.

Fig. 151.—Examination of shoulder. Movements of the shoulder. Normal maximum abduction. Notice method of grasping head of humerus.

pressed under the spinous and acromial processes. The other hand should grasp the flexed elbow firmly, in order to make the necessary movements at the shoulder-joint (see Fig. 150). If the head of the humerus is intact and in its normal place, it will be felt to move with the shaft of the humerus, as upon the uninjured side. All the normal movements of the shoulder-joint should be made passively and actively—namely, the movements

Fig. 152.—Examination of shoulder. Maximum adduction. The bend of the elbow, when the forearm is flexed to a right angle, comes to the median line of trunk.

of abduction, adduction, forward and backward swing, and rotation (see Figs. 151, 152, 153). Those movements which are painful and limited should be carefully noted. Unless the normal individual standard of movement is known, as determined by examination of the well shoulder, there can be no definite interpretation of the conditions existing in the injured shoulder. The condition of the circulation and the presence of paresis or paralysis in the limb should be observed. The shaft of the humerus should

be measured: the measurement best taken is the distance between the edge of the acromial process and the external condyle of the humerus. The patient should be seated with the elbow at the side if possible, and flexed to a right angle (see Fig. 154). The forearm should rest on the thigh of the same side. The direction of the long axis of the humerus should be carefully noted.

The coracoid process of the scapula in all injuries to the shoulder should be palpated, for a knowledge of its position assists in locat-

Fig. 153.—Examination of shoulder. Maximum outward rotation. Notice position of examining hands.

ing the head of the humerus intelligently (see Fig. 155). The examiner should stand in front of the patient, and place the left hand upon the right shoulder and the right hand upon the left shoulder, the hands being open. The thumb should fall below the clavicle a full finger's-breadth, when the end of the thumb will touch the coracoid. It is generally possible to feel the coracoid even in very stout people and when much swelling is present.

Diagnosis.—It is sometimes impossible to determine the exact

lesion following an injury to the shoulder. Anesthesia and the Röntgen ray are invaluable aids to diagnosis. It is of the first importance to know whether the head of the humerus is in the glenoid cavity or whether it is dislocated; this is determined by palpation and by noting the direction of the long axis of the humerus. It is next in importance to learn whether there is a fracture of the humerus. If the humeral head rotates with the

Fig. 154.—Method of measuring the length of the shaft of the humerus from the acromial process to the external condyle.

Fig. 155.—Examination of shoulder. Palpating the coracoid processes. Note the position of the hands and thumbs.

shaft, there is probably no fracture unless there is one with impaction. If the humeral head does not rotate with the shaft, then there is a fracture. If crepitus is present, the diagnosis is confirmed. After injury to the shoulder the following fracture lesions may be present, and are to be considered:

Fracture of the anatomical neck of the humerus.
Separation of the upper humeral epiphysis.
Fracture of the surgical neck of the humerus.

In any one of these instances a dislocation of the humeral head from the glenoid cavity may exist and complicate the case.

Simple Dislocation of the Humeral Head, Subcoracoid (see Fig. 156).—The attitude is characteristic: the affected arm is held flexed, with the elbow away from the side and the arm rotated inward. The anterior axillary fold is lowered upon the injured side. The long axis of the shaft of the humerus is inclined inward.

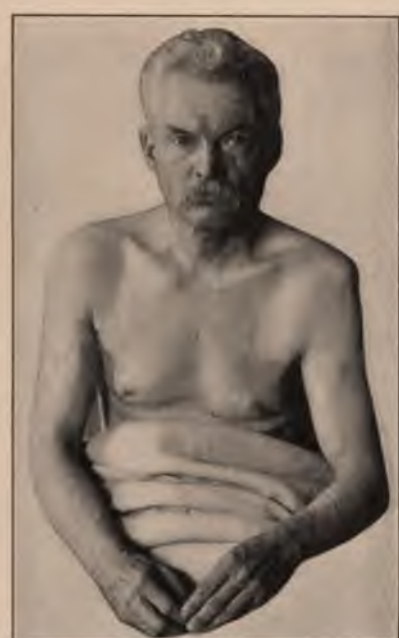

Fig. 156.—Dislocation of the left shoulder. Note the flat deltoid. Prominence under coracoid. Direction of the long axis of the humeral shaft. Lengthening of upper arm. Left nipple lowered. Anterior axillary fold lowered.

The roundness of the shoulder is flattened. The acromial process is prominent. The head of the humerus is out of the glenoid cavity, and most often lies under the coracoid process. The elbow can not be brought in front toward the median line, nor can the hand of the injured arm be placed upon the opposite shoulder. Active and passive movements at the shoulder-joint are greatly restricted. Measuring from the acromial process to the external epicondyle of the humerus, the upper arm, in a subcoracoid dis-

location, is lengthened. A soft crepitation may be detected in manipulating the shoulder, which simulates bony crepitus.

Fracture of the Anatomical Neck (see Figs. 157, 158, 159, 160, 161, 162).—This is rare. It occurs in elderly people. Swelling of the shoulder is evident. Anesthesia is necessary for a careful examination with deep palpation. There is thickening of the neck of the bone. Crepitus will be felt unless the fracture is impacted. There will be pain upon moving the shoulder. Abnor-

Fig. 157.—Fracture of the anatomical neck of the left humerus. Atrophy of the shoulder muscles. Deformity at the seat of the fracture, seen a little below acromial process upon the anterior surface of the shoulder just inside the white line.

mal mobility may be felt high up the shaft close to the head of the bone. This fracture lies wholly within the capsule of the joint.

Separation of the Upper Epiphysis (see Figs. 163, 164, 165, 166, 167).—The separation of the upper humeral epiphysis will not necessarily open the joint cavity, for the capsular ligament is firmly attached to the epiphysis and the synovial membrane is but loosely attached to the diaphysis. The line of the separation of the upper epiphysis of the humerus begins on the inner side of the head of the bone and runs across almost horizontally, rising toward the center of the shaft, and ends in the

outer side of the bone, so that the epiphysis includes the tuberosities.

This happens to young people, but never after the twentieth year. The most frequent period is between the ages of nine and seventeen years. Ordinarily, the upper end of the lower fragment projects forward and inward, producing a characteristic deformity. The head of the bone is in the glenoid fossa, but rotated by the muscles attached to it so that its articular surface looks downward.

Fig. 158.—Normal right shoulder. Compare with figure 159. Same case as figure 157.

Fig. 159.—Fracture of the anatomical neck of the left humerus. Sharp deformity anteriorly characteristic. Compare with figures 157 and 158.

It does not rotate with the shaft. The crepitus is of a softer quality than in cases of fracture—*i. e.*, cartilaginous. Localized pain and swelling are present. A puckering of the skin, caused by the hooking of the lower fragment into the skin is characteristic (see Fig. 164). Palpation reveals the upper end of the shaft. A high lesion near the joint in a young patient, showing displacement forward and inward of the shaft, is very suggestive of epiphyseal separation.

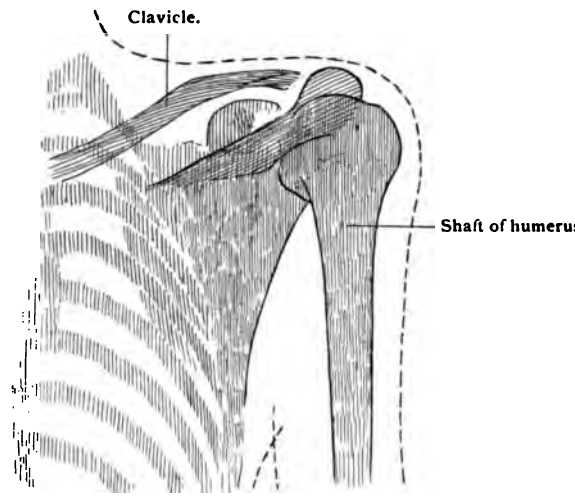

Fig. 160.—Fracture of high surgical or anatomical neck of humerus. Recovery with useful arm. Slight limitation of movements only (X-ray tracing).

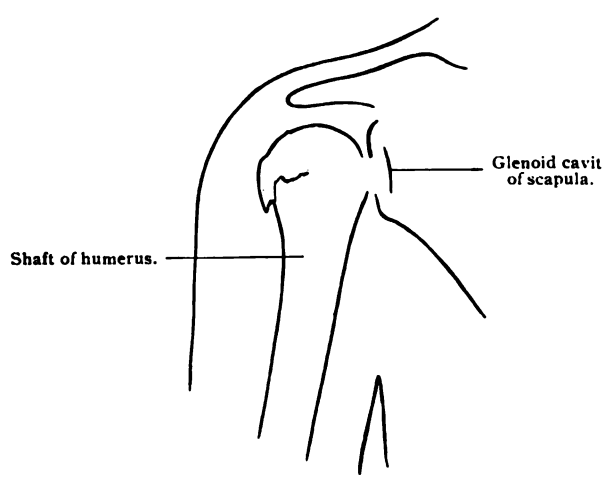

Fig. 161.—Fracture of the anatomical neck of the humerus (X-ray tracing).

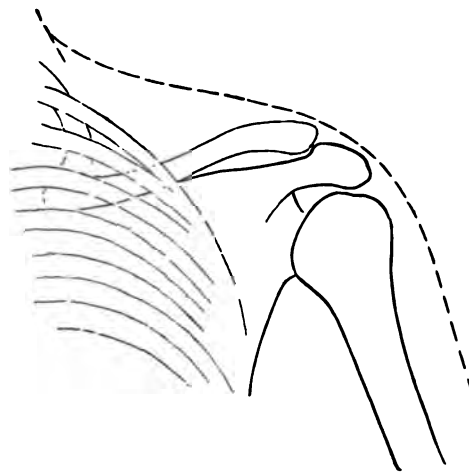

Fig. 162.—Man, sixty years of age. Fracture of anatomical neck of humerus, six months previous to this (X-ray tracing). Backward swing and abduction slightly limited, otherwise normal movements. Useful arm.

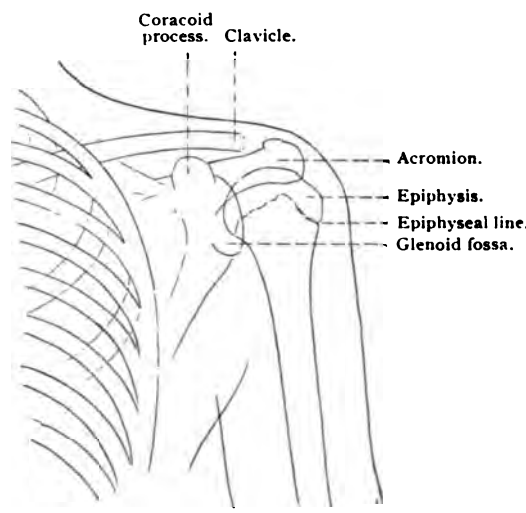

Fig. 163.—Normal shoulder, showing epiphysis of upper end of humerus (X-ray tracing).

Fig. 164.—Separation of upper epiphysis of the humerus immediately after the accident. Note, especially, position of upper arm and position of head, and deep crease in skin made by the catching of the skin in the upper end of the lower fragment. Same as figure 165.

Fig. 165.—Separation of the upper epiphysis of the humerus (left). Notice shortening of the upper arm. Unusual fullness internal and above normal position for head. Same as figure 166.

Fig. 166.—Separation of the upper epiphysis of the left humerus. Notice prominence below normal place for humeral head. This prominence is made by the upper end of lower fragment. Same case as figure 164.

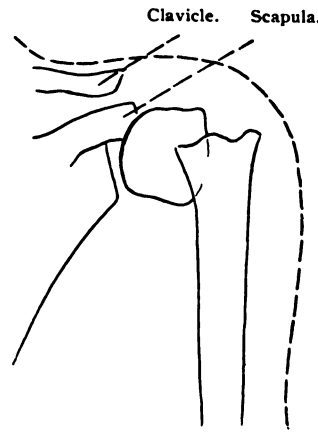

Fig. 167.—Fracture of high surgical neck, or separation of epiphysis with rotation of head (X-ray tracing of figure 164).

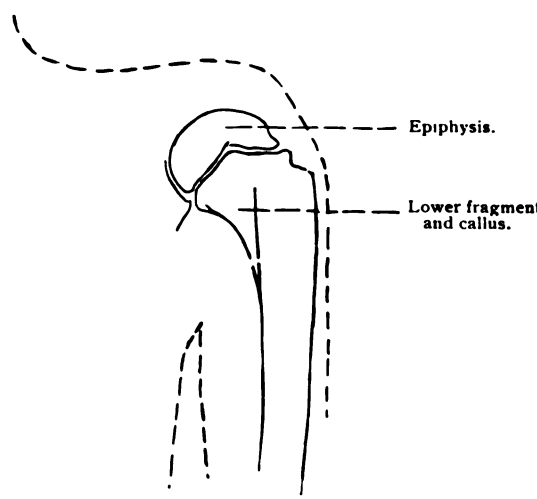

Fig. 168.—Old fracture of surgical neck high up, simulating true epiphyseal separation (X-ray tracing).

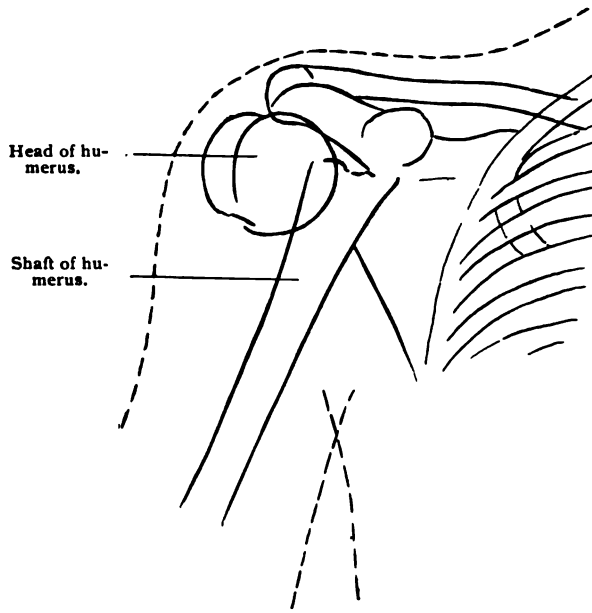

Fig. 169.—High fracture of surgical neck, simulating separation of the upper epiphysis of the humerus. Displacement of lower fragment inward. Old fracture unreduced (X-ray tracing).

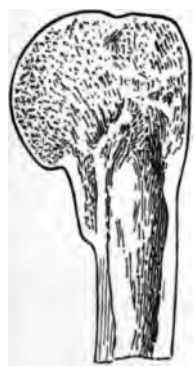

Fig. 170.—Impacted fracture of the surgical neck and tuberosities in section (Warren Museum, specimen 8539).

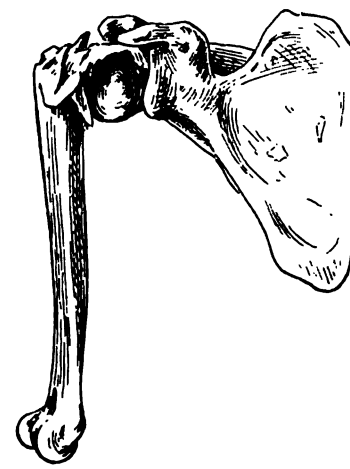

Fig. 171.—Fracture of the surgical neck of the humerus. Much displacement. Fibrous union only (Warren Museum, specimen 991).

Fig. 172.—Diagram showing usual displacement in fracture of the surgical neck of the humerus.

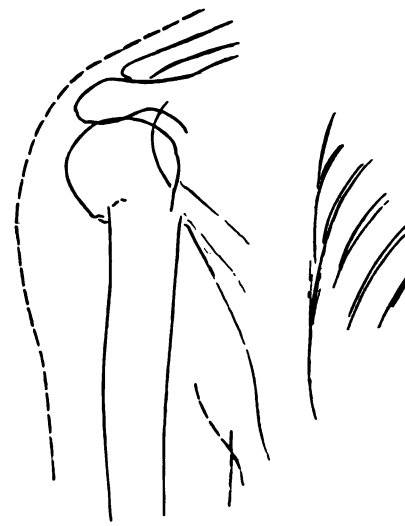

Fig. 173.—Fracture of the surgical neck (X-ray tracing).

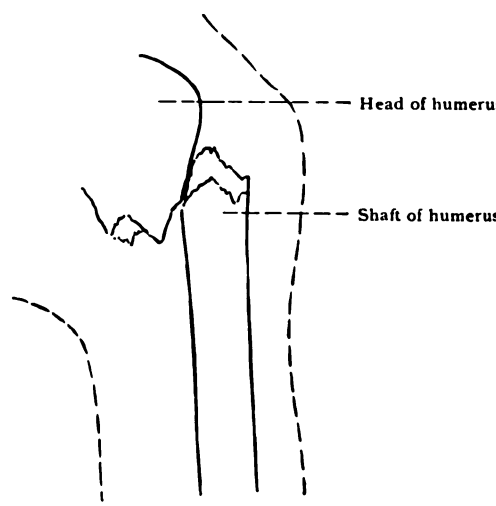

Fig. 174.—Fracture of the surgical neck of the humerus. Displacement of the shaft outward. Impossible to reduce without open incision (X-ray tracing) (Eliot).

Fracture of the Surgical Neck (see Figs. 170, 171, 172, 173, 174, 175).—Any fracture below the epiphyseal line of the upper end of the humerus and well within the upper fourth of the shaft of the bone may, for all practical purposes, be regarded as a fracture of the surgical neck of the humerus. Fracture of the surgical neck is the common fracture of the upper end of the humerus. Fracture of the anatomical neck is most often seen in the aged. Separation of the upper humeral epiphysis occurs in youth.

The head of the bone is found in the glenoid cavity. Passive movements are associated with pain, and elicit crepitus and abnor-

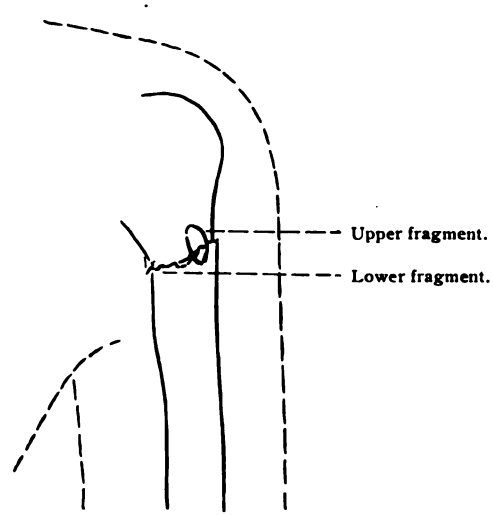

Fig. 175.—Fracture of surgical neck of the humerus. Same as figure 174 after reduction by open incision and wiring with silver wire. Recovery as to motion complete (X-ray tracing) (Eliot).

mal mobility at the seat of fracture, provided, of course, the fracture is not impacted. The arm is slightly shortened. The arm is held flexed, with the elbow at the side.

If after an injury to the shoulder no positive evidences of fracture or dislocation exist, and there is tenderness and localized swelling about the joint, and motion is painful, it is probable that simply a contusion exists.

Treatment.—*Fracture of the Anatomical and the Surgical Neck and Separation of the Upper Humeral Epiphysis.*—The importance of these lesions demands, as has been said, an examination with

the aid of an anesthetic. It is even much more important, however, that the first retentive dressing be applied with the assistance of an anesthetic. Traction, countertraction, and manipulation will secure coaptation of the fragments. To hold these fragments securely is difficult. To hold a separation of the upper epiphysis in position may be impossible without operative assistance. To hold any one of these fractures without operative interference may be impossible.

The following is the best and simplest method of treatment: The upper arm, shoulder, and trunk should be thoroughly powdered. The hand, forearm, and elbow should be bandaged evenly, smoothly, and firmly with a bandage of flannel—not cut on the bias. A V-shaped pad (with the apex of the V in the axilla) constructed of sheet wadding with cardboard outside and covered with cotton cloth, should be placed in the axilla of the injured side (see Fig. 176). This pad is firm, and fitted to the trunk in order to support the inner side of the upper arm (see Fig. 177). If thought wise, a thin coaptation splint may be placed between this pad and the inner side of the upper arm for more direct support. The forearm is held flexed. The shoulder is now well padded with one layer of sheet wadding. A plaster-of-Paris shoulder-cap is applied so as to cover the whole shoulder, the anterior and posterior aspects of the chest, and the outer side of the upper arm down to the external condyle of the humerus (see Fig. 178). This shoulder-cap is made of washed crinoline, six layers thick, into which has been rubbed plaster-of-Paris cream. Its exact shape and extent are seen in the plates. A gauze bandage encircling the trunk, arms, and shoulders should be used, in order to hold the upper arm at the side and closely applied to the coaptation splint and the axillary pad, and in order to secure the shoulder-pad firmly in place. Often better than the plain gauze bandage is a roller bandage of unwashed crinoline, which is applied just after dipping it in lukewarm water (see Fig. 179). The starch of the crinoline bandage after being wet, stiffens the crinoline as it dries and makes a particularly firm and efficient dressing. A towel folded thin or a piece of compress cloth should be placed against the trunk upon the well side. Against this the circular turns of the bandage rest, thus causing less discomfort to the patient than

Fig. 176.—Fracture of the upper end of the humerus. Note hand, forearm, and elbow bandaged; axillary pad and strap.

Fig. 177.—Fracture of the upper end or shaft of the humerus. Posterior view. Note bandage to forearm and elbow; axillary pad and strap. Note shape of axillary pad.

if they bear directly upon the chest. The forearm is supported by a cravat sling (see Fig. 178). By this method of immobilization no active traction is exerted upon the lower fragment. The weight of the arm, being unsupported at the elbow, exerts slight traction.

On account of the absence of active traction, ambulatory apparatus can not hold a fracture of the shoulder properly if there is much displacement; particularly if the fracture is oblique. Am-

Fig. 178.—Fracture at upper end of the humerus. Note hand, forearm, and elbow bandaged; axillary pad and strap, plaster-of-Paris shoulder-cap, sling.

Fig. 179.—Fracture at upper end of humerus. Arm and elbow bandaged. Axillary pad and shoulder-cap in position. Application of circular bandage to trunk and shoulder. Sling not shown.

bulatory apparatus can modify muscular action, insure quiet and rest to the part, and, except in the instances just noted, approximately maintain the position secured by manipulation and traction and countertraction. On account of its limitations, therefore, it is important that apparatus should be removed at regular and frequent intervals and that the whole shoulder should be examined in order to determine errors in position and, if possible, to correct them.

After-care of a Fracture of the Shoulder.—Ordinarily, the great

swelling associated with this injury disappears in two weeks. As the swelling subsides, the normal contour of the shoulder becomes apparent again. It is necessary, therefore, to alter the shoulder splint and to apply a fresh one. When the patient wearing a shoulder-cap lies down, there is a tendency for the shoulder-cap to ride up and away from the shoulder. This can be guarded against by carrying the retaining bandage under the firm axillary pad and well over the shoulder. Pressure points should be carefully watched, and the pressure removed. In the course of the treatment of a single case this change of dressing will have to be made two or three times. Union will be firm in from three to four weeks. As soon as union is firm, all splints may be omitted. The forearm should then be held by a sling supporting the wrist. At night it will be wise to apply a single swathe the first week after the apparatus is left off in order to avoid undue motion at the shoulder during sleep. In these injuries about the shoulder-joint passive motion should be made rather early. At the end of two weeks or two weeks and a half repair will have proceeded far enough to allow of the gentlest movement at the shoulder without causing any displacement of fragments. The sooner these gentle movements can be resumed at regular and short intervals, the more rapidly the shoulder will improve. The common occurrence of a periarthritis after an injury to the shoulder emphasizes the necessity of massage. It should be begun as early as the second or third week.

Prognosis and Result.—In young subjects a useful arm will result (see Fig. 180). At first, if there is great difficulty in maintaining the reduction of the fragments, the surgeon will expect a poor result, but if he persists in efforts at retention and uses passive motion early, gradually the movements of the arm will return and to a surprising degree. In people past middle life there usually is a little shortening of the upper arm and impairment in some few of movements of the shoulder, as in abduction and external rotation. In individuals over fifty years old, excepting those with rheumatism, a useful but not a strong shoulder results (see Fig. 181).

The Prognosis in Separations of the Epiphysis: Bony union is to be expected. If there is little or no displacement of frag-

ments, complete restoration of function will result. If there is some deformity remaining after consolidation of the injury, the

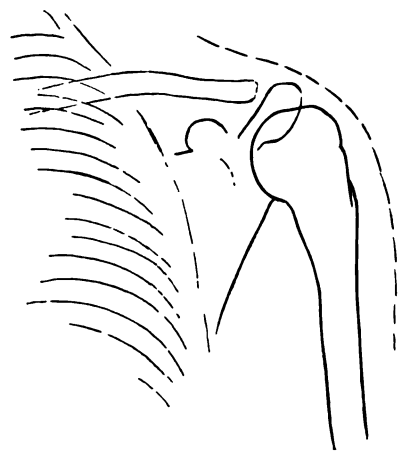

Fig. 180.—Young adult. Fracture of the surgical neck of the humerus (X-ray tracing, four years after the accident). Abduction and rotation very slightly limited. Useful arm.

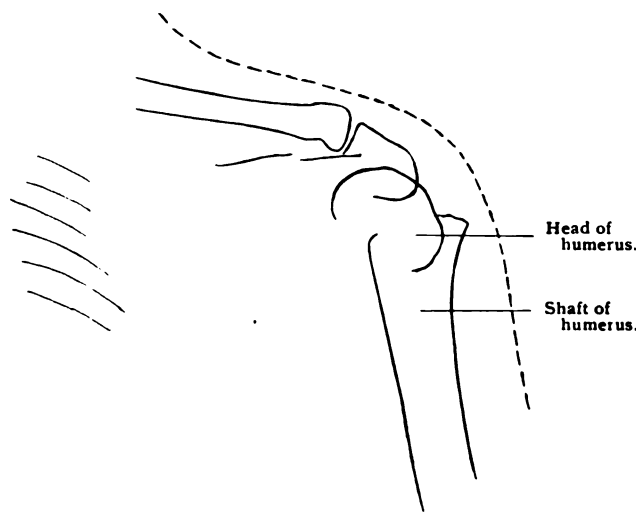

Fig. 181.—Fracture. Man fifty-five years of age. High surgical neck of humerus. At the end of five years recovery with very slight limitation of motion in all directions. Abduction is limited nearly one-half. Useful shoulder (X-ray tracing. Massachusetts General Hospital, 1021).

usefulness of the shoulder is ultimately and usually restored. The deformity becomes less apparent as the sharp bony corners are

smoothed off by the newly forming callus. It is not to be forgotten in considering the prognosis after all shoulder injuries that much of the persisting disability may result from too prolonged immobilization of the arm, even though bony displacement may not have been very great. The growth of the shaft of the humerus in length proceeds largely from the upper epiphysis. It has been thought by many that an arrest of growth of the humerus will follow separation of this upper epiphysis. It has been reported to have occurred in eight cases but in no others. In several of these cases the injury to the shoulder was thought at the time to have been a simple contusion or sprain. A loss of growth is not likely to occur, but may follow injury to the upper humeral epiphysis.

Oblique Fracture of the Surgical Neck with Great Displacement.—This fracture can sometimes be held by placing the patient in bed upon the back and making direct traction to the upper arm and countertraction upon the shoulder by weight and pulley. If the fracture can not be easily held reduced, it will be wise to make the closed fracture an open one and to unite the two fragments by suture (see Figs. 174, 175).

Fracture of the Shoulder, Surgical or Anatomical Neck of the Humerus, or Separation of the Upper Epiphysis of the Humerus, Together with a Dislocation of the Upper Fragment.—The head of the humerus is found in an unnatural position and it fails to move when the arm is rotated. This is generally thought to be an unusual accident, but by careful examination many of these cases may be detected. During the attempt at reduction of a dislocated shoulder, fracture of the humeral shaft is liable to occur. Among many cases of fracture of the surgical neck the fracture occurred fifty-nine times while an attempt at reduction of a dislocation of the shoulder was being made.

Treatment.—Obviously, attempts at reduction by manipulation in the usual way will meet with failure. An attempt should always be made to reduce the dislocation by abduction and traction upon the upper arm and pressure with the hand upon the loose head in the axilla. It may be possible to reduce the dislocation in this manner. If this method fails, an attempt should be made to reduce the dislocated head by open incision (arthrotomy) and

manipulation of the upper fragment assisted by the McBurney-Porter hook manœuver. If this attempt is successful, the shaft should be sutured, with an absorbable suture or fine silver wire, to the reduced head, and the shoulder treated as if a closed fracture existed.

If it is impossible to reduce the dislocated head or if the head is much comminuted, it will be necessary to excise it.

If operative interference has been decided upon, it is best to defer the operation until the acute symptoms have subsided and the damaged tissues have recovered themselves. It is the result of experience that operation through acutely damaged tissues is unwise. The vitality of the tissues is lessened by trauma, hence the resistance to infection is temporarily impaired.

If the reduced head of the humerus becomes necrosed and abscesses form about the joint, an unusual occurrence, the head of the bone should be immediately excised.

The After-treatment of Operated Cases.—If reduction and suturing have been accomplished, passive motion should not be attempted until the repair at the seat of fracture is well under way. This will be about the second week. Then gentle movement may be made and gradually increased.

If resection has been performed, passive motion should be gently begun almost immediately—*i. e.*, within the first forty-eight hours—and persistently continued. The muscles of the shoulder should be massaged and treated by electricity. Abduction should not be attempted to any great extent for some weeks after the operation for fear of displacing the upper end of the humerus too far from the glenoid cavity. The final results following reduction and suturing have been, as a rule, excellent, useful arms resulting in most cases. The results following excision are only fairly satisfactory. If the proper amount of bone has been removed, ankylosis will not occur. If too much bone has been removed, a dangling or flail joint will result. An excision is to be avoided if possible.

FRACTURES OF THE SHAFT OF THE HUMERUS

Fracture of the shaft of the humerus may occur at any point between the surgical neck and the condyles (see Fig. 182). Its

common seat is at the middle or in the lower third of the bone (see Fig. 183). The twisting force exercised in the breaking up of adhesions in and about the shoulder-joint will often fracture a humeral shaft obliquely. The strength test of the arms, as seen in the illustration, has been the cause of spiral fracture of the humerus (see Figs. 184, 185).

Symptoms.—The symptoms are readily recognized. They are swelling at the seat of fracture, pain, crepitus, abnormal motion, and ecchymoses. Paralysis of the musculospiral nerve may occur,

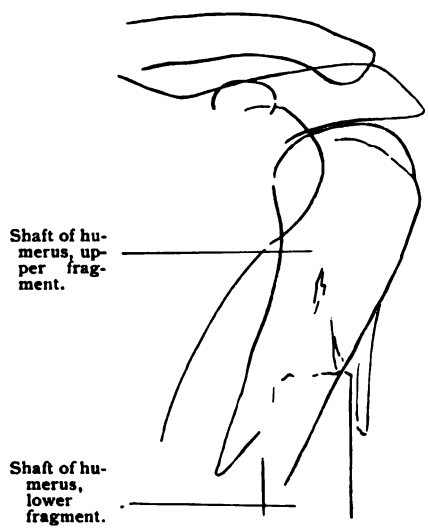

Fig. 182.—Fracture of shaft of humerus, high. Displacement of lower end of upper fragment inward (X-ray tracing).

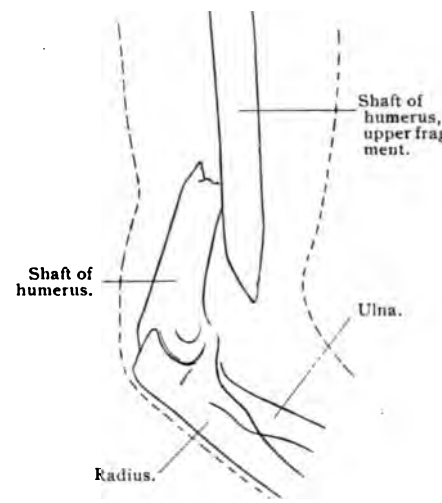

Fig. 183.—Fracture of the shaft of the humerus in lower third. Displacement of both fragments forward (X-ray tracing).

with the characteristic wrist-drop. Ordinarily, the attention of both the patient and the surgeon is so occupied with the fracture of the bone and its associated loss of movement that loss of power and sensation, because of involvement of the nerve, go unrecognized. If injury to the musculospiral nerve is not recognized at the outset, it may be overlooked until the splints are removed. The exact duration and the cause of the paralysis can not then be readily ascertained. The patient may wrongly attribute the paralysis to the pressure of the splints. Very rarely, injury or pressure upon the large vessels of the arm is met with. Damage to the

Fig. 184.—Trial of strength of arms resulting sometimes in spiral fracture of the humerus (Monks). See figure 185.

Fig. 185.—Illustrating spiral fracture of humerus (Monks). See figure 184.

artery will be suggested by weak or absent pulse at the wrist or by local evidences of hemorrhage. A swelling appearing suddenly, greater than that which would appear from the laceration of soft tissues alone, should suggest rupture of large vessels.

Fig. 186.—Longitudinal fracture of shaft of humerus into the joint. Displacement of smaller fragment backward. Note space between fragment and shaft. Arm extended.

Measurement of the humerus should be made from the edge of the acromial process to the external condyle of the humerus (see Fig. 154). The amount of overlapping of the fragments will be shown by this measurement.

Treatment.—For purposes of treatment, fractures of the shaft may be grouped into those with little or no displacement and those with considerable displacement and difficult of retention after reduction. The fracture should be reduced by traction upon the

Fig. 187.—Same as figure 186. Note the disappearance of space between fragments with correction of deformity upon flexing forearm. Position reduces the fracture.

condyles of the humerus and countertraction upon the upper arm and by manipulation of the fractured bones.

Treatment of Fractures of the Shaft of the Humerus with Little or no Displacement (see Figs. 188, 189).—The following materials are needed for the apparatus to be used: Ordinary dusting-powder,—which is powdered oxid of zinc and powdered starch, equal

Fig. 188.—Fracture of the shaft of the humerus. Note bandage to hand, forearm, and elbow axillary pad and strap; coaptation splints and sling. Bandage does not cover fracture.

Fig. 189.—Fracture of the shaft of the humerus. Note bandage to hand, forearm, and elbow; adhesive-plaster swathe holding arm upon axillary pad and covering coaptation splints. Sling.

parts; a bandage of Shaker flannel three inches wide, not cut on the bias; an axillary pad made with several layers of sheet wadding covered with a folded piece of pasteboard, and the whole in-

Fig. 190.—Space to be filled by axillary pad between arm and side in fracture of humerus.

Fig. 191.—Coaptation splint seen flat and in section. Made by laying thin wood on adhesive plaster and splitting with knife.

Fig. 192.—Showing effect (bowing outward) of too short an axillary pad upon a fracture of the shaft of the humerus.

closed in cotton cloth stitched at the edges; the pad is V-shaped, and long enough to extend from the apex of the axilla to just above the internal condyle of the humerus; it is broad enough to

support the upper arm comfortably and securely; the lower part of the pad is about three inches thick (see Fig. 190), so as to support the arm only a trifle abducted from the side—that is, just away from the perpendicular. If the axillary pad is too short, there is danger of causing an outward bowing of the humerus (see Fig. 192). Two straps are attached to the upper corners of the apex of the V-shaped pad long enough to surround the body and go over the opposite shoulder. These straps hold the pad in position. The remaining apparatus consists of two or three thin coaptation splints for application to the upper arm; these are

Fig. 193.—High fracture of the shaft of the humerus. A common and improper use of an internal right-angle splint.

made readily by laying thin splint wood upon adhesive plaster, and splitting the wood longitudinally (see Fig. 191); three adhesive straps two inches wide to hold the coaptation splints; an adhesive plaster swathe wide enough to extend from the acromion tip to the external condyle, and long enough to surround the body and upper arm; a cravat sling; a thin towel or piece of compress cloth for the forearm to rest upon. All these articles should be in readiness.

Etherization of the patient will rarely be necessary. In cases of nervous and sensitive women and unmanageable young chil-

dren it will be wise to use an anesthetic. The whole upper extremity, axilla, and chest should be washed with soap and water, thoroughly dried, and dusted with powder; then the reduced fracture is held in position by an assistant while the apparatus is being applied. The hand, forearm, and elbow should be snugly and evenly covered by the flannel bandage (see Fig. 176). The upper arm should be surrounded by the coaptation splints, held in place by the three straps of adhesive plaster, so as to secure the fractured bone perfectly (see Fig. 188). The axillary pad should be placed in the axilla and held by the straps passed over the opposite shoulder and under the opposite axilla. The upper arm should rest comfortably upon the pad. To prevent chafing, the thin towel or compress cloth should be placed beneath the forearm where it touches the body. The plaster swathe should then be applied over the arm to the body, so as to encircle completely the trunk (see Fig. 189). Thus the arm is absolutely fixed to the axillary pad and side. The wrist should be supported in a cravat sling passed around the neck. The elbow is left unsupported. The weight of the upper extremity will thus tend to exert slight downward traction upon the lower fragment of the humerus. Under no circumstances should an ordinary broad sling be used, because of the danger of making upward pressure upon the forearm and elbow and so pushing up the lower fragment of the humerus. The elbow-joint should not be immobilized for the reason that it would then be much more difficult to hold the seat of fracture fixed. With the elbow-joint fixed, the lower arm of the lever is greatly increased, and instead of movement of the forearm taking place at

Fig. 194.—View of right humerus from above, showing axes of upper and lower ends. Head of bone looks in the same general direction as the internal condyle, but slightly further backward. These relations are to be preserved when treating fractures of the shaft of the humerus.

the elbow-joint it would take place at the seat of fracture. Fractures of the shaft of the humerus are frequently treated by an internal angular splint and coaptation splints, the upper ends of the splints barely reaching the fracture, or, at best, being an inch or two above it (see Fig. 193). When the fracture of the bone is within the lower third of the shaft, then and then only should an internal angular splint be used in connection with coaptation splints.

After-treatment.—The patient should be seen each day for the first three days in order that the surgeon may be informed as to the exact condition of the parts. There may be undue pressure. The patient may be uncomfortable. The splints may need readjusting. Attention to little details of discomfort is important. The dressing should be reapplied with great care once each week. The parts covered by splints should at each dressing be carefully inspected to detect any points of undue pressure, indicated by reddening of the skin. If these are discovered, they should be washed with alcohol and covered with flexible collodion or a drying powder. The undue pressure should be removed by shifting the padding. Union will be found to be firm after about three or four weeks. As soon as union is solid,—at the end of four or five weeks,—the swathe may be omitted, the coaptation splints alone being a sufficient support. After about five weeks or five weeks and a half all support may be removed from the arm. The arm is then put in the sleeve of the clothes, and the wrist supported by a sling. After eight weeks the sling may be discarded and moderate and careful use of the limb in light movements be indulged in.

Fracture of the Shaft of the Humerus with Considerable Displacement.—Obviously, the method described for the treatment of fractures without great displacement will be of comparatively little value. Occasionally, it will be found that this method will hold even greatly displaced fractures; it should then be used. The ideally perfect method for such cases is traction and countertraction upon the arm with the patient lying on the back in bed. Coaptation splints should be used, as in simple uncomplicated fractures. If all methods fail to hold the fragments reduced, open incision, reduction of the displacement, and suturing of the fragments are indicated.

The plaster-of-Paris splint, applied with the plaster roller to the forearm and arm, and the spica bandage to the shoulder and chest are often efficient in these difficult cases. In the application of this splint it is of supreme importance that an assistant hold the arm so that the alinement of the bones remains perfect. The assistant who holds the arm should have nothing else to do. Before applying the plaster-of-Paris splint it is often advisable to apply thin coaptation splints at the seat of fracture to give additional strength to the splint. With these coaptation splints in use a lighter plaster splint may be applied without sacrificing strength. A narrow cotton swathe about the body and arm should steady the upper extremity. The wrist should be supported by a cravat sling.

The after-care of a case treated by the plaster splint will be similar to that following any other treatment after union has occurred. The plaster may be left *in situ* for four weeks; then, ordinarily, repair will be found so far advanced that the plaster splint may be dispensed with and the ordinary coaptation splints and swathe may be used. If the plaster splint has proved comfortable, it may be split and reapplied.

Massage and Passive Motion: In view of the possibility of nonunion of this fracture, it will be wise not to begin massage until union has begun. Passive motion to the shoulder and elbow should be gently made at as early a date as possible, with due consideration to the condition of repair in the fracture. If at the end of three weeks union is found to have begun, it will be wise to move the shoulder and elbow gently by passive motion. The seat of fracture should be cautiously guarded against movement during these gentle manipulations. A little gentle passive movement of this sort repeated occasionally during the process of repair will assist very considerably in the restoration of the functional usefulness of the shoulder and elbow, which so often become stiff from immobilization.

Prognosis.—Ordinarily, union occurs readily in from four to six weeks. In childhood union is quite solid in from three to five weeks. Fractures of this bone are more likely to be followed by nonunion than fracture of any other bone in the body. The presence of abnormal mobility after a considerable time (three

months) has elapsed is the sign of nonunion by bone. Considerable muscular atrophy follows this fracture (see Fig. 195). Upon using the arm again and by massage the size of the arm is, in a great measure, restored. The stiffness of the shoulder and elbow which is sometimes associated with this injury is due to long immobilization without passive motion.

Fracture of the shaft of the humerus sometimes occurs in the new-

Fig. 195.—Case: Fracture of the shaft of the left humerus. Fracture united. Note atrophy of upper arm, including deltoid. Loss of muscular contour very apparent.

born during delivery or afterward. The arm is best immobilized by thin coaptation splints. These splints may be as thin as six thicknesses of ordinary letter paper, and may be made of cardboard. The humerus is completely surrounded by them. They are held firmly by adhesive-plaster straps. If they are cut the right length and width, they may be applied most efficiently without padding. A liberal amount of drying powder should be rubbed on the arm and chest. A piece of compress cloth should

be placed on the side of the chest under the injured arm, to prevent chafing. The upper arm is then held to the side of the chest by a gauze or other cloth swathe. Repair is rapid. Union is firm in about three weeks. Fracture of the humerus in the newborn is sometimes associated with obstetrical paralysis of the upper extremity. This obstetrical paralysis should not be confounded with musculospiral paralysis.

The Musculospiral Nerve in Fracture of the Humerus.—The musculospiral nerve may be involved in fracture of the humeral shaft, particularly if the fracture is at the middle or in the lower third of the bone. The nerve lies in the musculospiral groove of the humerus. It leaves the bone a little below the junc-

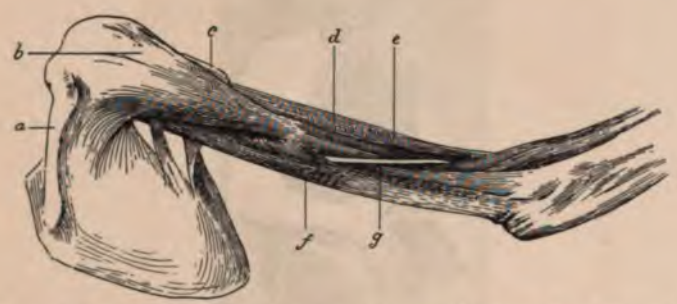

Fig. 196.—Relations of musculospiral nerve on outer side of arm (from dissected specimen): *a*, Clavicle; *b*, deltoid; *c*, pectoralis major; *d*, biceps; *e*, brachialis anticus; *f*, triceps; *g*, musculospiral nerve.

tion of the middle and lower thirds of the arm (see Fig. 196). The nerve may be involved primarily at the time of the accident by the contusion or laceration caused by the original violence or by the pressure of bony fragments. The nerve may also be involved secondarily by the pressure of the bony callus or of the cicatricial tissue of the soft parts.

Symptoms.—Contusion of the musculospiral nerve may be slight or severe. If slight, there will be pain at the injured place, and a tingling and numbness along the distribution of the nerve. These symptoms may pass away quickly or the tingling may remain several days. If it remains, a chronic neuritis is established associated with shooting and neuralgic pains. If the contusion is severe, there will be complete anesthesia and complete paralysis

of the nerve below the place involved. This may pass away early or it may remain several months or it may become permanent. Pressure upon the nerve from callus, cicatricial tissue, and bony fragments will give signs of disturbed sensation and motion in the parts supplied by the nerve.

Compression of the Musculospiral Nerve: The musculospiral nerve supplies the triceps, brachialis anticus, supinator longus, and extensor carpi radialis longior muscles. Inability to extend the fingers and wrist and loss of supination are the usual signs of motor paralysis following compression of this nerve. As for sensation, there will be complete loss or impaired sensation in the

Fig. 197.—Double fracture of humeral shaft. Immediate musculospiral paralysis. Union of bones in six weeks. Operation to free nerve from lower fragment. Sensation and motion returned. Same case as figure 198.

lower half of the outer and anterior aspect of the arm and in the middle of the back of the forearm as far as the wrist.

Treatment.—Immediate paralysis does not necessarily mean pressure by a bony fragment. Such paralysis may be associated with contusion; therefore, operative interference should be delayed. If the symptoms persist for four or five months, exposure of the nerve and relieving, if possible, the conditions found are indicated. It is wise to allow the fractured bone to unite before operating.

The prognosis after the removal of pressure and following resection and suture of the musculospiral nerve is good as to the ultimate partial or complete recovery. After a few days or weeks

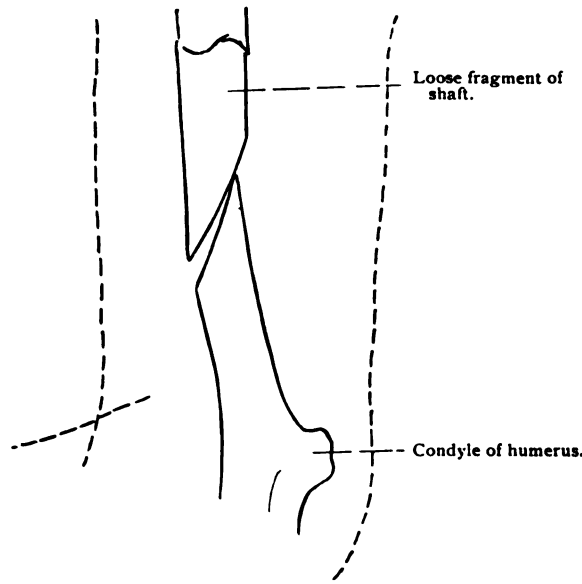

Fig. 198.—Same as figure 199. Lateral view to show displacement of fragment (X-ray tracing).

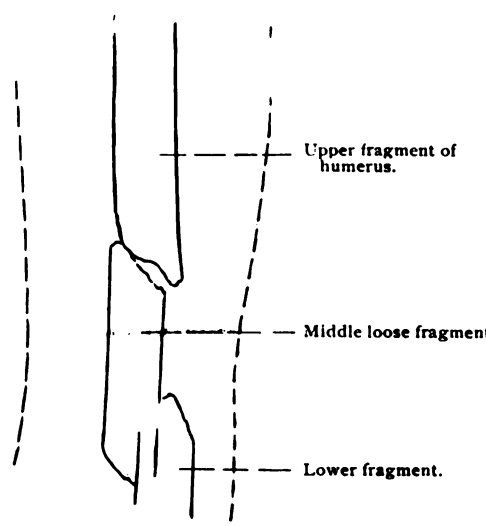

Fig. 199.—Double fracture of the humerus. Paralysis of the musculospiral nerve. Immediate union of bone. Suture of nerve found caught between fragments. Gradual recovery. Same as figure 198 (X-ray tracing).

sensation will return. After a few months—five or eight—motion will begin to return (see Figs. 197, 198, 199).

Malignant Disease.—Carcinoma is said to have occurred secondarily in a fractured bone. Sarcoma develops in the callus of fractures. It is highly probable that in many of the so-called sarcomata of callus the disease preexisted in the bone, and was the reason for the fracture occurring after trivial injury.

FRACTURES OF THE ELBOW

Fractures of the lower end of the humerus near to and involving the elbow-joint are frequent in childhood, but much less frequent

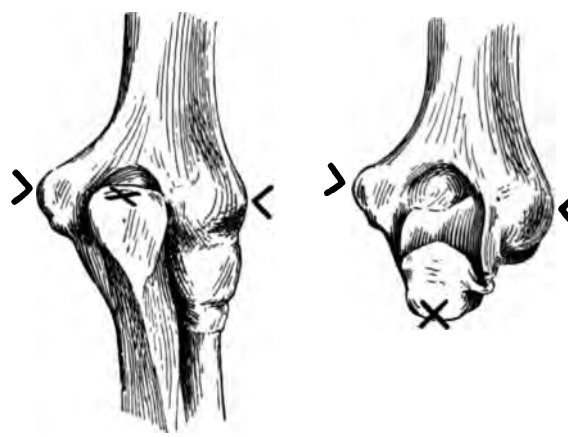

Fig. 200.—The relations of the three bony points at the elbow in extension and in flexion (from behind). The marks are placed upon the internal and external condyles and olecranon process (diagram).

in adults. A familiarity with the bony landmarks of the elbow is essential to an accurate diagnosis. The more nearly accurate the diagnosis, the more efficient will be the treatment and the more intelligent will be the prognosis. Every elbow injury, no matter how trivial, should be examined under anesthesia.

Method of Examination.—The normal anatomical relations of the uninjured elbow are to be first determined. The large prominent internal condyle of the humerus, the olecranon process of the ulna, the external condyle, the head of the radius are each in turn to be grasped by the thumb and forefinger. If these

bony points can be recognized upon the injured elbow, then a fracture ought not to be overlooked.

The Three Bony Points of the Elbow Region: With a pencil or ink the internal and external condyles of the humerus and the tip of the olecranon should be marked, the forearm being extended. Normally, these three points will be found to be in nearly a straight line transverse to the long axis of the limb. The tip of the olecranon is a trifle above this line (see Figs. 200, 201).

Palpation of the Three Bony Points: Grasping the left wrist

Fig. 201.—Normal elbow. Relation of the three bony points in almost complete extension of forearm. Prominence of olecranon and two condyles evident.

with the left hand, place the right thumb upon the external condyle, the third finger on the internal condyle, and the forefinger on the olecranon. When the elbow is at a right angle, these three points will be found in the same plane with the back of the upper arm. A similar examination may be made of the right elbow, changing hands for convenience (see Figs. 200, 202).

The Head of the Radius (see Fig. 205): Grasping the elbow with one hand, the thumb resting one-half an inch below the external condyle upon the head of the radius, and holding the wrist in the other hand, the patient's forearm is pronated and

Fig. 202.—Normal elbow. Examination. The three bony points. Note position of the thumb and two fingers of the examining hand.

Fig. 203.—Normal elbows. Well-marked carrying angle apparent.

supinated. If the shaft of the radius is unbroken, the head of the radius will be felt to move under the thumb.

The Carrying Angle (see Figs. 203, 204): The lateral angle that the supinated forearm makes with the upper arm is called the carrying angle. It is important to remember that this angle varies normally within very wide limits. Some individuals have no carrying angle. Its presence or absence is of little functional value.

Movements at the Elbow-joint: The movements of the joint

Fig. 204.—Position of supination, showing the carrying angle. The outline shows the position of pronation with disappearance of the carrying angle.

should be determined both in flexion and extension. There is normally no lateral motion in the extended elbow-joint. Abnormal lateral motion in either adduction or abduction should be detected if present.

Measurements: The distance between the two condyles should be measured on the uninjured arm. The distance from the acromial process to the external condyle of the humerus should also be measured (see Fig. 154).

Having then established a standard of comparison in the normal

elbow, the injured elbow should be examined with the greatest care. Even when there is great swelling of the elbow region, steady pressure will enable the fingers to reach the condyles. In approaching an injury to the elbow the questions which arise are: Is there a dislocation? Is there a fracture? Are both dislocation and fracture present? Is there a contusion and a sprain? Is there a subluxation of the radial head? In the absence of positive signs of dislocation, subluxation, and fracture the lesion is a sprain

Fig. 205.—Normal elbow. Method of examination. Palpating head of radius. Spot marks external condyle.

or contusion. In the absence of positive signs of dislocation and radial subluxation a fracture will be present.

Summary of the Order of Examination of the Injured Elbow.—Notice whether the swelling and ecchymosis are general or localized. If localized, that may determine the seat of the lesion. Observe the carrying angle. Palpate the external and internal condyles (see Fig. 206), the olecranon process of the ulna (see Fig. 207), and the head of the radius (see Fig. 205). Determine if crepitus

Fig. 206.—Normal elbow. Method of examination. Grasping the two condyles of the humerus.

Fig. 207.—Normal elbow. Method of examination. Palpating olecranon.

is present. See if the head of the radius rotates. Note the relations of the three bony points, with the forearm flexed at a right angle and completely extended (see Figs. 200, 201, 202). Note any lateral motion at the elbow-joint (see Fig. 208). Determine the possible movements of the elbow-joint. Make measurements.

The traumatic lesions of the elbow may be grouped, for simplicity and ease of reference, in the following manner. During

Fig. 208.—Normal elbow. Line between the condyles. Method of examining for supracondyloid fracture.

the routine examination it is wise to have in mind these possible individual lesions:

Lesions of the Radius and Ulna: (*a*) Dislocation of the radius and ulna backward with or without fracture of the coronoid process of the ulna.

(*b*) Subluxation of the radial head.

(*c*) Fracture of the olecranon process of the ulna.

(*d*) Fracture of the neck or head of the radius.

Lesions of the Lower End of the Humerus: (*e*) Fracture of the internal epicondyle (see Fig. 209, *c*, *c*).

(*f*) Fracture of the internal condyle (see Fig. 209, *b*, *b*).

(*g*) Fracture of the external condyle (see Fig. 209, *d*, *d*).

(*h*) Transverse fracture of the shaft of the humerus above the condyles (supracondylar) (see Fig. 210, *a*, *a*).

(*i*) Separation of the lower epiphysis of the humerus.

(*k*) T-fracture into the elbow-joint (see 209, *a*, *a*, *a*, and Fig. 210, *b*, *b*, *b*).

Symptoms of Lesions About the Elbow-joint with the Differential Diagnosis of Each Lesion.—(*a*) A Dislocation of the Radius and Ulna Backward with or without Fracture of the Coronoid Process of the Ulna: There may be very great swelling of the region of the elbow. The relations between the three bony points are

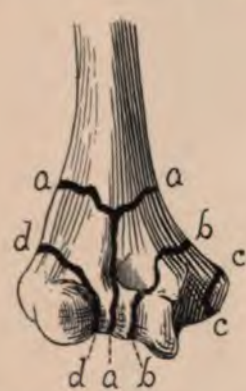

Fig. 209.—T-fracture, high (*a*, *a*, *a*). Fracture of internal condyle (*b*, *b*). Fracture of internal epicondyle (*c*, *c*). Fracture of external condyle (*d*, *d*) (diagram).

Fig. 210.—Supracondyloid fracture (*a*, *a*). T-fracture low down (*b*, *b*, *b*) (diagram).

disturbed. The olecranon process is very prominent posteriorly. The radial head is displaced backward. The two condyles are far in front of the olecranon. There is abnormal lateral mobility. The normal movements of the joint are restricted. This injury may be mistaken for a supracondylar fracture. The important difference has been mentioned. A dislocation of both bones backward, if reduced, does not ordinarily tend again to become displaced; if it does, there is most likely a fracture of the coronoid process of the ulna.

(*b*) Subluxation of the Head of the Radius: This takes place in children under five years of age. It is due to sudden traction

upon the extended forearm, which so often occurs in lifting a child by the arm over a curbstone. The child presents the arm hanging slightly away from the side, with the elbow a little flexed and the hand semipronated. Attempts to use the arm cause pain. The extremes of flexion and extension and supination are painful. Inspection will detect a slight swelling one-half of an inch to an inch below the external condyle of the humerus. Tenderness is

Fig. 211.—Fracture of the internal condyle. Recovery with "gunstock" deformity, due to slipping upward of fragment and adduction of forearm.

present over the head of the radius. The relation of the three bony prominences is preserved. The details of this not uncommon lesion are mentioned because it is sometimes mistaken for a fracture of the radial head or a simple sprain of the elbow. A fracture of the radius below the neck has also been mistaken for this subluxation of the head. Careful detailed examination will alone clear up any doubts.

(*c*) Fracture of the Olecranon Process: The details of this fracture are considered elsewhere. Crepitus and mobility of the olec-

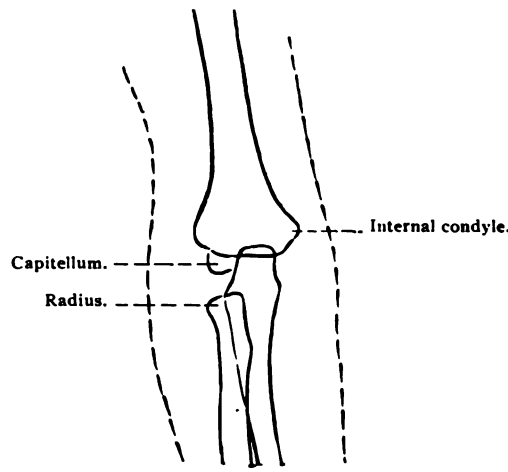

Fig. 212.—Normal right arm of patient in figure 211 (X-ray tracing).

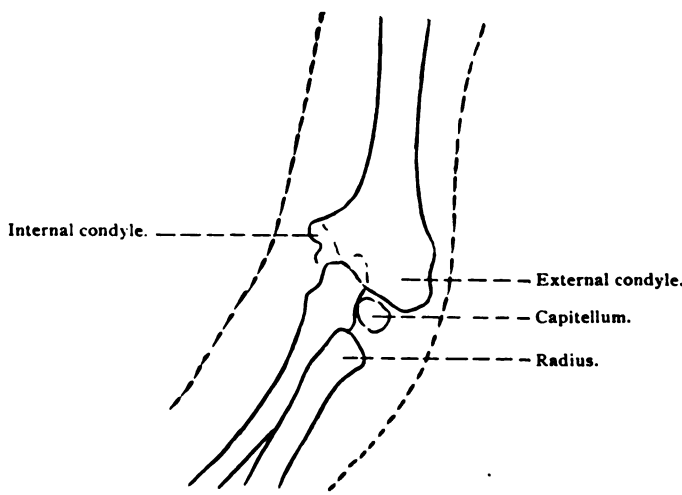

Fig. 213.—Fracture of internal condyle of left humerus. Recovery with deformity. See figure 211 (X-ray tracing).

ranon fragment will be felt. There may or may not be separation of the fragments. If there is a separation, it will be detected and the three bony points will have their normal relations disturbed.

(*d*) Fracture of the Neck or Head of the Radius: This is uncommon. Swelling over the radial head and neck is present. Supination and pronation are painful and limited and attended by crepitus, muscular spasm, and possibly a loss of rotation of the radial head.

(*e*) Fracture of the Internal Epicondyle: The epiphysis of this epicondyle unites to the shaft of the humerus between the eighteenth and twentieth years. This fracture is quite common among little children. If this fracture presents a small fragment, it is of little consequence. If a large fragment is broken off, it is

Fig. 214.—Rachitis, showing adduction of right forearm, as in figure 211.

of consequence. The displacement is downward and forward. The ulnar nerve is sometimes, though rarely, implicated in this injury.

(*f*) Fracture of the Internal Condyle: Swelling over this condyle is marked. By grasping the condyle abnormal mobility and crepitus are detected between the fragment and the shaft. The inner of the three bony points is displaced upward. Lateral mobility of the elbow is present; adduction is especially free. The carrying angle will be diminished if there is displacement of the condyle upward (see Figs. 211, 212, 213).

(*g*) Fracture of the External Condyle (see Fig. 215): Swelling over this condyle is marked. Crepitus and abnormal mobility are present. The normal relations of the three bony points are disturbed. The external condyle is displaced upward. The relation of the external condyle and the head of the radius is undisturbed. Lateral motion at the elbow is or is not present. The transverse measurement of the elbow is greatest on the injured side. Supination will be somewhat limited.

(*h*) Transverse Fracture of the Shaft of the Humerus Above the Condyles. Supracondyloid Fracture (see Fig. 216): The line of this fracture is higher up on the shaft than the line of the epi-

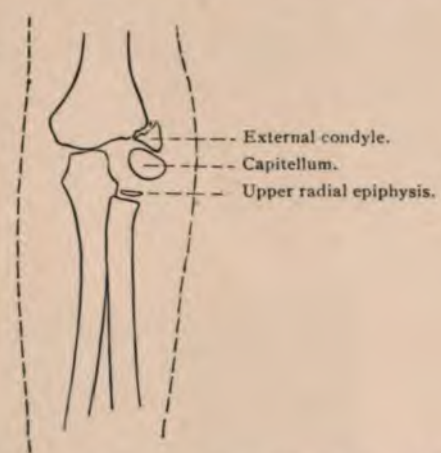

Fig. 215.—Fracture of external condyle of humerus. Child five years of age. Nucleus for capitellum seen below fragment.

physis. A fullness will be noticed in front of the elbow-joint, and posteriorly the point of the elbow will appear prominent. The small lower fragment is displaced backward with the bones of the forearm; the upper fragment or shaft of the humerus is displaced forward, causing the fullness in the bend of the elbow (see Fig. 218). The three bony points maintain their normal relations. This distinguishes the fracture from a dislocation of both bones backward (see Fig. 219). Crepitus will be detected upon grasping the arm firmly above and below the elbow-joint (see Fig. 208). Recurrence of the displacement often follows its correction unless the fracture is properly immobilized. Abnormal lateral and an-

Fig. 216.—Case of transverse fracture above the condyles of the left humerus; characteristic deformity. The anterior deformity is higher than in a case of dislocation of the elbow.

Fig. 217.—Transverse fracture above the condyles of the humerus. Same as figure 216.

teroposterior mobility above the elbow-joint is found (see Figs. 216, 217).

(*i*) Separation of the Lower Epiphysis of the Humerus: The

Fig. 218.—Supracondyloid fracture of humerus. Elbow flexed to a right angle. Diagram to show displacement of bones.

Fig. 219.—Dislocation of both bones of the forearm backward. Elbow flexed to right angle. Diagram showing relative position of bones. Compare with figure 218.

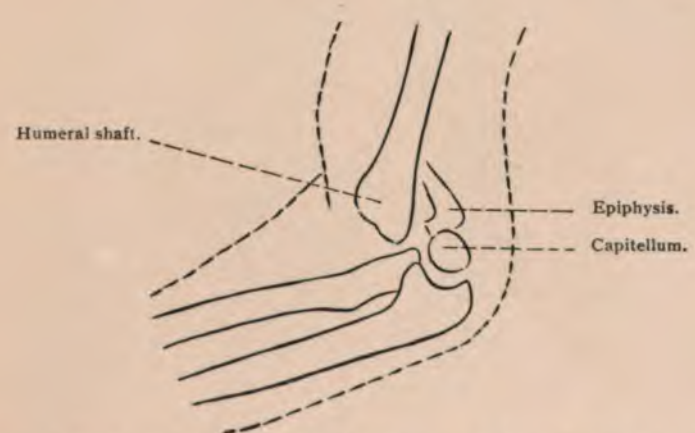

Fig. 220.—Displacement of lower epiphysis of humerus backward, with fracture of the diaphysis. Child seven years of age (X-ray tracing).

lower epiphysis of the humerus unites to the shaft about the seventeenth year. It includes only the very lowest end of the humerus. The lower epiphysis of the humerus is made up of the external epicondyle, the capitellum, and the trochlea. These separate

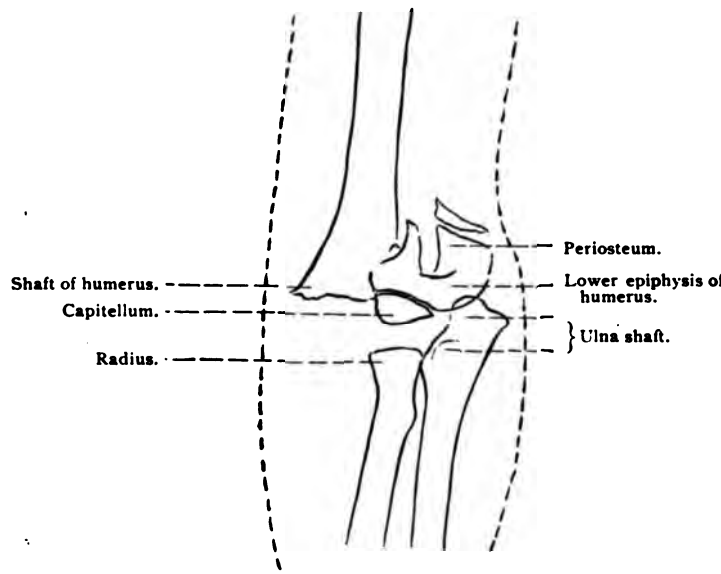

Fig. 221.—Separation of the lower epiphysis of the humerus and displacement of the forearm inward. Boy nine years of age. See figure 222 (X-ray tracing) (Massachusetts General Hospital, 1502).

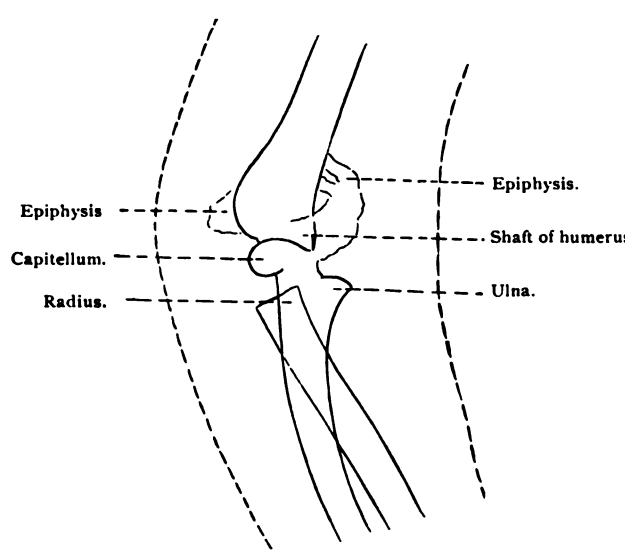

Fig. 222.—Lateral view of figure 221, showing forward displacement of the shell of the epiphysis and the lateral displacement of the ulna (X-ray tracing) (Massachusetts General Hospital, 1502).

centers of ossification unite about the thirteenth year, and at about the seventeenth year they join the shaft of the bone. The

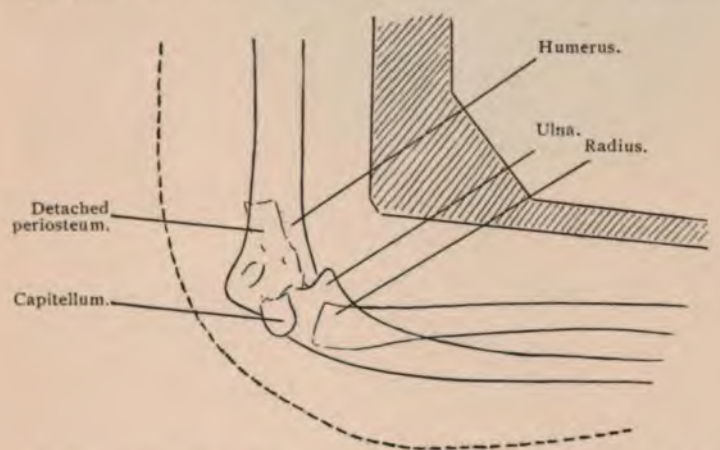

Fig. 223.—Same as figure 221, after reduction. Lateral view. Internal right-angle splint seen in position (X-ray tracing).

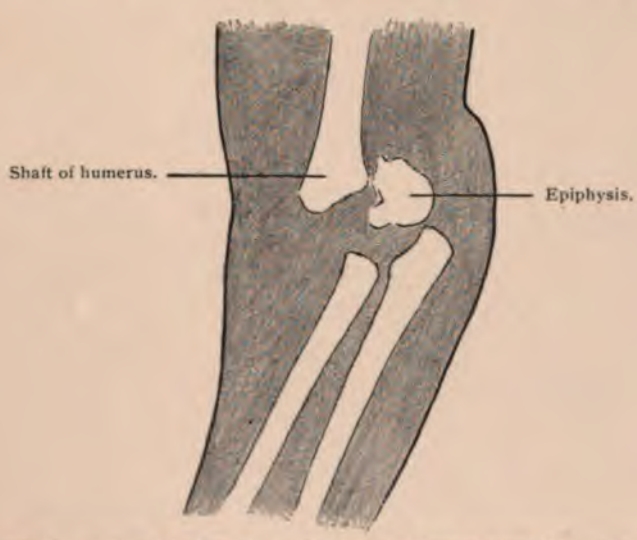

Fig. 224.—Separation of the lower humeral epiphysis (X-ray tracing) (Massachusetts General Hospital, 742).

epiphysis of the internal epicondyle is entirely separate from the large, general, lower, humeral epiphysis.

This is a not uncommon accident. It occurs usually in children

under ten years old. There is no change in the relations of the three bony points. It somewhat resembles transverse fracture

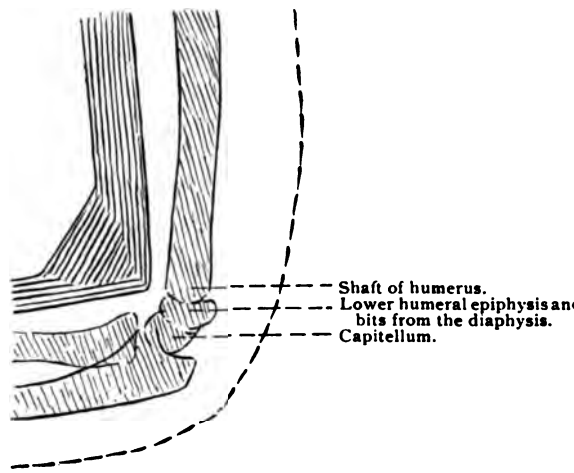

Fig. 225.—Separation of the lower humeral epiphysis. Child nine years of age. Separation reduced. Capitellum and epiphysis distinctly seen in the lateral view. Internal angular tin splint shown.

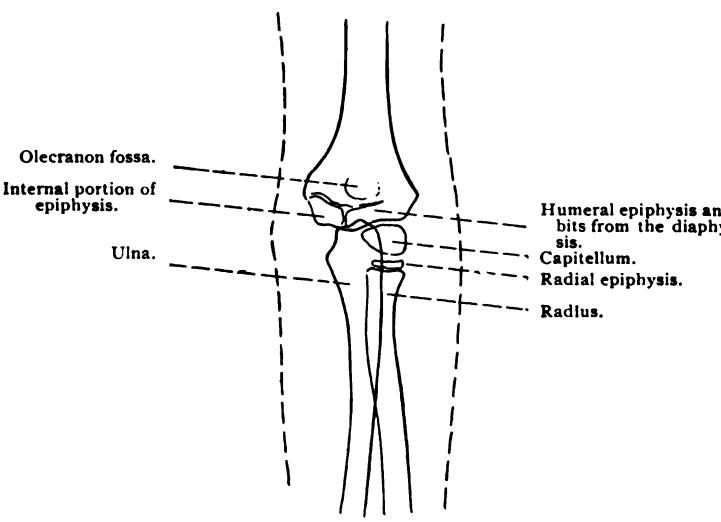

Fig. 226.—Separation of the lower epiphysis of the humerus, after union. Anteroposterior view. This figure illustrates the fact that the epiphysis does not include the condyles of the humerus (X-ray tracing).

above the condyles. The diagnosis is made upon the following points: The age of the individual; the history of the accident;

the existence of abnormal mobility at a very low level on the humeral shaft; anteroposterior mobility very marked, lateral mobility being less marked; muffled crepitus (this term is very

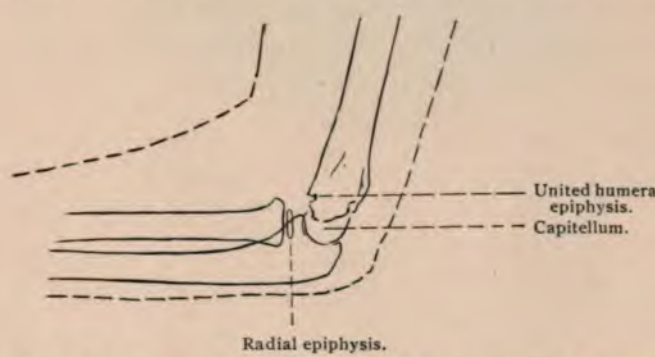

Fig. 227.—Separation of the lower humeral epiphysis, after union. Lateral view. Extension normal. Flexion to a right angle (X-ray tracing) (Massachusetts General Hospital, 1556).

Fig. 228. — Compound fracture of elbow—T-fracture—following epiphyseal lines in part. Boy of about nine years of age. Forearm also extensively injured. Amputation.

Fig. 229.—T-fracture of elbow. Man of forty-five, fell twenty feet and struck elbow, producing compound fracture. Arm amputated (Warren Museum, specimen 999).

Fig. 230.—T-fracture of humerus, low down. Man of forty-eight, fell downstairs. Arm amputated (Warren Museum, specimen 1102).

suggestive, and is used by Poland). The breadth of the lower end of the humeral fragment is broader than in the case of a fracture (see Figs. 220 to 227 inclusive).

(*k*) T-fracture into the Elbow-joint (see Figs. 228, 229, 230): The traumatism which causes this injury may be extremely slight. If the two condyles are grasped, crepitus and abnormal mobility will be detected. The relations of the three bony points will be disturbed, according as one or both condyles are displaced. The transverse measurement of the condyles will be found to be in-

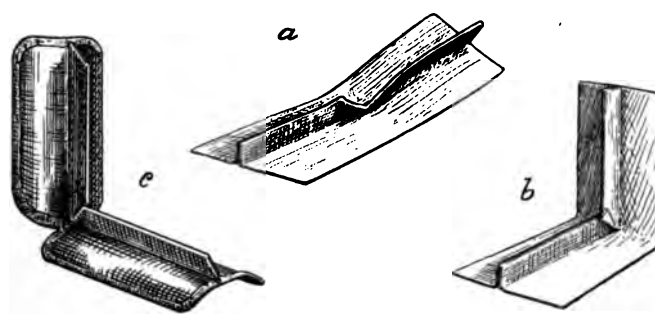

Fig. 231.—Method of manufacture of tin internal right-angle splint: *a*, Form into which piece of tin is folded (with vise and hammer); *b* shows the bend in the back ridge completed (bent with pliers, hammered close in the vise); *c*, the completed splint with edges shaped and covered with adhesive plaster, and with the surfaces of the splint properly concaved.

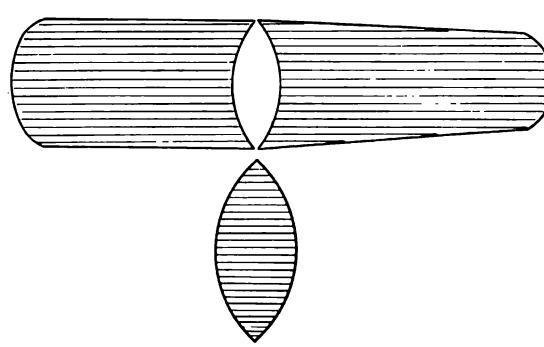

Fig. 232.—Patterns of pieces used in making the usual (soldered) internal right-angle splint, seen applied in figure 242.

creased. There will be abnormal lateral mobility, both in adduction and abduction.

A systematic anatomical examination of injuries to the elbow under an anesthetic will overcome much of the indefiniteness that surrounds these injuries. A crushed elbow, feeling to the examining hand like a bag of bones, can not always be accurately

diagnosed, some of the details of the lesions naturally remaining undetermined. The Röntgen ray in these doubtful cases will be of material assistance. The importance, however, of making such a careful eliminative examination as is described, both from the point of view of treatment and prognosis, can not be overestimated.

Treatment.—The object of treatment is to restore the elbow-joint to its normal condition. If the fracture is attended by great swelling, it will be necessary to temporarily support the arm until

Fig. 233.—Supracondyloid fracture of the humerus. Method of reduction before applying retentive splint. Countertraction on upper arm. Traction on condyles of humerus with right hand; backward pressure with thumb of left hand. Also illustrative of method of beginning acute flexion.

the swelling reaches its maximum and begins to subside. The right-angle internal angular splint is the most satisfactory for this purpose (see Figs. 231, 232). The maximum swelling will have taken place after forty-eight to seventy-two hours. This temporary dressing will rarely be needed. In general, it may be stated that the arm should be placed in that position in which it is found, upon experiment with the fracture under consideration, that the fragments are best held reduced.

Fractures of the internal epicondyle, of the internal condyle, of the

external condyle, and T-*fractures into the joint* are best treated, as a rule, in the acutely flexed position.

Experimental evidence, both upon the cadaver and on the anesthetized living subject, confirmed by clinical experience extending over a number of years in the hospital and private practice of many different surgeons, demonstrates that the acutely flexed position actively reduces and holds reduced the fractures previ-

Fig. 234.—Left elbow in position of forced flexion. Gauze in bend of elbow. Thin axillary pad. Pad under hand and wrist. Gauze protection under forearm, held by safety-pin from slipping. Adhesive plaster maintaining flexion. Skin protected on upper arm by gauze compress from cutting of adhesive plaster.

ously mentioned. In the acutely flexed position the coronoid process in front, the trochlear surface of the olecranon behind, and the fasciæ posteriorly and laterally, together with the tendon of the triceps posteriorly, hold the fragments reduced and close to the shaft of the humerus.

Method of Using the Acutely Flexed Position: The condyles of the humerus are grasped by the thumb and finger of one hand,

a finger of the other hand is placed in the bend of the elbow, traction is made upon the forearm, and it is slowly flexed to an acute angle. While the forearm is being flexed, traction and lateral pressure are brought to bear upon the loose fragments of the humerus to correct existing malpositions. These manipulations will materially assist in the reduction (see Fig. 233).

The degree of flexion will be determined by the obstruction

Fig. 235.—Applying figure-of-eight cravat to flexed elbow (after Lund).

Fig. 236.—Strap from elbow to cravat to prevent abduction of flexed elbow.

offered by the local swelling. If the swelling is great, or is likely to increase very much, then the degree of flexion must be less than when there is no swelling. In the bend of the elbow, to prevent chafing, is placed a piece of gauze upon which has been dusted a dry powder. This acutely flexed position is maintained by an adhesive-plaster strap, three inches wide, passing about the arm and forearm (see Fig. 234). This strap should be placed upon the

upper arm as high as the axillary fold, and upon the forearm just above the styloid of the ulna. A piece of linen or compress cloth (cotton cloth) is placed under the forearm and hand where they would come in contact with the skin of the chest. This should be pinned so as not to slip from position. The arm thus flexed is supported by a swathe sling (see Fig. 235) made of cotton cloth,

Fig. 237.—Fastening figure-of-eight cravat over folded compress on opposite side of chest. Elbow region open to inspection.

Fig. 238.—Adhesive plaster strip showing bits of gauze arranged so as to protect skin from plaster without impairing efficiency of the plaster.

fifteen inches wide, folded three times, and long enough to extend twice around the body. This is applied as illustrated (see Figs. 235, 236, 237). The elbow is held to the side by pinning a strip of compress to the swathe at the elbow and posteriorly (see Fig. 236).

Precautions in Using the Acutely Flexed Position: The arm is inspected each day for the first week. It is necessary to note

whether with the increase in the swelling the flexion of the arm should be diminished, and whether with diminution in the swelling flexion may be increased with safety. The radial pulse should be felt as the flexion is diminished, so as to avoid compression of the vessels at the bend of the elbow. There should be no pain associated with this acutely flexed position. A certain amount of discomfort may be complained of. Real pain will be indicative of too great pressure, and if it is present, the forearm should be less acutely flexed. Chafing should be looked for at the bend of

Fig. 239.—Fracture of the elbow. Application of the internal right-angle splint. First strap already applied. Manner of holding splint and arm as the forearm is flexed up to the splint (see Fig. 240).

the elbow, under the forearm and hand and on the chest, where, if necessary, fresh powder and compress cloth should be placed. The edge of the adhesive plaster may cause chafing of the skin upon the posterior surface of the forearm and upper arm. It may be necessary to place beneath the plaster small, carefully folded compresses of cotton cloth to protect the skin (see Fig. 235).

Later, in changing the adhesive plaster, the skin may be washed with alcohol and then with soap and water, to the great comfort of the patient. The alcohol removes all adhesive plaster sticking

to the skin. If the adhesive plaster chafes the skin, as it so often does in children, it will be necessary to place a bit of gauze under the adhesive-plaster strips, leaving enough of the sticky side of the plaster uncovered to catch the skin and thus keep it from slipping entirely loose. The carrying angle of the arm will be preserved if the fragments are approximately reduced; it can not be maintained otherwise. The acutely flexed position reduces the fragments in the fractures under consideration; therefore it will preserve the carrying angle.

Transverse Fracture of the Shaft above the Condyles.—There is

Fig. 240.—Fracture of the elbow. Application of the internal angular splint. Placing second strap. The angle of the splint is crowded into the bend of the elbow (see Fig. 239).

usually an overlapping of the fragments. This is evident in the backward displacement of the lower fragment and forearm and in the forward displacement of the upper fragment.

It will be necessary in order to effect reduction of this fracture to make, with the aid of an assistant, countertraction and pressure backward upon the upper fragment while traction and a forward pull are made upon the lower fragment by grasping the arm above the condyles (see Fig. 233). The internal right-angle splint will best hold this fracture, for it exerts continuous pressure backward upon the upper fragment and prevents displacement (see Figs. 239, 240). It is padded with sheet wadding and applied as illus-

trated. Two straps are needed upon the forearm to hold this splint in good position (see Figs. 241, 242). The strap at the wrist should be so applied that there is no pressure upon the styloid process of the ulna. Long-continued pressure upon this bony process would cause a pressure sore. In applying the adhesive plaster it is wise to apply it so loosely that there is no undue pressure upon the arm, which might retard the circulation. The arm is then covered with a roller bandage of sheet wadding, over which is placed a roller bandage of cheese-cloth. This should be applied smoothly and firmly from the hand to the upper end of the splint.

Fig. 241.—Two straps insufficient to hold elbow in internal right-angle splint. Splint has slipped away from the bend of the elbow.

Fig. 242.—Third strap is necessary to hold the splint close to the flexed elbow.

As the swelling about the elbow begins to subside, pads of cotton cloth (compress cloth) may be placed at each side of the olecranon below each condyle. The pressure of a frequently renewed bandage on these pads will hasten the disappearance of the swelling. It is important to avoid the forward and backward deformity in treating this fracture (see Figs. 243, 244, 245).

Dislocation of Both Bones of the Forearm Backward.—If there is no tendency to displacement after reduction is accomplished, the right-angle position with internal splint is the best treatment. If, on the other hand, there is a tendency to displacement, the acutely flexed position will be the best for the arm because in

case the coronoid process is broken it will insure its close approximation to the ulna.

Separation of the lower epiphysis of the humerus will be best treated in the right-angle position, the same as a fracture of the humerus above the condyles (see Figs. 223 and 225).

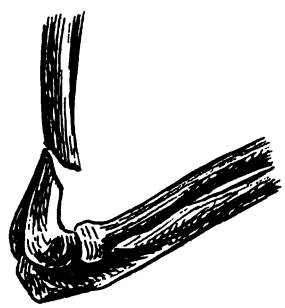

Fig. 243.—Supracondyloid fracture. Obliquity of the line of fracture from behind downward and forward. Diagram showing anterior deformity with elbow flexed.

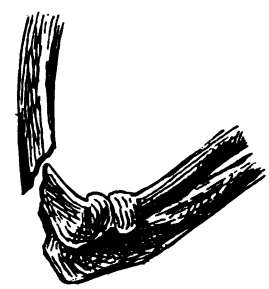

Fig. 244.—Supracondyloid fracture. Obliquity of the line of fracture from above downward and backward. Diagram showing posterior deformity if acute flexion of forearm is attempted.

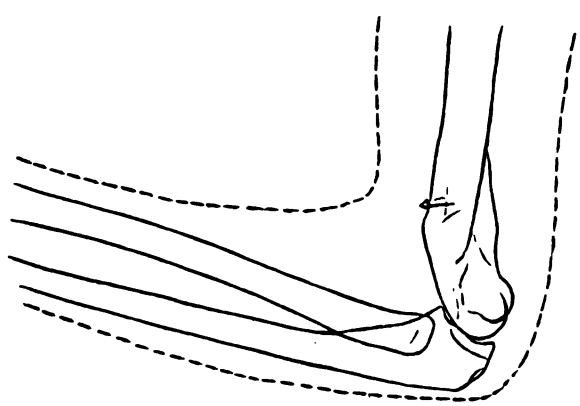

Fig. 245.—Supracondyloid fracture with slight anterior displacement, wired. Recovery, with slight anterior bending of fragments. Wire seen *in situ* (X-ray tracing. Massachusetts General Hospital, 1077).

Fracture of the neck of the radius is best treated by the internal right-angle splint.

Fracture of the olecranon is discussed elsewhere.

The After-care of Injuries to the Elbow.—The reapplying of splints and of apparatus should be done often enough to be sure

that they are efficient, and that there is no undue swelling or pressure upon the arm. Rebandaging the hand and the arm each day, if the internal angular splint is used, is important. All apparatus should be removed at least once a week, and carefully inspected twice during this interval. Passive motion should be instituted late rather than early. In most instances it will be wise to delay passive motion until union is firm—from the fourth to the sixth week. It should be of the gentlest sort; passive motion that is painful does harm.

Massage to the hand, wrist, forearm, elbow, and upper arm, after the primary swelling has begun to subside, is of great value. It should be given at first without disturbing the apparatus and the retentive adhesive plaster. Given every other day, it will accomplish considerable in maintaining the integrity of the muscles of the part. The employment of a professional masseuse is not always necessary. The physician should give the massage or instruct a competent person how to give it.

Omission of Splint or Retentive Apparatus: This should be tentative and gradual after union is known to be firm—in the fifth or sixth week. The arm should be allowed in a sling without the splint for an hour and then the splint applied. The following day a longer interval is granted without the splint. Gradually, the splint is removed entirely. A snugly fitting bandage will often prove comfortable as a support on first leaving off the splint. Passive motion, massage, and active use of the arm will now assist in regaining the use of the joint. At this stage the carrying of dumb-bells, pails or baskets filled with sand, and the doing of certain gymnastic movements with the injured arm will be of material aid. All violent exercise of the part is to be avoided. That amount of exercise may be allowed that leaves the arm moderately tired. A fatigue that is not recovered from within a half-hour's rest is excessive.

The Prognosis.—Up to the time of the present introduction of the acutely flexed position in the treatment of fractures at the elbow, the movement most easily lost and with greatest difficulty regained was that of flexion. By the use of the acutely flexed position in suitable cases the prognosis has improved remarkably in this respect. Now all of flexion is ordinarily preserved, and

the more easily acquired extension is obtained as usual, so that the prognosis as to motion in these cases is good. Although anatomically perfect results are not always obtained, most fractures of this region recover with a useful arm. These fractures of the elbow region should be kept under observation for at least four months. It is wise to treat such cases until all that can be achieved toward a restoration of function has been accomplished.

At the time of the first examination of the elbow the nature of

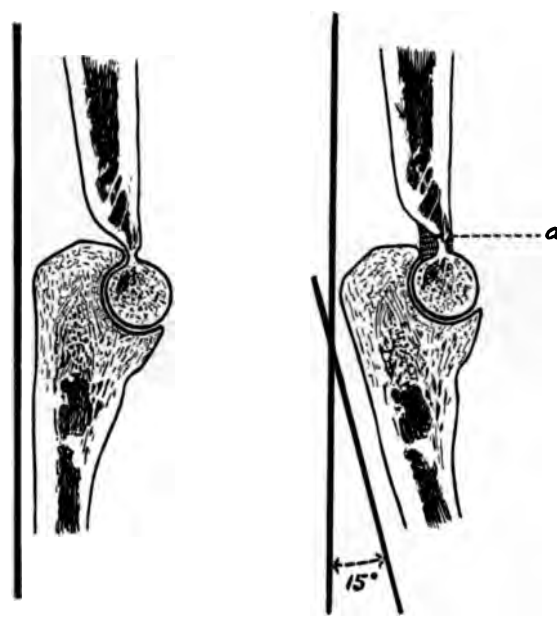

Fig. 246.—Diagram to show the amount of the limitation of extension that may be caused by very moderate callus (*a*) in the olecranon fossa, without displacement of fragments (median section of dry bones).

the injury and its seriousness should be explained carefully to the patient or his friends. A guarded outlook should be expressed, particularly with reference to the function of the joint. Some limitation of motion may exist after all that is possible has been done (see Fig. 246). How much limitation of motion will exist it is impossible to state. There may be none whatever. The patient and his friends should be encouraged with the statement that just as great usefulness of the elbow-joint will be ob-

tained as is consistent with the character of the injury. The importance of the injury demands of every physician a painstaking anatomical examination with the aid of an anesthetic, careful attention to minute details in the initial treatment, and intelligent solicitude in the after-care of all traumatisms to the elbow-joint.

CHAPTER X

FRACTURES OF THE BONES OF THE FOREARM

FRACTURES OF BOTH RADIUS AND ULNA

THE most common seats of fracture are in either the middle or lower thirds of the bones. The fracture of the radius is often a little higher than the fracture of the ulna (see Figs. 247–251 inclusive).

Symptoms.—The arm can not be used without pain. In a muscular or fat arm with little separation of the fragments there may be no deformity excepting the localized swelling of the seat of fracture. Deformity will be determined by the displacement of the bones. If the seat of fracture is not obvious, the forearm should be grasped by the two hands (see Fig. 252) and gentle but firm movement attempted, to determine the presence of abnormal motion and crepitus. Motion should be attempted in all directions, for the bones may be fractured and yet be locked when movement is made in one direction only.

Incomplete or Greenstick Fracture of the Bones of the Forearm (see Figs. 253, 254, 255).—This is a partial break across the bone, with bending at the seat of fracture. In children between the ages of two and fourteen years injury to the bones of the forearm results usually in a greenstick fracture. Either one or both bones may be broken. One bone may be completely fractured while the other is incompletely broken.

Deformity is very evident. Pain and tenderness at the seat of fracture are present. Crepitus is absent unless one bone is completely fractured. Children having these fractures are often seen a week or two after the injury; they are said to have "sprained the arm" and "are unable to use it well at the present time." Careful inspection will detect the characteristic bowing at the seat of a greenstick fracture. Slight callus will be present if a little time has elapsed since the injury.

Fig. 247.—Case: Child. Fracture of the neck of the radius.

Fracture of the Neck and Head of the Radius.—These fractures are rarely unassociated with lesions of the humerus and ulna. A fracture of the external condyle of the humerus and backward dislocation of both bones of the forearm have been noted with these fractures.

Local swelling and tenderness over the radial head and neck are apparent. The swelling is greater than in a simple subluxation of the radius, and is limited to the upper third of the radial side of the forearm. There is pronation of the forearm. Flexion and extension, in the absence of associated lesions such as fracture of

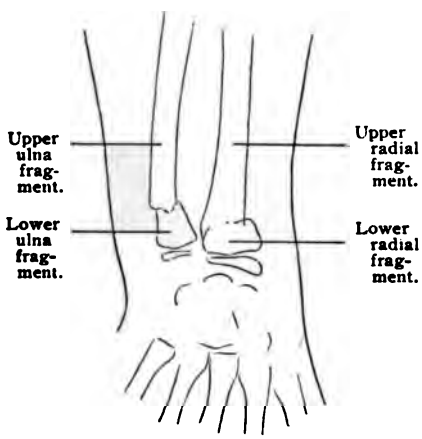

Fig. 248.—Fracture of both bones of the forearm near the wrist, at about the same level. Radial displacement of whole hand. Deformity of wrist resembling somewhat that of Colles' fracture (X-ray tracing).

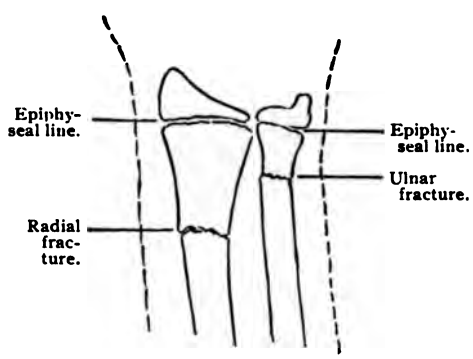

Fig. 249.—Fracture of both bones of the forearm near the wrist; different levels. No displacement in either place (Massachusetts General Hospital, 1384. X-ray tracing).

the external condyle of the humerus, are possible. Attempted rotation of the radius,—that is, supination,—elicits pain, muscular spasm, and perhaps crepitus. The head of the bone does not usually rotate with the shaft, at least not as it does normally. Subluxation of the radial head and fracture of the external condyle of the humerus are the two lesions with which a fracture of the radial neck and head is most often confused. The points of difference have been indicated. The X-ray is here of decided value. It is often difficult on account of overlying muscle and swelling of the soft parts to palpate the head of the radius with

accuracy. Pressure over the shaft of the radius at about its middle elicits pain, if a fracture of the radial neck be present, at the seat of fracture. An X-ray of the elbow will determine a diagnosis.

Fracture of the Shaft of the Radius (see Figs. 259–264 inclusive).—This is usually caused by direct violence. The fracture occurring at any part of the shaft presents no unusual symptoms. The head of the bone does not rotate with the shaft unless the fragments are locked. Abnormal mobility, pain, and crepitus are

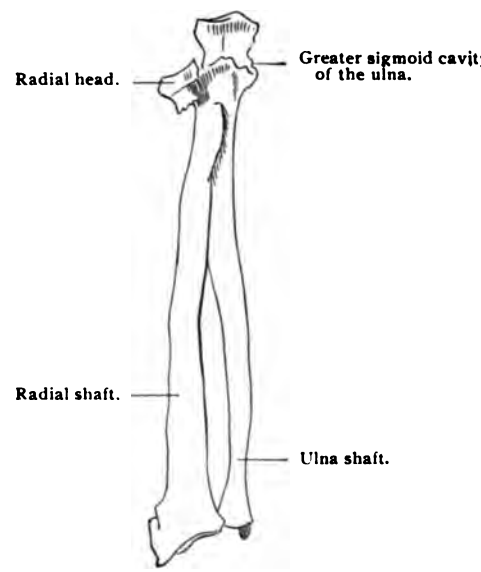

Fig. 250.—Common displacement in fracture of the neck of the radius (after Mouchet).

present. The displacements vary with the situation of the fracture. Pronation and supination will be limited and painful. This fracture has been mistaken for a subluxation of the radial head. A fracture of the radial shaft at the junction of the lower and middle thirds will sometimes suggest very plainly the lateral deformity in a Colles' fracture, the prominent ulna and apparently shortened styloid process of the radius being in evidence. If the fracture occurs in the upper third of the bone, the displacement of the upper fragment will be considerable.

Separation of the Lower Epiphysis of the Radius (see Figs.

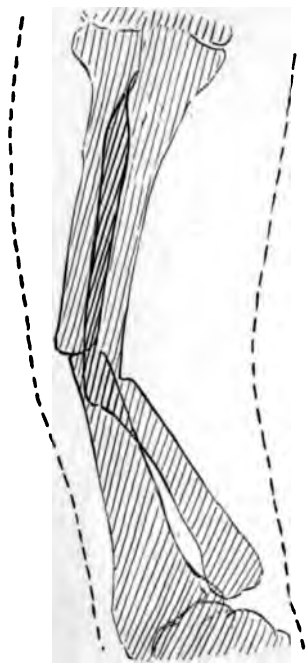

Fig. 251.—Fracture of both bones of the forearm at the middle, showing falling together of broken ends (X-ray tracing).

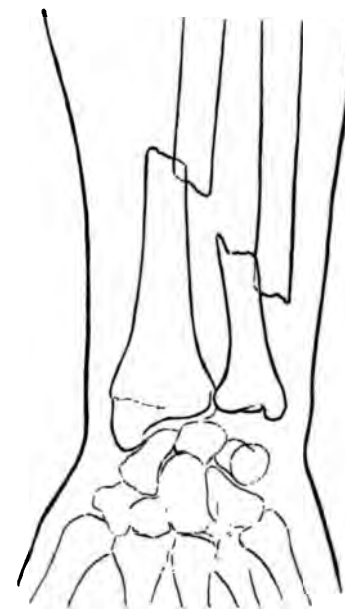

Fig. 252.—Fracture of both bones of the forearm, showing differences in level and that the seat of fracture is in the lower third of bones.

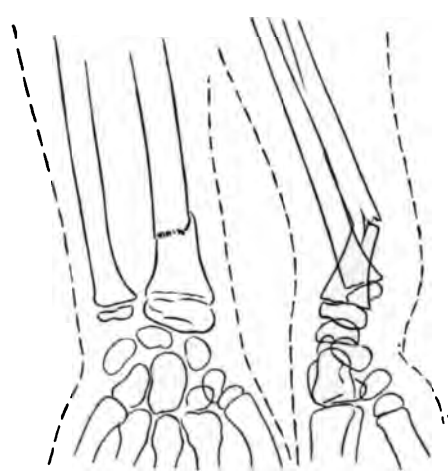

Fig. 253.—Fracture of radius alone. Slight lateral, considerable anteroposterior, displacement. The fallacy of depending upon an X-ray taken in one plane only is here illustrated (X-ray tracing).

265, 266).—The lower radial epiphysis unites to the shaft of the bone at the twentieth year. Previous to this age a separation of the epiphysis is not at all uncommon. Many cases of separation of this epiphysis are thought to be Colles' fractures, and they are treated as such. The treatment of a Colles' fracture may present considerable difficulties. Ordinarily the treatment of a separation of this epiphysis is simple. There is little difficulty in maintaining the fragments in position in separation of the epiphysis. The epiphyseal separation requires a short time in splints.

A soft, cartilaginous crepitus is felt. There are usually less swelling and less pain than in a Colles' fracture. The deformity

Fig. 254.—Manner of grasping forearm to detect the presence of fracture. Note the firmness of grasp.

is quite constant: a prominence near the carpus on the dorsum of the wrist and a prominence higher up on the palmar surface of the wrist. There is almost no tendency to reproduction of the deformity after it is once reduced.

Fracture of the shaft of the ulna occurs usually because of a direct blow received upon the arm raised for protection. It is more uncommon than fracture of the radius (see Figs. 268, 269).

Localized tenderness, pain upon attempting to use the forearm, obscure discomfort in the arm after an injury—these may be the only signs of fracture. There is no general swelling of the forearm. Ordinarily, there will be very little displacement, be-

cause the radius serves as a splint for the broken bone. Crepitus may be detected if the ulna is grasped between the fingers, placed either side of the fracture, and motion is attempted. The shaft of the ulna being subcutaneous throughout its entire extent, the tender seat of fracture can be easily determined (see Fig. 270).

Fig. 255. — Greenstick fracture of both bones of the forearm (diagram).

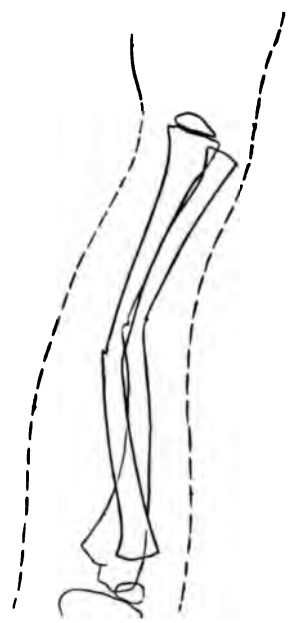

Fig. 256.—Greenstick fracture of both bones of the forearm. Notice characteristic deformity (X-ray tracing).

Fig. 257.—Complete fracture of ulna and greenstick fracture of radius (X-ray tracing).

Fracture of the coronoid process of the ulna is associated with backward dislocation of the ulna. It is a rare accident. A very small fragment is broken off, and it is not much displaced. If in any dislocation of the forearm backward recurrence of the deformity after reduction occurs readily, a fracture of the coro-

Fig. 258.—Right forearm bones in semipronation from front and inner side, showing epiphyses; child of eight years (Warren Museum, specimen 334).

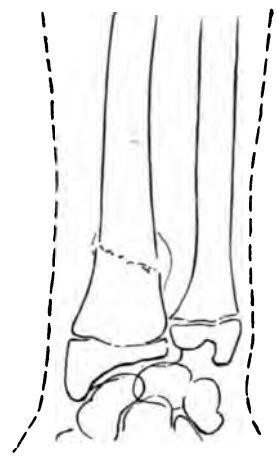

Fig. 259.—Fracture of radius. Slight lateral displacement. See figure 260 (X-ray tracing).

Fig. 260.—Fracture of radius. Slight anteroposterior displacement (same as Fig. 259, X-ray tracing).

Fig. 261.—Comminuted fracture of radius, low down, and of ulnar styloid (X-ray tracing).

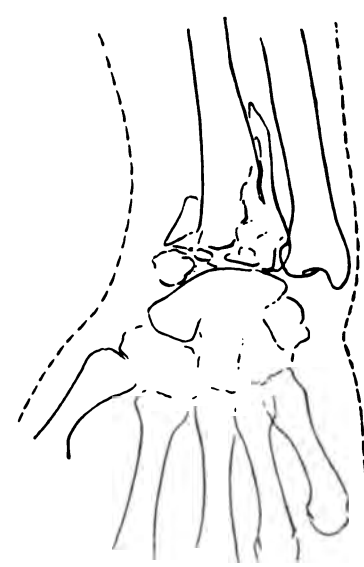

Fig. 262.—To illustrate so great damage to lower end of radius that complete restoration to normal is impossible (X-ray tracing).

Fig. 263.—Fracture of both bones of the forearm. Notice displacement and overlapping of fragments. Notice epiphysis of lower end of radius and ulna. Anteroposterior view.

Fig. 264.—Same as figure 263. Lateral view. Notice displacement of fragments and overlapping. This overlapping is very difficult to overcome.

noid should be suspected. This will be confirmed by the discovery of a small hard mass in front of the elbow-joint just above the insertion of the brachialis anticus muscle; roughly, a finger-breadth above the bend of the elbow. This small hard mass may give crepitus upon being manipulated. It is very difficult to detect this fragment of the coronoid process even under the most favorable conditions. The Röntgen ray may discover it.

Treatment of Fractures of the Forearm.—The objects of

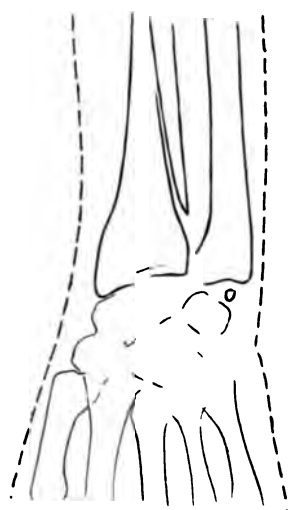

Fig. 265.—Oblique fracture of the shaft of the radius.

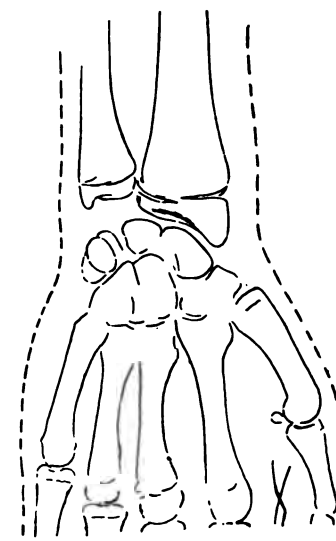

Fig. 266.—Separation of the lower epiphysis of the radius without displacement.

treatment are to prevent permanent deformity and to preserve the movements of pronation and supination.

Fractures of Both Radius and Ulna.—All fractures of the forearm attended with overriding or angular displacement that do not yield readily to traction, countertraction, and pressure should be reduced under complete anesthesia. While an assistant makes countertraction upon the upper part of the forearm the surgeon, holding the lower end of the limb, makes strong, even traction, at the same time pressing the bones into position. When the angular deformity is corrected, the forearm should be strongly supinated. This supination will assist in preventing the bones becoming locked close together (see Fig. 273).

In order to immobilize a fracture of the shaft of a bone not only must the fracture itself be held firmly, but the joint immediately above and below the seat of fracture must be immovably fixed. If the arm is seen immediately after the accident, and the soft parts are not evidently bruised, and there is little swelling, a plaster-of-Paris splint should be applied. It should extend from the axilla above to the metacarpophalangeal joints below. The arm should be flexed to a right angle and the forearm semi-supinated (thumb upward) (see Fig. 274).

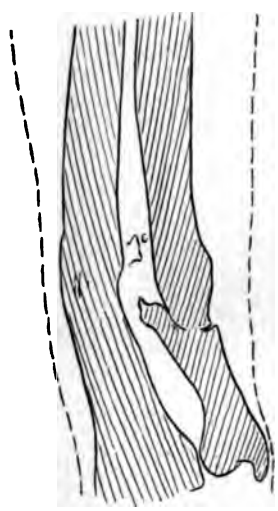

Fig. 267.—Old fracture of both bones of the forearm; pseudoarthrosis of ulna. Radial fracture has united (X-ray tracing).

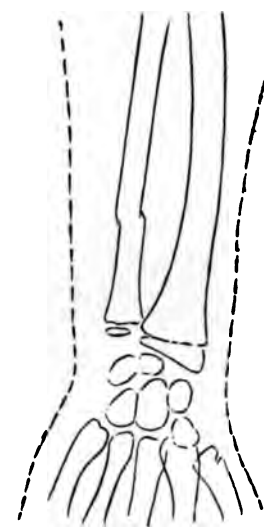

Fig. 268.—Fracture of the shaft of the ulna. Slight lateral displacement. Localized tenderness clinically the only symptom (Massachusetts General Hospital, 1036. X-ray tracing).

Precautions in Using the Plaster-of-Paris Splint: The forearm should be held in the corrected position by an assistant throughout the application of the plaster bandages. Two assistants will facilitate the putting on of the plaster. The forearm and upper arm should be thinly covered with one layer of sheet wadding; cotton wadding should not be used. No salt should be used in the water in which the plaster bandages are dipped. It will require about three or four bandages, three inches wide and four yards long, for an ordinary muscular adult arm. The plaster

roller should be applied deliberately, evenly, and snugly from the metacarpophalangeal joints to the axilla. Great lateral compression of the arm will be avoided if the bandage is applied as directed. There will be insufficient compression to crowd the bones together and so produce deformity.

After-care of the Plaster Splints: When the plaster has set firmly, the assistant may place the forearm in a sling of comfortable height to support the arm. Inspection of the fingers will determine the condition of the circulation in the limb. If there is too great pressure, if the splint is too tight, a blueness will appear,

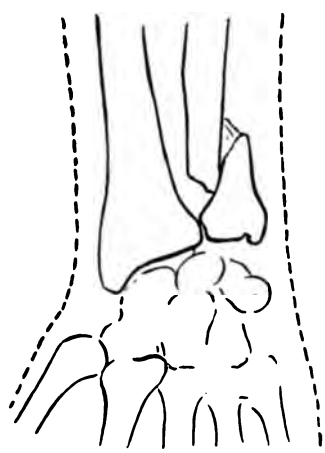

Fig. 269.—Fracture of ulna, low down, with considerable lateral displacement and shortening of shaft (X-ray tracing. Massachusetts General Hospital, 5693).

Fig. 270.—Partial fracture of ulna. T-shaped line of the fracture (Warren Museum, 3722).

indicating a sluggishness in the circulation. If this sign appears, the splint should immediately be split from axilla to hand by a knife. This will relieve the circulation. Ordinarily, there is no difficulty of this sort. The patient should be seen each day for the first week after the dressing is put on. Inquiry should be made for pain and throbbing in the arm and sleeplessness, which are evidences of too great pressure. If the arm is doing well, the splint should cause no discomfort. After one week the plaster splint should be removed, for the swelling of the arm will have diminished and the splint will have become loosened. Unless

this loosening is corrected, an opportunity for deformity to occur will then exist. Either a new plaster should be applied or the old splint, if suitable, should be reapplied and tightened by a bandage. If the splint is too large, it may be made smaller by removing a strip of plaster the entire length of the splint. The edges of the cut plaster should be bound with strips of adhesive

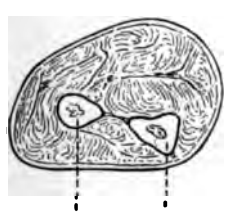

Fig. 271.—Showing distance between bones and their relation to mass of soft parts. Median section of forearm (from frozen section by Dwight).

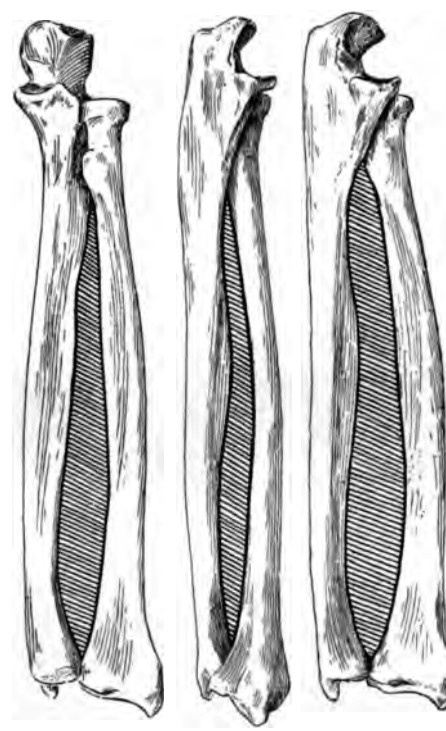

Fig. 272.—Variations in the shape and width of the interosseous space between radius and ulna when the forearm is supinated, pronated, and semipronated. Semipronation presents the widest interosseous space (diagram).

plaster to prevent chafing of the skin and crumbling of the plaster. The position of the bones at the seat of fracture should be noted. The degree of movement possible at the seat of fracture should be noted. At the end of each week the splints should be removed. After about three weeks, when union is well advanced, the plaster splint may be cut off below the elbow and the upper part dis-

carded, or a posterior splint of wood may be applied for lightness and convenience.

If the force was a direct violence and there is injury to the soft parts, if the swelling is considerable and is likely to be greater, it will be best to use palmar and dorsal splints of wood upon the fore-

Fig. 273.—Fracture of the forearm low down, or Colles' fracture. Anterior and posterior splints, three straps, radial pad. Anterior splint cut out to fit thenar eminence.

Fig. 274.—Fracture of the forearm. Manner of holding arm and of applying the adhesive-plaster straps. Posterior splint of splint wood.

arm and an internal right-angle splint at the elbow. The forearm is held in the position of semisupination. The maximum swelling occurs within the first forty-eight hours—barring, of course, inflammatory disturbances, which are not to be considered here. The splints should be of thin splint wood, which is stiff

enough not to yield to ordinary pressure. In width they should be one-fourth of an inch wider than the forearm. The posterior splint should extend from just above the middle of the forearm to the metacarpophalangeal joints. The anterior splint should extend from the same point on the forearm to the middle of the palm of the hand (see Fig. 273). The palmar splint is cut out on the thumb side, so as to avoid pressure on the thenar eminence. These two splints are padded with evenly folded sheet wadding

Fig. 275.—Fracture of both bones of the forearm. Proper position of arm in sling. Note hand is unsupported by sling, and arm rests on ulnar side. Notice height of arm.

no wider than the splints. About three or four thicknesses of the sheet wadding will be necessary. The posterior splint is padded alike through its whole extent. The anterior splint is so padded as to conform to the irregularities of the anterior surface of the forearm, particularly at the radial side near the wrist. The internal right-angle splint is padded evenly with four thicknesses of sheet wadding. It overlaps the wooden splints, and extends up to the axilla. It immobilizes the elbow-joint.

The Application of the Splints: The forearm is held flexed at

a right angle and semisupinated and steadied by an assistant. The posterior and then the anterior splints are applied to the forearm. Three straps of adhesive plaster, two inches broad, are then applied—one at the upper ends of the splints, one at the wrist, and the third across the palm of the hand and around the posterior splint only. These straps should simply steady the splints snugly in position (see Fig. 274). The bandage is next applied, and it is by this that pressure is exerted upon the arm. There should be some spring left upon pressing the splints together after the bandage is applied. If there is none remaining, too

Fig. 276.—Fracture of both bones of the forearm. Ulnar view of the anterior and posterior splints. Note length of splints and position of straps. Straps of the internal right-angle splint, 3 and 4.

great pressure will be made on the arm and the circulation will be interfered with. The arm is placed in a sling of comfortable height (see Fig. 275).

If the fracture of the forearm is above the middle of the bones, the tin internal right-angle splint should be used to immobilize the elbow-joint. This should be applied after the wooden splints are in place and while the arm is semisupinated. A bandage is then placed over both wooden and tin splints (see Figs. 276, 277, 278).

After-care of Wooden and Tin Splints: The patient should be

seen every day for two or three days after the fracture. The splints should be readjusted and applied more snugly by a fresh bandage. The comfort of the patient should be considered; any complaint on the part of a sensible individual should be inquired into. If the apparatus is applied with the bones in approximately normal position, there should be no subsequent discomfort. All splints should be removed at least twice a week throughout active treatment, and the presence of deformity noted and corrected. After the first week or week and a half, the swelling having sub-

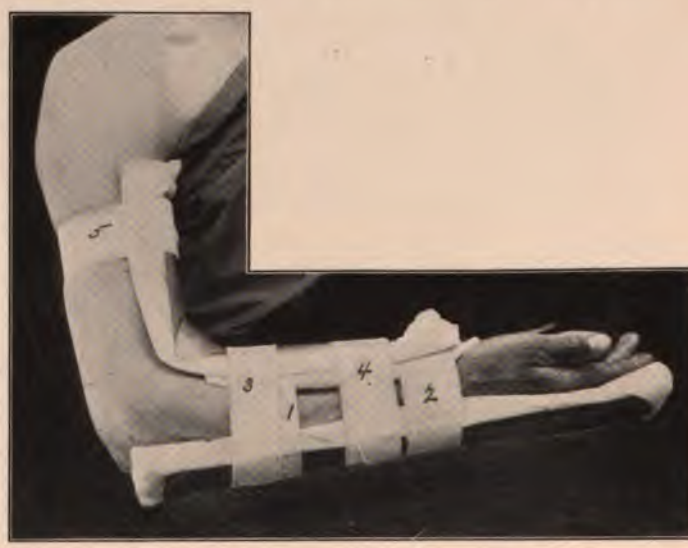

Fig. 277.—Fracture of the bones of forearm. Forearm supinated. Anterior and posterior splints and tin internal angular splints. 1 and 2, Straps holding anterior and posterior splints; 3, 4, and 5, straps holding internal right-angle splint.

sided, it is often advantageous to apply in place of these splints of wood the plaster-of-Paris splint, which has been described (see p. 202).

Fracture of the head and neck of the radius and fracture of the coronoid process of the ulna should be treated by the internal right-angle splint with the forearm semipronated—that is, with the thumb up (see Fig. 278).

Fracture of the shaft of the radius, if above the middle of the bone, should be treated by the anterior and posterior wooden splints and

the internal right-angle splint. If below the middle of the bone, the internal right-angle splint may be omitted, although it may be well to retain it in most instances. If the fracture is in the upper third of the bone, it may be impossible to correct the deformity without making an open fracture and suturing the fragments together. It may be possible to approximate the fragments by putting the forearm in a position of semipronation. No special splint is necessary to maintain this position; the two wooden anterior and posterior splints and the tin internal right-angle splint fulfil all the indications.

Separation of the lower radial epiphysis is treated by anterior and

Fig. 278.—Fracture of both bones of the forearm. Anterior and posterior splints and tin internal right-angle splint immobilizing elbow-joint. Note arm in semipronation, "thumb up"; position of straps; padding of internal right-angle splint.

posterior splints, similarly to the treatment of a Colles' fracture (see Fig. 273).

Fracture of the shaft of the ulna should be treated as fractures of the shaft of the radius are treated.

How long should splints be kept on in fractures of the forearm? Until union is firm enough between the fragments, so that firm pressure does not cause motion. When the fracture is firm, ordinarily after about three weeks and a half, the anterior and internal angular splints may be omitted, the posterior splint alone being left in place. If the posterior splint of wood is used, a broad (four-inch) strap of adhesive plaster, in addition to the two ordinary

straps at each end of the splint, should be placed at the seat of fracture and a gauze bandage applied over all. At the end of the fourth or fifth week all splints should be omitted. Continual watchfulness is demanded in order that bowing at the seat of fracture may not take place. The application of the sling after the omission of splints should be carefully made to avoid backward

Fig. 279.—Application of sling. Proper position of triangular bandage in first step. 2 is carried over right shoulder; 1 drops over left shoulder; 1 and 2 are fastened behind the neck; 3 is brought forward and pinned, as shown in figure 280.

bowing of the bones. A laboring man should not go to work for at least from four to six weeks after leaving off splints. A return to work too early causes bowing of the fracture and pain in the arm.

Massage and passive motion should be employed as soon as union is firm and the anterior and internal angular splints have been removed. Massage may be given at first without removing

the arm from the splint. Convalescence will proceed more rapidly in consequence of massage.

When will the arm be restored to normal usefulness? It is impossible to answer this question accurately. The conditions in each individual instance of fracture are so variable that no general statement can be made that will more than indicate the probable time of convalescence. It may be fairly stated that in an uncomplicated fracture of both bones of the forearm the arm

Fig. 280.—Application of sling. Final position of arm. Two ends tied behind neck and the third end pinned.

will be useful for working in from two to three months from the time of fracture.

The treatment of open fractures of the forearm is best conducted by methods described under open fractures of the leg: briefly, absolute cleanliness, suturing of bones, sterile dressing, immobilization of the part.

Prognosis and Result of Treatment.—There may be some limitation of supination and pronation immediately after the

splints are removed. As the callus diminishes and with persistent movements of the arm in ordinary use this limitation should diminish, and in some instances entirely disappear. If the fracture is in the upper or lower thirds of the bones, the limitation of motion will often be greater than when the fracture is at the middle of the bones. The interosseous space is greatest at the middle of the shafts (see Fig. 272); consequently, callus at this point is less likely to impair motion of the forearm. The arm

Fig. 281.—Compound fracture and dislocation at the wrist. Hand saved.

should be straight. Movements of the wrist and elbow should be perfectly normal.

Nonunion of Fractures.—If after the usual time has elapsed for a fracture to have united firmly it has failed of union, delayed union is said to exist. If after a longer time no union occurs, nonunion is said to exist. A case of delayed union may result in nonunion or it may become united. The term nonunion does not, however, necessarily imply that no union exists between the bones, but simply that bony union does not exist. In cases of so-called nonunion fibrous union is often present. The causes of nonunion are local and general. Of the local causes the commonest

is the interposition of some soft tissue, such as torn periosteum, strips of fascia or muscle, between the fragments. A wide separation and imperfect immobilization of the fragments are also factors in the occurrence of nonunion. Of the general causes it is thought that syphilis, pregnancy, prolonged lactation, the wasting diseases, rachitis, and the acute febrile diseases may contribute something toward nonunion.

The constitutional treatment of nonunion is of primary importance, together with reduction and absolute immobilization of the fragments. If these measures fail after a fair trial, a rubbing of

Fig. 282.—Method of applying force in completing a greenstick fracture of the forearm. The force is applied in the direction of the original force (diagram).

the ends of the fractured bones together and then immobilizing them is sometimes effective. If this fails too, operative measures should be instituted for making the fracture an open one for the removal of any interposed tissues. Careful fixation will, after such operative procedure, usually effect union. If for some unremediable constitutional reason union does not result after operation, a splint should be devised to make the damaged part as useful as is compatible with nonunion.

Treatment of Greenstick or Incomplete Fracture of the Bones of the Forearm.—It is impossible to maintain the correction of the deformity if the bones are simply bent back into position. Even

with the greatest care in the use of pads and pressure the deformity will in part reappear. It is necessary, therefore, to administer an anesthetic, and to make a complete fracture of the greenstick fracture. This done, the arm is set as in a complete fracture. The best method of refracturing the greenstick fracture is to bend the arm with the two hands in the direction of the original force (see Fig. 282).

The anterior and posterior wooden splints may be used with satisfaction. Ordinarily, the plaster-of-Paris splint as applied in complete fractures is the best apparatus. Union in children after fracture is more rapid than in adults. At the end of two weeks union will be found firm. It is well not to omit all apparatus in a child until four weeks have passed. If great caution is needed on account of an extremely active child, the posterior wooden splint should be kept on during the fifth week.

FRACTURES OF THE OLECRANON

The normal anatomical relations of the olecranon should be kept constantly in mind. The insertion of the brachialis anticus muscle is into the front and lower part or base of the coronoid process of the ulna. The insertion of the triceps muscle is into the posterior part of the upper surface of the olecranon and into the fascia of the posterior surface of the forearm. The small epiphysis of the olecranon unites to the shaft about the sixteenth year. A direct blow upon the olecranon together with violent muscular contraction of the triceps will produce the fracture. The fracture is usually transverse. A complete transverse fracture of the olecranon always opens the elbow-joint (see Fig. 283). Some of the varieties of fracture of the olecranon are seen in the accompanying tracings of Röntgen-ray plates (see Figs. 284, 285, 286, 287).

Symptoms.—Inability forcibly to extend the forearm, pain at the seat of fracture, and deformity, provided the fragment is separated from the shaft of the ulna. A depression marks the separation. Very great separation of the fragment is not often present. The interval between the fragments depends upon three conditions: The extent of the facial laceration—if the laceration

is moderate in extent, the interval between the fragments will be slight; if the laceration is extensive, the interval between the

Fig. 283.—Showing relations of olecranon to elbow-joint; practically all fractures are intra-articular.

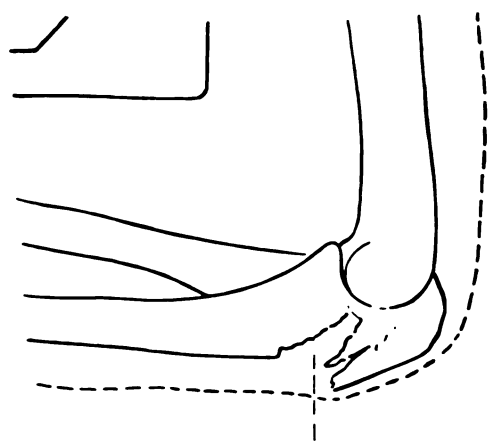

Fig. 284.—Splintered fracture of olecranon without much displacement (Massachusetts General Hospital, 1536. X-ray tracing).

fragments may be great; the position of the arm, whether flexed or extended—if flexed, the separation will be greater than if extended (see Fig. 288); the amount of synovial fluid and blood in

the joint—the greater the amount of fluid, the greater will be the separation of the fragments. The mobility of the fragments of

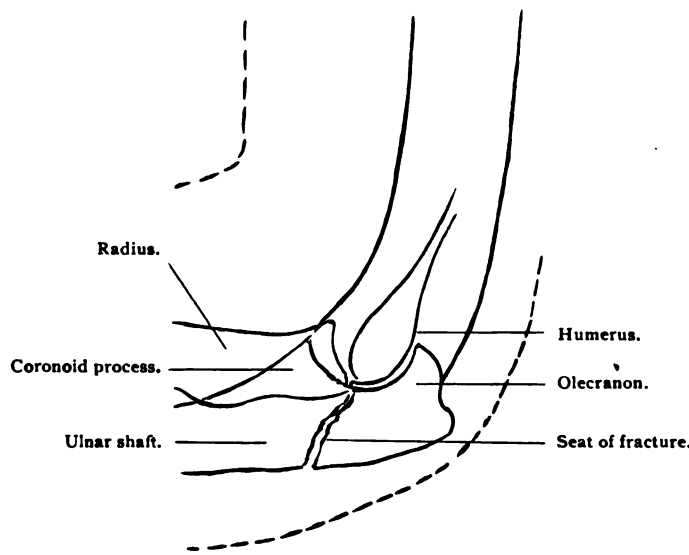

Fig. 285.—Fracture of olecranon. No displacement detected clinically. No symptoms other than local tenderness and slight swelling (X-ray tracing).

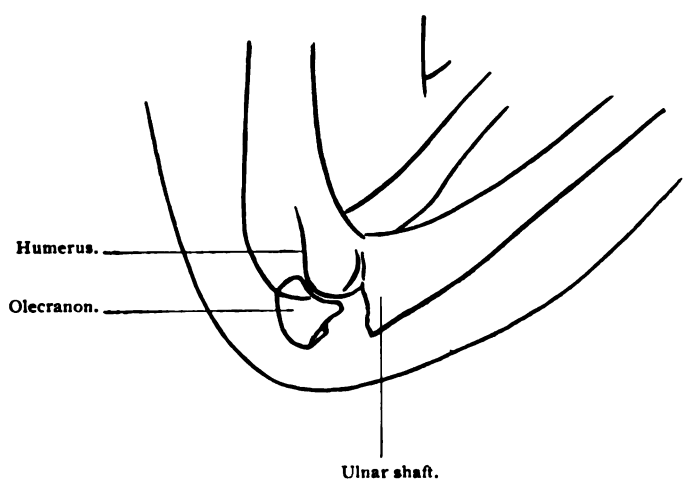

Fig. 286.—Fracture of olecranon; separation of fragments upon flexing forearm (X-ray tracing).

the olecranon is determined by grasping the olecranon firmly and attempting lateral motion (see Fig. 207). Crepitus may thus

be elicited. The general swelling about the elbow will be considerable if the traumatism was severe. There exists a traumatic synovitis of the elbow-joint.

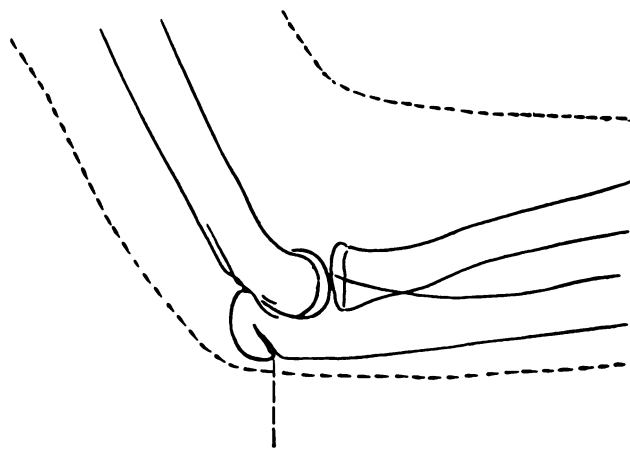

Fig. 287.—Fracture of olecranon at about the epiphyseal line, without opening the elbow-joint (Massachusetts General Hospital, 1172. X-ray tracing).

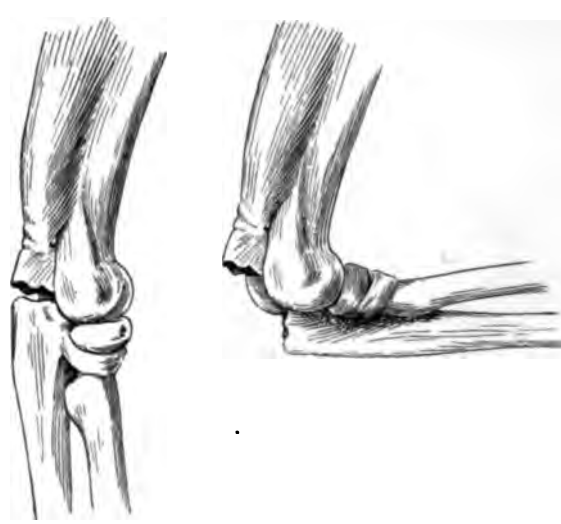

Fig. 288.—Diagrams to illustrate separation of fragment of olecranon by the triceps and in flexion of the elbow.

Treatment.—If there is considerable swelling of the elbow, and if the arm is large and muscular, it is wise to rest the arm for a

few days (at least five or six) upon an internal right-angle splint before putting it up permanently. The swelling will disappear in the mean time, and a more accurate examination of the arm can then be made. If there is little or no separation of the fragments in the right-angle position, the arm may be kept at a right angle. This is doubtless the most comfortable position, and,

Fig. 289.—Fracture of the olecranon. Arm in extension. Long anterior splint. Note pad and strap above olecranon fragment; pad in palm of hand.

under these conditions, certainly is effective. If there is marked separation (half an inch or more), the arm should be extended and this position maintained by a long internal splint (see Fig. 289). This splint, made of splint-wood, should be the width of the arm, and should reach from the anterior axillary margin to the tips of the fingers. This is well padded with sheet wadding at the bend of the elbow (see Fig. 290). The contiguous skin sur-

faces of the fingers are protected from chafing by strips of gauze or compress cloth placed between them, and a pad is put in the palm for comfort (see Fig. 291). The splint is held in position by four straps of adhesive plaster, one placed at either end of the splint and one above and below the elbow-joint. The upper or loose fragment is pushed down toward the shaft of the ulna, and held in

Fig. 290.—Fracture of olecranon. Arm in extension. Note upper and lower straps; oblique olecranon strap; padding of splint.

place by a strap of adhesive plaster carried around the upper side of the olecranon fragment and fastened to the splint lower down. Sheet wadding and gauze roller bandages applied from the fingers to the axilla afford comfort and prevent undue swelling of the hand. Should the separation be so great that reduction of the fragment is unsatisfactory, an incision and suture should be made (see Fig. 291).

Treatment if the Fracture is Open.—The wound should, if necessary, be enlarged to permit of easy inspection of the joint surface. The joint should be thoroughly irrigated with boiled water. The wound of the soft parts should be very thoroughly cleansed by scrubbing with gauze wet in corrosive sublimate solution, 1 : 5000, and then the fragment of the olecranon sutured to the shaft.

Fig. 291.—Fracture of olecranon. Bandage applied to the same case as shown in figures 289, 290. Note protection of fingers from chafing by compress cloth and bandaging of hand.

The After-care.—If the arm has been put up temporarily at a right angle to await the subsidence of the swelling, gentle massage and firm bandaging of the arm, twice daily, until the swelling subsides sufficiently for accurate examination and a more permanent dressing, will be of very great service. The arm should be inspected each day for the first week. Daily massage should be continued not only to the joint region, but to the forearm and

upper arm as well. The straps and bandages should be reapplied as they become too tight or are loosened by the disappearance of the swelling. After about two weeks the position of the forearm may be cautiously changed. The small fragment of the olecranon should be held fixed during the manipulation. If the arm is in the extended position, it should be gradually flexed some five or ten degrees, and returned to the extended position. If the arm is already at a right angle, it should be gradually extended, at first a

Fig. 292.—Method of examination of wrist. Note supination of forearm; position of examining hands and fingers; palpation of the styloid process of the radius and the head of the ulna. The radial styloid is seen to be lower than the head of the ulna.

Fig. 293.—Method of examination of wrist. Note pronation of forearm; position of examining hands and fingers; palpation of styloid processes of radius and ulna. The styloid of the radius is lower than the styloid of the ulna.

few degrees only, and returned to the right-angle position. No pain should be experienced by the passive motion. Painful passive motion is harmful. After a few days of these gentle passive motions it will be wise to alter the angle of the splint so that the arm may rest in the changed position permanently. After about four or five weeks all splints should be omitted. A bandage should be worn after the removal of the splints to afford support to the elbow.

Union of the fragments usually takes place in from three to four weeks. After six weeks to three months the movements of the elbow-joint should be normal. There may remain as a permanent condition slight limitation of extension. The functional usefulness of the elbow depends more upon the approximation of the fragments and less upon the kind of union between them. The union between the fragments is more often ligamentous than bony. The short fibrous union, if of good width,—*i. e.*, if it covers the whole of the broken surface,—is as efficient as a bony union.

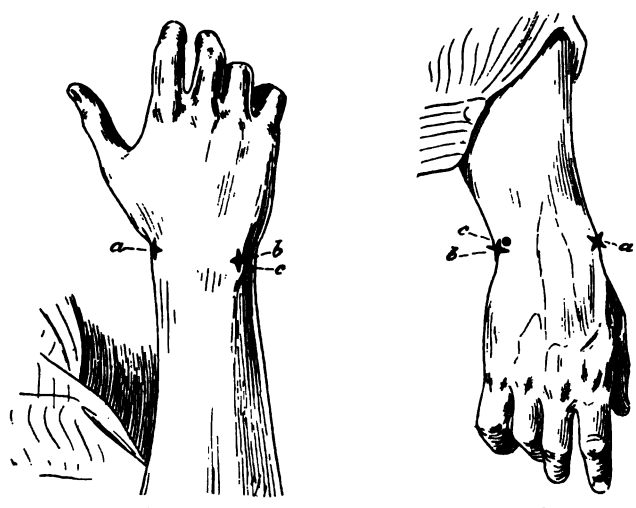

Fig. 294.—*a*, Tip of radius; *b*, styloid process of ulna; *c*, ulnar head. 1. Supination. 2. Pronation. To illustrate that, in comparing the level of the styloid of radius with lower end of ulna, as in figures 292, 293, in supination, 1, the *head* of the ulna is felt, and that in pronation, 2, the *styloid* of the ulna is felt.

A ligamentous union accompanied by great disability in the functional usefulness of the arm should be excised and the bony fragment sutured to the shaft. Suturing of the periosteum and fibrous tissue about the fragments will prove fully as satisfactory in many cases as suturing the bone with silver wire.

Summary: If there is great swelling, delay the application of the permanent splint. Apply internal right-angle splint. Use compression and massage. If there is little or no separation of the fragments, use a right-angle splint. If there is marked sepa-

ration of fragments, use an extended position. If the fracture is open, suture the fragments. If practicable, at the outset, renew the bandage and massage the arm twice daily. After two weeks cautious passive motion should be made daily. After three weeks the angle of the splint should be permanently changed. After four weeks all splints should be removed. After six weeks to three months a useful arm should result.

Tetanus is rarely seen after fracture of bone. It sometimes appears after open fracture. Early amputation and the administration of tetanus antitoxin are the most rational means of treatment in these cases.

COLLES' FRACTURE

A fracture of the lower end of the radius within about one inch of the articular surface is common in adults and is unusual in childhood. A fall upon the outstretched and extended hand is the most frequent cause.

Anatomy.—In a case of traumatism to the wrist the normal

Fig. 295.—Method of examination in a case of injury to the lower end of the radius. Grasping the radius above and below the probable seat of fracture.

anatomical relations should be studied upon the uninjured wrist, and then a careful examination made of the injury. The normal wrist should be looked at from the front and back and from each side with the hand supinated. Anteriorly, the base of the thenar eminence is lower than that of the hypothenar eminence. Posteriorly, on the inner side, the styloid process of the ulna is visible with the marked depression below it. Laterally, on the radial

side, is seen the curve backward on the anterior surface of the radius where the base of the styloid process of the radius joins the shaft. Laterally, upon the ulnar side, are seen not only the styloid of the ulna and its associated depression, but the hollow above the prominence of the hypothenar eminence.

The normal wrist should be felt with the hand both in supination and pronation. With the hand supinated (see Fig. 292) the tip of the styloid process of the radius is found to be lower (nearer

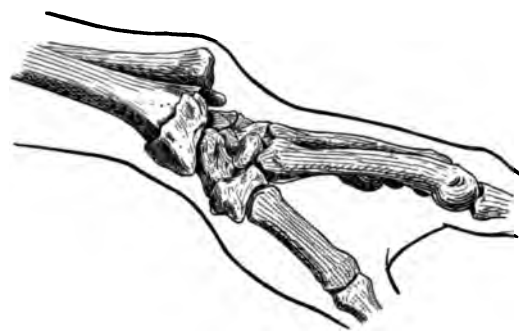

Fig. 296.—Diagram of fracture of base of radius with anterior displacement: "reversed Colles' fracture" (term suggested by Roberts).

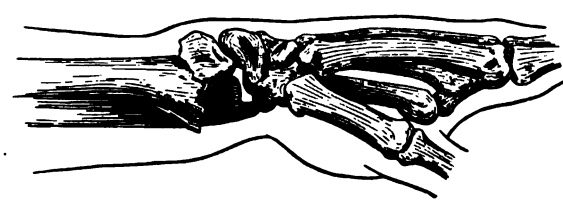

Fig. 297.—Colles' fracture: the common "silver-fork deformity." Note dorsal and palmar prominences (diagram).

the hand) than the head of the ulna. With the hand in pronation (see Fig. 293) the tip of the styloid process of the radius is found to be a little lower (nearer the hand) than the tip of the styloid process of the ulna. To ascertain the relative position of the styloid processes, the injured wrist should be grasped by the two hands and the styloids felt by the tips of the forefingers. The styloid process of the radius and the shaft immediately above it should be carefully palpated to determine the extreme thinness of the bone above the thick styloid process (see Fig. 295). The

width of the wrist between the styloid processes should be measured by means of a tape, or, better, by a pair of calipers.

The movements of the normal wrist and forearm should be carefully observed. Pronation and supination of the forearm and

Fig. 298.—Colles' fracture. Characteristic appearance. Note backward displacement of the hand and wrist. Palmar prominence. Compare with figure 297.

Fig. 299.—Colles' fracture, radial side. Marked crease at base of thumb. Dorsal and palmar prominences.

Fig. 300.—Colles' fracture, ulnar side. Absence of ulna on the dorsum of the wrist; presence anteriorly. Marked crease in front of displaced ulna. Dorsal prominence marked.

flexion, extension, abduction, and adduction of the hand should be carefully performed. These simple observations quickly made upon the normal wrist enable one to establish a standard for comparison with the injured wrist. In every case in which there is a

question of fracture the examination should be made by means of an anesthetic (see Fig. 295). If for sufficient reason complete anesthesia is contraindicated, primary anesthesia will prove to be sufficient. In the larger proportion of cases of Colles' fracture primary anesthesia will be satisfactory for both the examination and the first dressing of the fracture.

Symptoms.—In Colles' fracture the wrist appears unnatural. The thenar eminence of the thumb is higher, nearer to the wrist

Fig. 301. — Colles' fracture, anterior bulging of flexor tendons; absence of dorsal prominence of head of ulna.

Fig. 302.—Colles' fracture. The dorsal prominence is not uncommonly seen after recovery from fracture of the radius when the displaced bones have been but partially reduced. Slight lateral deformity.

Fig. 303.—Colles' fracture. Hand carried to radial side. Prominent ulna anteriorly. Thenar eminence lower than normal.

than usual, as compared with the hypothenar eminence (see Fig. 303). Anteroposterior and lateral deformities are apparent to a greater or less degree. It is said that at times an anterior displacement of the lower fragment occurs, the reverse of the ordinary displacement. It is unusual (see Fig. 296).

The anteroposterior deformity is caused by the projection of the lower end of the upper fragment into the palmar surface of the wrist, pushing the flexor tendons forward (see Fig. 297), and by the projection of the upper end of the lower fragment toward the

dorsal surface of the wrist, pushing the extensor tendons backward. Impaction of the radial fragments may be another factor in the production of the deformity. This deformity is spoken of by the older writers as the silver-fork deformity. The reason is obvious (see Figs. 298, 299, 300, 301, 302).

The lateral deformity (see Fig. 303) is caused by several factors: the impaction of the radial fracture, lateral displacement of the

Fig. 304.—A form of comminution in Colles' fracture. Left wrist from back and below (diagram).

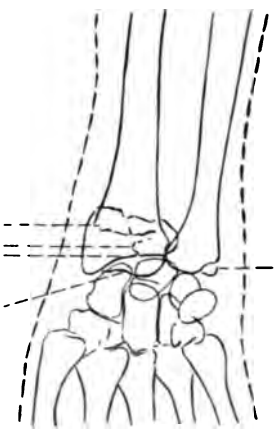

Fig. 305.—Colles' fracture. Anteroposterior view. Slight lateral deformity. Anterior view of figure 306 (Massachusetts General Hospital, 1028. X-ray tracing).

lower fragment, and by rupture of the inferior radio-ulnar ligaments. The abduction of the whole hand, the prominence laterally of the lower end of the ulna, the disappearance of the ulnar head from the dorsum of the wrist, are to be noted. Because of the displacement of the radial lower fragment, the normal relations are no longer maintained between the styloid processes of the radius and ulna. There is a reversal of relations. The radial sty-

loid is higher than usual. It is on the same level with or higher than the head of the ulna.

It is possible to have present a fracture of the lower end of the radius (a Colles' fracture) without any appreciable alteration in the levels of the styloid processes. The existence of the normal

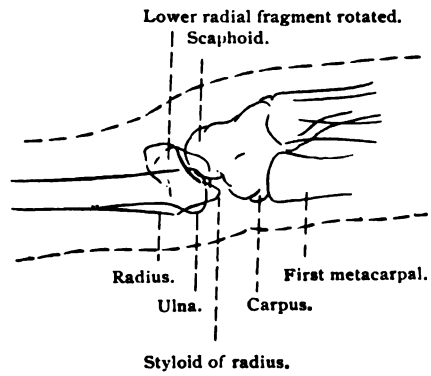

Fig. 306.—Colles' fracture. Lateral view of figure 305. Rotation of lower fragment on transverse axis. Cause of dorsal and palmar deformity evident (X-ray tracing).

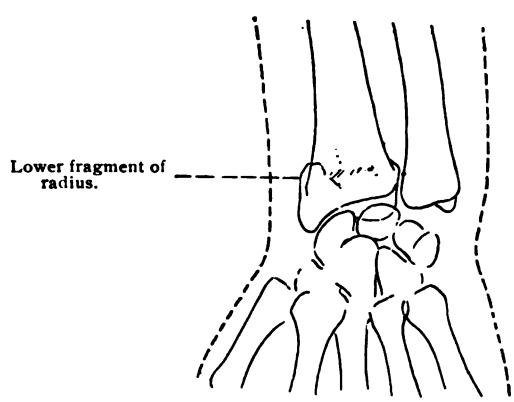

Fig. 307.—Simple transverse Colles' fracture. Anteroposterior view. Lateral deformity (X-ray tracing).

relations of the styloids does not preclude the presence of a fracture.

Direct pressure over the broken bones elicits pain, but crepitus is often undetected until the patient is examined with the aid of an anesthetic. A transverse ridge is sometimes present on the

Fig. 308.—Case same as figure 309. Lateral view.

Fig. 309.—Case: Transverse fracture of the lower end of the radius without much displacement. Anteroposterior view.

posterior and external surface of the radius, corresponding to the line of fracture. In certain cases of Colles' fracture the wrist may not appear very unnatural. There may be scarcely any deformity.

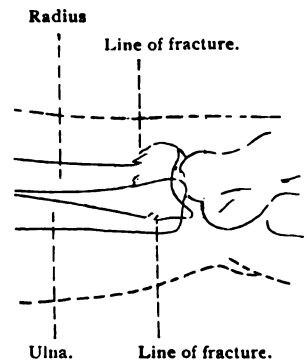

Fig. 310.—Simple transverse Colles' fracture. Lateral view. Same as figure 307 (Massachusetts General Hospital).

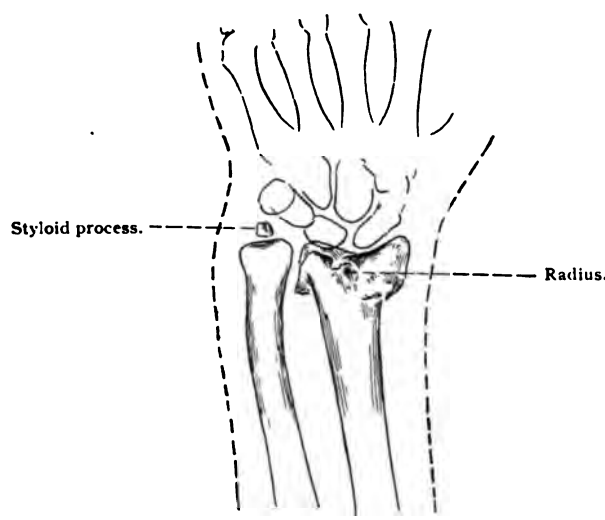

Fig. 311.—Colles' fracture. Fracture of styloid of ulna. A T-fracture into the wrist-joint. Much lateral deformity (X-ray tracing).

The normal relation may be nearly preserved. If there is little displacement of the fragments, it may be difficult to determine the existence of fracture. An appreciation of slight differences

from the normal will, under these circumstances, prove of great value. The Röntgen ray will be of service in this connection.

After injury to the wrist one must consider in the differential diagnosis—

A sprain of the wrist,
Contusion of the bones near the wrist,
Dislocation of the wrist backward.
Fracture of the shaft of one or both bones low down,
Separation of the lower radial epiphysis.

A sprain of the wrist is rather unusual. There very often exists in so-called sprains a definite anatomical lesion of bone. The deformity due to the distention of the synovial sac with fluid is

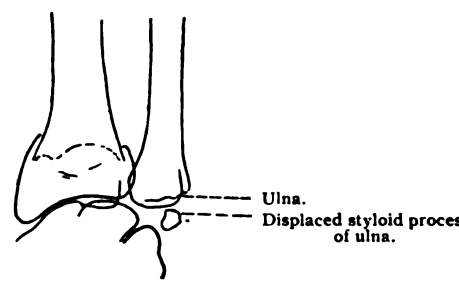

Fig. 312.—Colles' fracture with fracture of base of ulnar styloid; outward displacement of styloid fragment. Shaft of radius driven into the lower fragment (Massachusetts General Hospital, 1173. X-ray tracing).

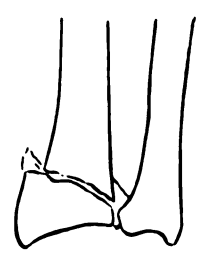

Fig. 313.—Radial fracture upward and outward (Massachusetts General Hospital, 1126. X-ray tracing).

conspicuous over the back of the wrist-joint and, therefore, near the hand. There is tenderness upon pressure over the synovial membrane anteroposteriorly. There is little or no tenderness over the radius upon deep pressure. There is an absence of the positive signs of fracture. It is not an uncommon experience to find an injury to the lower end of the radius presenting no posi-

tive fracture signs, which is proved by the Röntgen ray to be a break of the lower end of the radius. A lesion somewhat resembling that shown in figure 304, the bone being cracked along those same lines but without displacement, is sometimes found to exist. Many of these obscure lesions are passed over as sprains of the

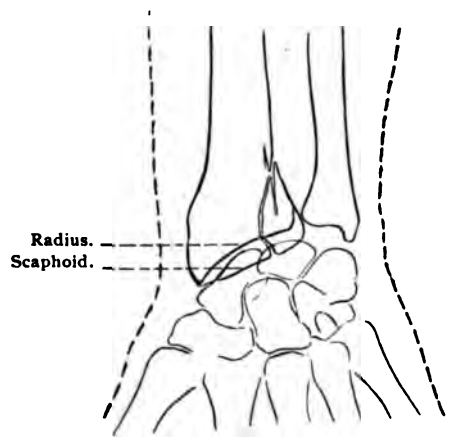

Fig. 314.—Fracture of inner edge of the radius (X-ray tracing).

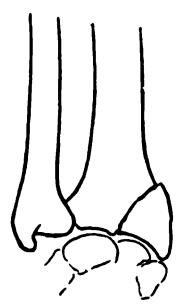

Fig. 315.—Fracture of radial styloid (Massachusetts General Hospital, 1252. X-ray tracing).

wrist. Any injury to the wrist, no matter how trivial, should be regarded with suspicion until there is absolute proof that fracture is absent.

A Contusion of One or Both Bones near the Wrist-joint: Tenderness is localized. Fracture signs are all absent. The Röntgen ray will assist in determining this diagnosis.

Dislocation of the wrist backward is rare. The posterior prominence is lower down on the wrist than in Colles' fracture. The

upper surface of the displaced carpus can be felt. The relation of the two styloids is preserved. The deformity disappears and does not tend to reappear when traction is made on the hand and pressure is made over the dorsal prominence.

Fracture of the shaft (see Fig. 317) of one or both bones low

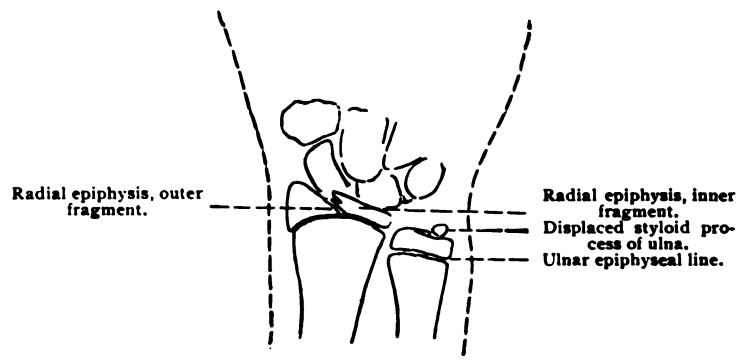

Fig. 316.—Fracture of the epiphysis of the lower end of the radius and of the styloid process of ulna (Massachusetts General Hospital, 712. X-ray tracing).

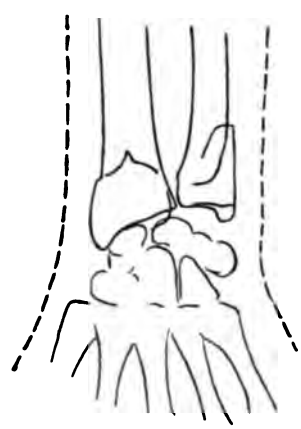

Fig. 317.—Colles' fracture, with fracture at lower end of ulna (X-ray tracing).

down may simulate the anteroposterior deformity of Colles' fracture, but an absence of other positive signs is important. The Röntgen ray determines the exact seat of the lesion. Abnormal mobility and crepitus are readily obtained without the administration of an anesthetic.

Fig. 318.—Case: Adult. Very great comminution of lower end of the radius. Extremely difficult to mold fragments into good positions. Note abduction of hand.

A Separation of the Lower Epiphysis of the Radius: The lower epiphysis of the radius unites with the shaft about the twentieth year. The radius increases in length chiefly through growth from its lower epiphysis. This lesion occurs much more commonly than has hitherto been supposed. It is usually classed as a Colles' fracture, no very careful examination being made. There is usu-

Fig. 319.—Reduction of Colles' fracture. Note position of hands in forcibly hyperextending the lower fragment; breaking up impaction.

Fig. 320.—Reduction of Colles' fracture. Note grasp upon forearm and the lower fragment of the radius, traction and countertraction being made; breaking up the impaction.

ally less deformity than is found in most Colles' fractures, and it is nearer the hand. The crepitus is soft and cartilaginous, and easily obtained without an anesthetic. The treatment of separation of the lower radial epiphysis is similar to that of a Colles' fracture. A fracture of the lower radial epiphysis is occasionally seen; it is, however, a rare lesion (see Fig. 316).

Associated with every Colles' fracture there may be one or more of the following lesions: A fracture through the lower end of the ulna, which is rather rare (see Fig. 317). A fracture of the styloid process of the ulna, which occurs in about fifty to sixty-five per cent. of all cases (see Fig. 312). A rupture of the interarticular triangular fibrocartilage at its insertion into the base of the styloid process of the ulna. This is probably quite common, and accounts in part for the broadening of the wrist-joint. A perforation of the skin by the lower end of either the ulna or the shaft of the radius, making an open fracture. A fracture of the scaphoid bone, although occurring often alone, is not very uncommonly associated with Colles' fracture. A sprain of the hand, wrist, forearm,

Fig. 321.—Reduction of Colles' fracture. Note position of the thumbs and fingers. Lower fragment is pushed into place while counterpressure is made by the fingers upon the upper fragment.

elbow, or shoulder may occur. It is wise to examine the whole upper extremity, particularly a few days after the accident, as it is at this time that sprains associated with fracture are likely to be detected.

Treatment.—The ordinary uncomplicated fracture is here under consideration. Reduction should be accomplished as soon as possible. Complete reduction can not be made satisfactorily without the administration of an anesthetic, either to complete or partial anesthesia. Very great force is needed to accomplish satisfactory reduction of impacted fractures of the radius. It is because of the use of too little force that often a slight bony deformity remains after union has taken place.

A Method of Reduction.—Grasp with the thumbs and forefingers

of the two hands the upper and lower fragments. Free the lower fragment completely from the upper by pressure and traction backward and forward and laterally upon the lower fragment, using all the force that is needed (see Figs. 319, 320). The lower fragment may then be forced into position by pressure of the two

Fig. 322.—Fracture of radius near wrist. Method of applying the posterior splint and dorsal pad in displacement of lower fragment backward.

Fig. 323.—Fracture of radius near wrist. Method of applying anterior splint and pad and of holding the two splints and arm for the application of straps. Anterior splint is cut out below the thenar eminence.

thumbs upon the dorsum of the wrist (see Fig. 321). When reduction is completed, the hand should be allowed to rest naturally without support to determine whether there is a recurrence of the deformity. If there is no recurrence of the deformity, the fracture may be fixed. If there is recurrence of the deformity, notice should be taken of the direction of the displacement of the

lower fragment, that proper pads may be applied to hold it in position. A pad of compress cloth placed on the dorsum of the wrist over the lower fragment will easily hold it if ordinarily displaced. A knowledge of the direction of the displacement of the lower fragment will suggest the prevention of the recurrence of the deformity. The Röntgen ray is making possible a more intelligent treatment of this fracture of the radius. The bone is so

Fig. 324.—Fracture of the forearm near the wrist-joint. Anterior and posterior splints. Straps are taut. Note length of splints, the position of the three straps, and the cutting out of the anterior splint to clear the thenar eminence.

Fig. 325.—Fracture of the forearm near the wrist-joint. Notice wrinkles in the straps. The straps are loose from the pressure of the two splints together. Thus is illustrated the fact that the straps should retain splints in position without exerting much pressure.

nearly subcutaneous that one can take advantage of an accurate knowledge of the line or lines of fracture in attempting reduction of the malposition. Intelligently applied force can now be used in each fracture instead of the hitherto blind routine manipulation. Thus, less injury is done in setting the fracture, and better anatomical results are obtained.

It is well to restore, if possible, the prominence of the lower end

of the ulna at the back of the wrist. Usually, after a Colles' fracture has healed and functional usefulness exists in the wrist and hand, the ulna will be found to have slumped forward—to have disappeared from the dorsum of the wrist. This can be prevented

Fig. 326.—Posterior splint padded with two thicknesses of sheet wadding. Two straps Note length of splint and position of straps.

Fig. 327.—Posterior splint, three straps, and pad at the seat of fracture. Note comfortable position of forearm and hand.

Fig. 328.—Completed dressing, similar to figures 326, 327. The bandage is applied evenly and uniformly.

partially at the time of setting the fracture, by padding the ulna anteriorly and by completely correcting the radial deformity and strongly adducting the hand.

Retentive Apparatus.—The simplest splint is the best. If there is considerable swelling about the seat of fracture in a rather

muscular and large arm, it is best to use the following apparatus: Two pieces of splint-wood, one for the back and the other for the front of the forearm, are provided. The back or posterior splint should extend from the heads of the metacarpal bones to a little above the middle of the forearm (see Fig. 322). The front or anterior splint should extend from the heads of the metacarpal bones to a little above the middle of the forearm (see Fig. 323). These splints are padded evenly and smoothly with sheet wadding, retentive pads at the seat of the fracture being used as needed. The hand and forearm are held in semipronation. The hand is adducted. The dorsal splint is applied and held in position. The anterior splint is then applied with the pads, and all are held in position by adhesive-plaster straps. The arm and splints are

Fig. 329.—Hand and fingers extended. Dorsal surface of forearm and hand practically straight and in the same plane. The anterior surface of the forearm and hand are rounded and irregular surfaces.

covered with a bandage. Direct pressure should be avoided over the head and styloid process of the ulna posteriorly, in order to minimize the disappearance of the bone from the dorsum of the wrist. A pad placed anteriorly and laterally over the lower end of the ulna is often useful in reducing the ulna head and styloid. The adhesive-plaster straps should be snugly but loosely applied. They are intended simply to retain the splints in position (see Fig. 324). After their application, pressing the two splints together should show that there is considerable slack in the straps (see Fig. 325); a springiness should exist between the splints. The necessary pressure on the splints should be secured by the bandage. The fingers are allowed to be free and movable. The arm is held in a sling. The sling should be so adjusted as to receive

the whole weight of the arm, the hand lying free from the upward pressure of the sling. The sling should be applied with the ends crossed in front of the neck.

At the end of the first week in most cases, in place of the two anteroposterior splints, it will be wise to use one posterior splint only and an anterior pad over the seat of fracture. The posterior splint is applied evenly padded, and if necessary, a small pad is placed over the dorsum of the lower fragment. The splint is held in place by two adhesive-plaster straps—one at the upper end of the splint around the forearm, the other around the metacarpal bones at the lower end of the splint (see Fig. 326). The fracture should be held securely by a third strip of adhesive plaster at the seat of fracture over a compress-cloth pad, which fills up the anterior hollow of the radius (see Figs. 327, 330). This pad holds

Fig. 330.—Anterior and posterior splints. Diagram of pad to fit the radial arch.

the fragments securely. A roller bandage gives even compression and support to the whole arm (see Fig. 328).

The posterior surfaces of the forearm, wrist, and hand in the extended position are practically in one plane (see Fig. 329); hence, the reasonableness of the use of the posterior splint. The arm lies naturally upon it. The anterior surface only requires accurate padding. The difficulty in applying an anterior splint accurately to the forearm and wrist is rendered clear by the illustration. The front of the forearm and wrist is a rounded and uneven surface (see Fig. 329). In order accurately to control the bone by a splint applied to the anterior surface of the forearm, the padding must be applied with greater care than is ordinarily exercised. No splint is manufactured that fits the wrist accurately. If the surgeon depends upon manufactured and molded splints, he is in very great danger of neglecting the fracture). It is best for the surgeon to use simple splints,

and to hold the fracture reduced by personally applied pads and straps.

Until the time of union the arm should always be comfortable. The patient should be seen, if convenient, within the first twenty-four hours of the application of the splint. Swelling may occur after the splints are applied, causing blueness or swelling of the fingers. The bandage may need reapplying to relieve this increase of pressure. With the subsidence of the primary swelling

Fig. 331.—Colles' fracture. Position of short dorsal splint of wood and palmar pad of compress cloth. Note method of holding before the application of the strap.

Fig. 332.—Colles' fracture. Short dorsal splint and palmar pad held in position by adhesive-plaster strap.

the bandage naturally loosens and will require tightening. It is rare that the straps and padding will need more than slight readjustment during the first week of treatment. At least every three days the pads should be removed with great care, and the arm carefully inspected. The alinement of the fragments is maintained by readjustment of the pads.

Gentle massage should be instituted to the fingers, hand, wrist, and forearm during the second week. Passive and active move-

ments of the fingers and wrist are to be made through the second week. During the second or third week it will be possible to shorten the dorsal splint and also to increase the amount of passive

Fig. 333.—Colles' fracture. Cravat sling holding wrist improperly. Hand pronated.

Fig. 334.—Colles' fracture. Cravat sling holding wrist properly. Hand semi-supinated. Wrist resting upon ulnar side with hand unsupported.

Fig. 335.—Right Colles' fracture in an old woman. Splints applied for five weeks without removal. Note deformity and flattening of hand and forearm. The fingers and wrist are stiff and swollen. Left hand is normal.

and active motion. At the end of the second or third week the union will be found to be firm. During the third or fourth week the splint may be removed and the wrist be supported by a wooden

dorsal pad (see Figs. 331, 332) two inches long and the width of the wrist, and by a palmar radial pad of compress cloth and strips of adhesive plaster about two inches wide. The middle of the plaster should come at the line of the break in the bone. After the fourth week all padding may be removed, and the wrist supported by a simple bandage. The fingers and hand may be used at this time. After the removal of the splint and while the arm is carried in a sling great care must be exercised lest lateral deformity result through an improper adjustment of the sling (see Fig. 333). The forearm should rest in the sling upon the ulnar side, and the hand, being unsupported, should be slightly adducted (see Fig. 334).

The treatment of a "reversed Colles'" fracture (see Fig. 296) will differ from the treatment of the ordinary fracture only in the method of reduction and in the position of the retaining pads. An anterior (palmar) pad will be needed over the lower fragment and a posterior (dorsal) pad over the shaft of the radius.

Prognosis and Result.—The swelling about the fracture in elderly people will persist longer than in the young. A functionally useful wrist-joint and hand should follow a simple uncomplicated Colles' fracture in healthy young adults. For some weeks tenderness may exist over the styloid of the ulna. Limitation of pronation and supination may persist for some time, disappearing, after several months, more or less completely. Supination is the last movement to be recovered. Limitation of movement at the wrist and in the fingers is not incompatible with a useful wrist-joint. Bony union is rapid—within three weeks. Care must be exercised lest in the early removal of support the soft callus is molded, by the ordinary movements of the wrists and hand, into some permanent deformity.

It is not uncommon for the line of the fracture of the lower end of the radius to extend into and involve the sigmoid cavity of the radius. Thus the inferior radio-ulnar joint is involved in the fracture. This fact is of importance, as it helps to explain the limitation of motion in pronation and supination which so often exists after fracture of the lower end of the radius. Often perfect supination is the last movement to be recovered, and this may in

part be explained by the involvement of the inferior radio-ulnar joint.

The destruction of parts of the lower fragment of the radius may have been so complete that it is impossible to restore the wrist to its normal shape, and some bony deformity will remain permanently (see X-ray plate, p. 234). Bony deformity is not incompatible with a functionally useful arm. In many instances it is impossible wholly to prevent a slumping forward of the head of the ulna and its corresponding disappearance from the back of the wrist. Complete reduction of the radial deformity together with a frequently re-adjusted pad upon the palmar surface of the wrist over the slumping ulna-head are the best methods for preventing the disappearance of the ulna from the dorsum of the wrist. Some slight widening of the wrist will remain after most Colles' fractures. The changes in the tendon sheaths about the fracture, the periarticular adhesions that form, especially in elderly people, cause much more hindrance to recovery of function than do the bony alterations (see Fig. 335). Early and persistent massage and passive motion will prevent these changes from becoming permanently troublesome. Old people are liable to have considerable difficulty in regaining the movements of the fingers, on account of adhesions within and without the tendon sheaths. The continued use of the hot-air treatment is of value in restoring mobility to the wrist and fingers.

Colles' fractures that have bony union with marked deformity should be corrected by osteotomy, if the wrist is functionally impaired. Colles' fractures two or three weeks old may be refractured manually, if necessary, to correct existing deformity. The ease of refracture and the limits in time within which it is possible will vary with individual cases. The more nearly the deformity in Colles' fracture is corrected at the first setting, the milder will be the subsequent pain about the wrist.

CHAPTER XI

FRACTURES OF THE CARPUS, METACARPUS, AND PHALANGES

FRACTURE OF THE CARPUS

SIMPLE fracture of the carpal bones is unusual. It is associated with other injuries. It is not uncommonly seen in crushes resulting in open fracture. The scaphoid is found fractured in certain Colles' fractures and in falls upon the outstretched hand. There are many cases of painful wrist, "rheumatism" about the wrist,

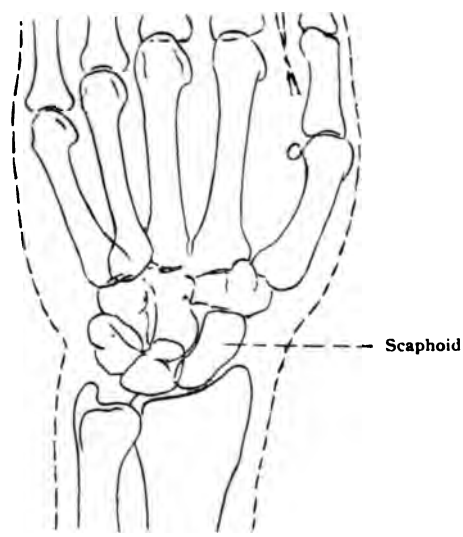

Fig. 336.—Normal wrist. No injury (X-ray tracing).

weak wrist, and sprained wrist that are instances of unrecognized fracture of the scaphoid bone. The persistence of the difficulty necessitates a physician's examination. In these cases a Röntgen-ray examination will reveal the true nature of the lesion. In interpreting X-rays of the carpus following injury it must not be over-

looked, as Prof. Thomas Dwight has observed, that in about 1 per cent. of all subjects the scaphoid is divided into two parts in the course of its development. Such an anomaly might be easily mistaken for a fracture of the scaphoid if the appearances in the X-ray alone were depended upon. After fracture of the scaphoid

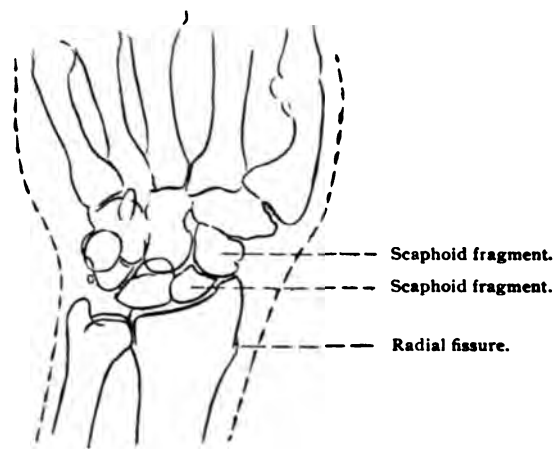

Fig. 337.—Case: Fracture of the scaphoid and fissure of radius (X-ray tracing) (Balch).

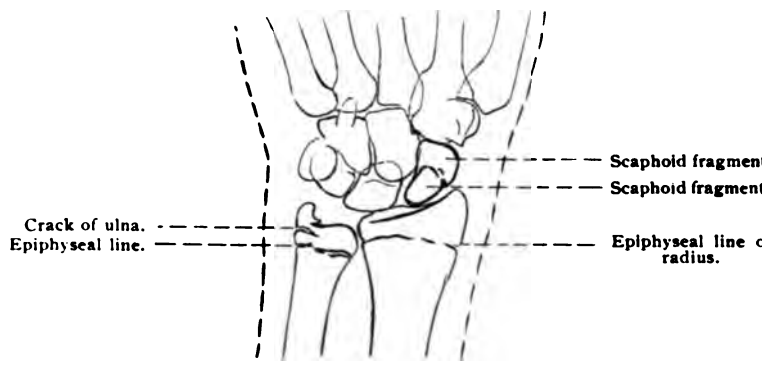

Fig. 338.—Fracture of the scaphoid. Lesion of epiphysis of ulna (X-ray tracing) (Balch).

bone persistent, painful limitation of extension at the wrist is not at all uncommon. The os magnum is sometimes fractured by falls upon the hand.

Treatment.—If there is displacement, immediate pressure and counterpressure, associated with extension and flexion of the wrist-joint, under an anesthetic will usually reduce the displace-

ment. Immobilization of the wrist-joint should be secured by means of a dorsal splint extending from above the middle of the forearm to the heads of the metacarpal bones (see Fig. 326). It should be retained by two adhesive-plaster straps. Sheet wad-

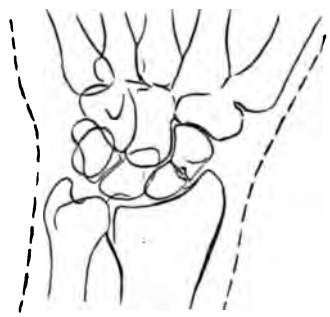

Fig. 339.—Fracture of the scaphoid. The two fragments are seen near the styloid of the radius (X-ray tracing) (Balch).

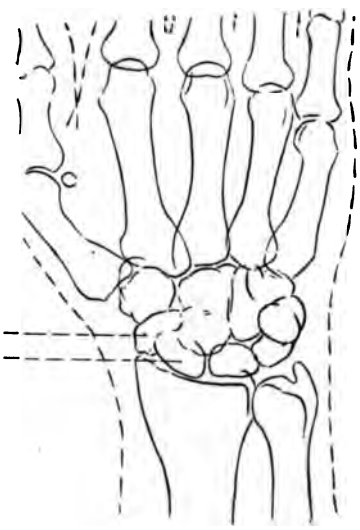

Fig. 340.—Case: Fracture of the scaphoid (X-ray tracing).

ding and gauze roller bandages are then carefully applied to the arm the whole length of the splint (see Fig. 328).

With the splint in position gentle massage to the wrist and forearm after the first week will hasten healing. Gentle passive mo-

tion with more vigorous massage will be indicated at the end of two weeks. At the end of three or four weeks all support save a roller bandage may be omitted. Stiffness will persist after this injury, especially in elderly people (see Figs. 336–340 inclusive).

FRACTURE OF THE METACARPAL BONES

The third and fourth metacarpal bones are the ones most commonly broken. The fracture is due to a blow upon the knuckles (see Fig. 341).

Symptoms.—The deformity is characteristic. The very considerable swelling often obscures the outline of the bones, but pal-

Fig. 341.—Metacarpus and phalanges showing epiphyses at fifteen years (Warren Museum, specimen 537).

Fig. 342.—Fracture of third metacarpal, showing dropping of knuckle. Ligamentous preparation.

pation detects the lower end of the upper fragment in the dorsum of the hand, while the upper end of the lower fragment is sometimes felt in the palm of the hand (see Fig. 342). This deformity is characterized by a loss from the line of the knuckles of that knuckle corresponding to the fractured metacarpal (see Figs. 343, 344). Pain and crepitus are present. The hand can not be closed tightly on account of the swelling and pain.

To obtain crepitus easily and to assist in reducing the fracture, it is best to grasp the finger corresponding to the fractured metacarpal with the whole right hand, steadying the injured metacarpus

A B

Fig. 343.—A, Fracture of neck of fourth metacarpal bone. Swelling of finger and knuckle. Knuckle has dropped downward toward the palm. B, Normal hand. Line of knuckles shown. Contrast with A.

A B

Fig. 344.—Fracture of the fourth metacarpal bone. View of two hands from behind: A, Normal line of knuckles. B, Knuckle of the ring-finger has dropped downward. Deformity well shown.

with the left hand, and then to make steady and continuous traction (see Fig. 344). The distal fragment is so short and movable that unless this method is used to steady the fragment it will be difficult to determine crepitus and to reduce the fracture. This fracture

Fig. 345.—Method of grasping hand and finger in examining for fracture of metacarpal bone, and in reducing such a fracture.

Fig. 346.—Fracture of the neck of the second metacarpal. Method of securing extension. Note adhesive plaster, rubber tubing, peg, padding to finger, pad over proximal fragment. Counterextension by adhesive plaster about wrist. Ready for the application of a bandage.

Fig. 347.—Fracture of the metacarpal of the index-finger. Use of roller bandage. Po of roller bandage. Method of traction and countertraction.

heals readily. Occasionally, however, a suppurative process may complicate recovery even when the fracture is not an open one.

Fig. 348.—Fracture of the metacarpal of the index-finger. Completion of traction. Pressure and counterpressure by thumb on the dorsum and on bandage in the palm of the hand.

Fig. 349.—Fracture of the metacarpal of the index-finger. Completion of the application of the dressing. Adhesive-plaster straps holding hand and roller bandage in position.

Bennett's fracture, commonly designated "stave" of the thumb, should be mentioned here. It is a fracture of the proximal end of the metacarpal of the thumb, oblique and into the joint with

the trapezium. (See figure of X-ray, No. 352.) The metacarpal bone is displaced backward. There is great disability in opposing the thumb and index-finger. Grasping small objects is impossible. Pressure upon the ball of the thumb is painful.

The injuries likely to be mistaken for this fracture are subluxation of this same joint, a sprain of this joint, and a contusion of this part.

Treatment.—After reducing the fracture by traction and pressure as suggested, it must be held in place by special padding, for

Fig. 350.—Transverse fractures of the last three metacarpals (X-ray tracing).

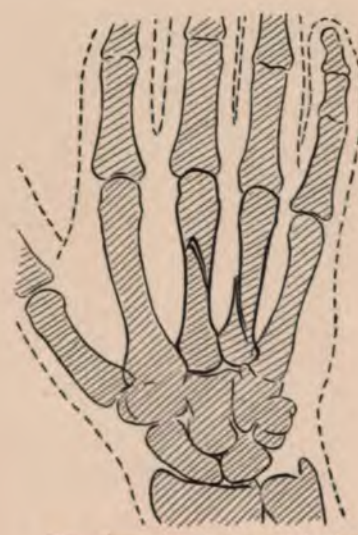

Fig. 351.—Oblique fracture of the third and fourth metacarpals (Massachusetts General Hospital, 1142. X-ray tracing).

the deformity tends to recur. The hand and forearm are supported upon a properly padded palmar splint. A pad is placed in the palm over the prominent lower end of the metacarpal. Another pad is placed upon the dorsum of the hand over the upper fragment. These pads are secured by narrow strips of adhesive plaster. The whole is then bandaged. If after carefully padding the two fragments and immobilizing them the deformity is reproduced, the fragments slipping by each other, it may be necessary to make permanent traction upon the finger (see Fig. 346). This is best done by applying narrow adhesive-plaster straps to the sides

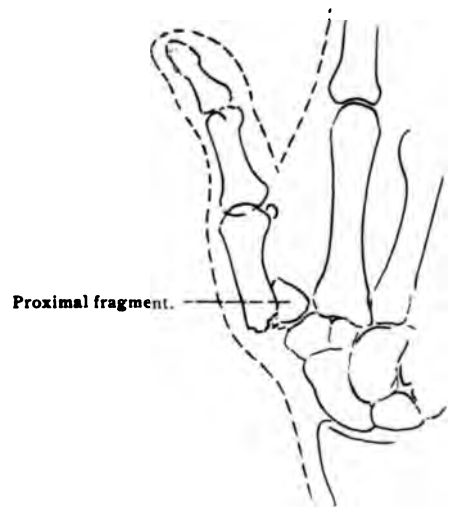

Fig. 352.—Fracture of the upper end of metacarpal bone of thumb. Displaced upper fragment could be felt in the palm of the hand (Massachusetts General Hospital, 1785. X-ray tracing).

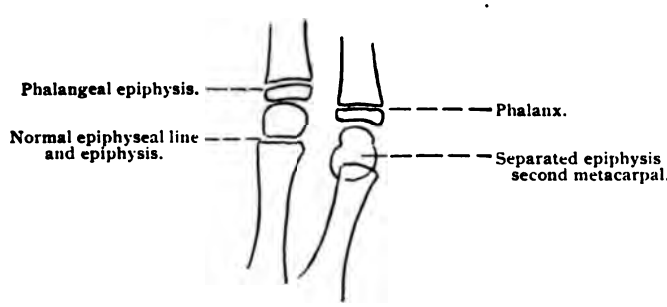

Fig. 353.—Separation of the distal epiphysis of the second metacarpal bone. Displacement into the palm of the hand. Rare (Massachusetts General Hospital, 1765. X-ray tracing).

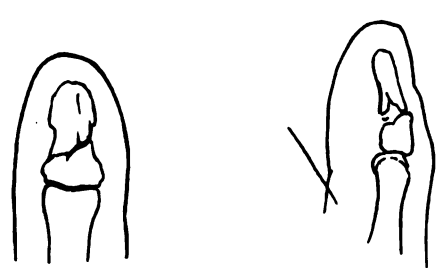

Fig. 354.—Fracture of terminal phalanx of thumb. Anteroposterior and lateral views (X-ray tracings).

of the finger held in place by circular and oblique straps. The hand rests upon the palmar splint. An adhesive-plaster circular band passed about the wrist and splint offers continuous counter-traction. If the band is carried between the thumb and forefinger, greater security is obtained, and there is much less likelihood of slipping of the plaster. The extension upon the finger is obtained by fastening the extension strips to small pieces of rubber tubing, and carrying the tubing around a wooden peg or screw passed through a hole in the splint.

Fig. 355. — Fracture of the finger. Wooden splint applied to the palmar surface. Note straps and length of splint.

Fig. 356.—Finger splint of copper wire applied.

A simple contrivance for a fracture with little displacement is the use of a roller bandage (see Figs. 347–349 inclusive). A roller bandage of cotton cloth that is firm and not easily compressed and of a size comfortable for the hand to grasp is selected. This is placed in the palm of the extended hand; the fingers and metacarpal heads are drawn down firmly over it. This position is maintained by a broad strip of adhesive plaster around the whole hand. Pads, as with the palmar splint, may be used to reinforce the roller bandage. Unless great care is exercised, this method will result in posterior bowing of the metacarpal bone. If there is an anterior

Fig. 357.—A, Finger splint of aluminium or tin, anterior surface. B, Finger splint applied to middle finger, three straps. Note position of splint in palm of hand.

Fig. 358.—Palmar wooden thumb splint. Note shape, pads, straps, position.

displacement of either or both fragments, this roller-bandage apparatus is very efficient in maintaining reduction of the deformity.

This apparatus should be carefully inspected each day during the first week, to be sure that the position obtained is held firmly. After three weeks the splint may be omitted. Massage during the third week will be of benefit. Great care must be exercised in the use of the hand following the removal of the splint until the fourth week is passed, for deformity may result (see Figs. 350–353 inclusive).

FRACTURE OF THE PHALANGES

The bones lie subcutaneously; fractures of the phalanges are, accordingly, comparatively easy to detect. Fractures near the

Fig. 359—Lateral splint of wood for fracture of the thumb. Note pad at the side of first phalanx, to correct lateral deformity.

articular surfaces are hard to detect because joint crepitus is deceptive. The so-called base-ball finger may, in many instances, be associated with a fracture of the head of the metacarpal bone, and, involving the joint, occasion a slow convalescence (see Fig. 342).

Symptoms.—Crepitus, pain, and abnormal mobility are present, and occasionally deformity is seen.

Treatment.—It is important that the alinement of the phalanx

be maintained. Rotation of the lower fragment upon its long axis is especially to be guarded against. Temporarily, if there is much swelling, the broken finger may rest upon a palmar splint, the two adjoining fingers serving as lateral splints to steady it. The contiguous skin surfaces must be protected by strips of cotton cloth and a drying powder.

A single splint of thin wood, extending from the middle of the palm of the hand to the finger-tip, and held in position by adhesive-plaster straps, is most useful (see Fig. 355). The splint-wood used should be cut thin and not left thick and bungling—half the thick-

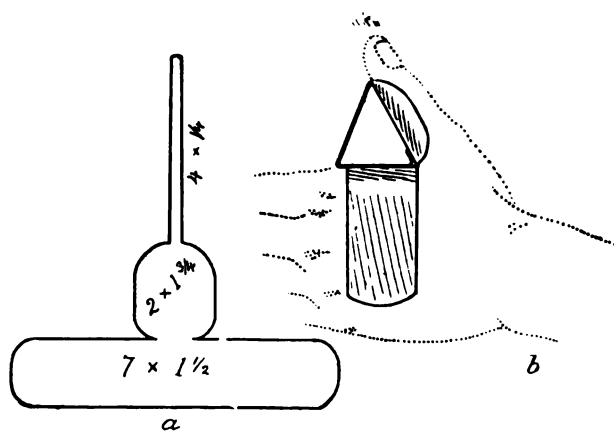

Fig. 360.—Thumb splint: *a*, Pattern—measurements are in inches; *b*, position of splint. Note extension of thumb (after Goldthwaite).

ness of the wood of an ordinary cigar box is about right. The splint should be a little narrower than the finger itself. A narrow cotton bandage applied over the finger or a simple cot to cover the finger will be comfortable and will assist in immobilization. Ordinary letter-paper, by continued folding, may be made into a narrow and suitable splint. This is simple and efficient. It should be held in place by a bandage or, preferably, by a cot. Ordinary copper wire may be used, as shown in the illustration, without any padding (see Fig. 356). This serves as a proper protection after the first week or two, and is not so clumsy as other splints. The aluminium or tin finger splint is easily made and satisfactory (see

Fig. 357). Any displacement in this fracture may be easily adjusted by narrow adhesive straps and small pads.

Fractures of the first and second phalanges of the thumb may be satisfactorily treated after reduction upon a dorsal or lateral splint of wood, if proper padding is employed (see Figs. 358, 359). Frequently, however, the tin splint fitted to the cleft between the thumb and forefinger, as shown in the illustration (Fig. 360), will immobilize these fractures more securely and comfortably.

Open Fractures of the Phalanges.—This is usually followed by profuse suppuration from necrosis of the fractured bones. This fracture is to be treated with extreme care, especially as regards antisepsis. Immobilization should continue at least four weeks. If at the end of this time union has not occurred, the patient may be given the option of continuing the treatment or of having the finger amputated. If union does not occur after four weeks of careful treatment, it is highly improbable that it will ever occur. Resection of the bones may be attempted before amputation.

CHAPTER XII

FRACTURES OF THE FEMUR

FRACTURE OF THE HIP OR NECK OF THE FEMUR

Anatomy.—The crest of the ilium can be felt throughout its entire extent, from the anterior superior spine to the posterior superior spine. The posterior superior spine corresponds to the level of the center of the sacro-iliac synchondrosis. The great trochanter of the femur is easily distinguished even in fat individuals. Nélaton's line is determined by stretching a tape from the anterior superior spine of the ilium to the tuberosity of the ischium (see Fig. 361). The top of the great trochanter lies at or a little below Nélaton's line, and about opposite to the symphysis pubis.

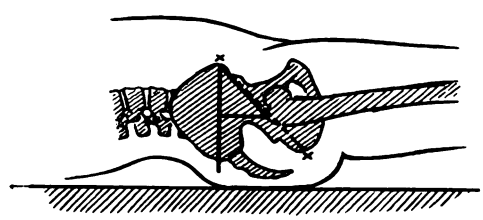

Fig. 361.—Nélaton's line (dotted line), from the anterior superior spine of the ilium to the tuberosity of the ischium. Bryant's triangle seen. Distance from top of trochanter to perpendicular dropped from anterior spine (X) is Bryant's measurement. After fracture this measurement may be less than normal.

The internal condyle of the femur looks in the same general direction as the head and neck of the femur (see Figs. 362, 363). The anterior superior spine of the ilium is of importance because from it measurement is made in taking the length of the legs after fracture of the femur. Normally, the fingers can be hooked behind the great trochanter toward the posterior surface of the neck of the bone. By this manipulation the posterior portion of the capsule of the joint can be felt.

Fracture of the Neck of the Femur in Adults.—This accident occurs most frequently in elderly people. It ordinarily is associ-

ated with a very slight injury, such as a trip and fall upon the floor from the standing position. Undoubtedly, in many instances the fracture precedes the fall. It is often difficult to determine the exact seat of the lesion. Whether the fracture is within or without the capsule of the joint is of comparatively little moment. On the other hand, whether the fracture is impacted or unim-

Fig. 362.—Femur, from front. Note normal relation of direction of head and neck to that of internal condyle.



Fig. 363.—Femur, from outer side. Note normal anterior bowing and relation of direction of head and neck to that of internal condyle.

pacted is of the greatest importance. Fractures of the base of the neck of the bone—that is, fractures near the trochanter—are usually impacted. Fractures of the neck toward the head of the bone are usually unimpacted (see Fig. 365). Impacted fractures unite readily. Unimpacted fractures often remain ununited.

Symptoms.—The patient is unable to rise from the ground. A contusion may be seen over the hip as a result of the fall. There is

pain in the hip while the patient is lying still. This pain is increased upon motion at the hip. There is an inability to move the injured leg easily and painlessly. There is limitation of motion of the injured leg. While lying upon the back it is impossible for the patient to raise the heel from off the bed. The foot is everted, the leg having rolled outward. The whole extremity lies helpless (see Fig. 366). There is a slight appreciable fullness below the fold of the groin. This fullness in the outer upper part of Scarpa's triangle corresponds to a non-depressible area associated with fracture of the neck of the femur. Slight shortening of the leg exists. After three or four days this shortening may increase to two inches. The

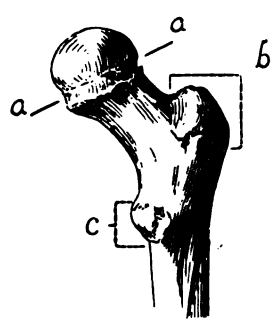

Fig. 364.—Upper end of femur in a child: *a*, *a*, Line of junction of epiphysis of head and shaft; *b*, epiphysis of greater trochanter; *c*, epiphysis of lesser trochanter (Warren Museum, specimen 334).

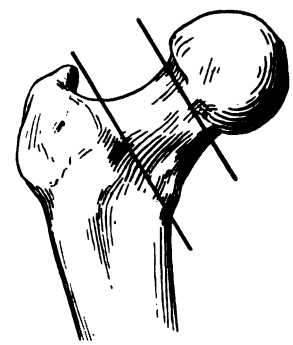

Fig. 365.—Head and neck of femur of adult. The lines show the ordinary seats of fracture.

trochanter is above Nélaton's line. The fascia above the trochanter is relaxed (see Fig. 367). This is especially noted in the standing position, with the patient resting the weight upon the well leg. If the fracture is an impacted one, crepitus will be absent upon gentle manipulation, unless the impaction has been broken up by some unwise means. If the fracture is unimpacted, crepitus can be detected by the hand while traction or gentle rotation of the leg is made. The foot is everted whether impaction is present or not. If the impaction is of the anterior portion of the neck, inversion will be present; if the impaction is of the posterior portion of the neck, eversion will be present (see

Figs. 368, 369). Impacted eversion can not be inverted nor can impacted inversion be everted without breaking up the impaction. In these cases of marked eversion and inversion a dislocation of the hip must be excluded if possible.

Examination.—A prolonged search for crepitus and abnormal mobility must never be attempted. In order to avoid unnecessary movement of the hip and because inspection and gentle palpation alone will so often decide the diagnosis, it is wise to follow a routine examination.

The history of the accident should be obtained. The presence and location of pain are determined. How much is the functional usefulness of the leg involved? What does inspection reveal as to the local condition and the position of the limb? What does pal-

Fig. 366.—Case: Impacted fracture of the left hip. Note helpless attitude of limb; foot everted.

pation reveal? How do the measurements of the leg and the trochanter compare with similar measurements of the uninjured leg? Last,—and to be avoided if a diagnosis has been reached,—what does gentle manipulation show as to the presence of crepitus in the hip?

In order to make a systematic examination all clothing, of course, should be removed from the patient. He then should be placed upon a firm and even surface. A hard mattress, a table, or a comforter spread upon the floor will provide the necessary conditions. An anesthetic is hardly ever necessary for diagnostic purposes. If an anesthetic is employed, the hip should be handled in the gentlest manner possible. All muscular spasm, which without an anesthetic protected the hip from violence, is abolished; therefore, movements of the hip are felt directly by the bone unprotected by mus-

cular spasm. All sudden quick movements should be avoided. There is great danger that an impacted fracture of the hip may be changed by rough handling, especially in the movement of rotation, to an unimpacted fracture. Palpation of the neck of the femur with the thumb in front of, and the fingers behind, the great trochanter will detect any irregularity or thickening and tenderness about the neck of the bone (see Fig. 377). By palpation of the great trochanter one may discover there the seat of fracture.

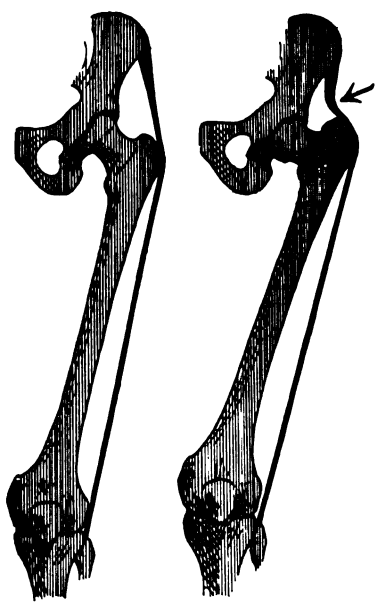

Fig. 367.—Relaxation of the fascia lata as a result of fracture of the hip. Most obvious at point shown by the arrow.

Swelling, tenderness, and crepitus may be found. Only gentle strong traction in the line of the long axis of the thigh should be made to elicit crepitus and abnormal motion.

Measurement.—The absence of any preexisting injury or disease of the hip under consideration is always to be carefully noted. Measurement should always be made with the patient lying on the back. The leg should be brought gently alongside of its fellow, and steadied by an assistant. Measurement should be made from the anterior superior spine of the ilium to the internal malleolus

upon each side (see Fig. 397). If there is shortening upon the injured side, a fracture with some displacement is likely to have occurred. A normal difference in the length of the lower limbs is, however, not unusual. It is, therefore, necessary to determine the presence of asymmetry if it exists, if any confidence is to be placed in the measurements of the legs. Measurements should, therefore, be made of the tibia upon the two sides, and these compared. If no asymmetry appears to be present, any differences in measure-

Fig. 368.—Fracture of the hip. Inward rotation of the leg because of impaction of the anterior portion of the neck of the bone.

Fig. 369.—Fracture of the hip. Outward rotation of the leg because of impaction of the posterior portion of the neck of the bone.

ment may be taken to be absolute. If it is impossible to bring the legs parallel, they must be placed in the same relative positions to the median line of the body.

Bryant's method of measurement is simple and of service (see Fig. 361). The limbs are placed symmetrically. The top of the trochanter is marked upon the skin. A perpendicular line is dropped from the anterior superior spine to the table upon which the patient lies. Measurement is made from the top of the tro-

chanter to this perpendicular line. If fracture of the neck of the femur has occurred, and there is displacement or shortening of the limb, the distance from the perpendicular to the top of the tro-

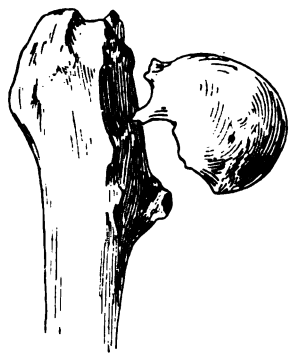

Fig. 370.—Old fracture of femoral neck; no union. Absorption of whole neck of bone. The contiguous surfaces of the fragments are of hard, compact bone. There is some atrophy of the whole shaft of the femur (Warren Museum, specimen 8075).

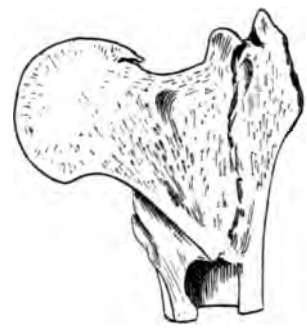

Fig. 371.—Fracture of femoral neck. Impaction of base into the shaft, with downward and inward rotation of upper fragment (Warren Museum, specimen 6303).

Fig. 372.—Fracture between neck and shaft and fracture of great trochanter. Union so imperfect that fragments separated in maceration (Warren Museum, specimen 1075).

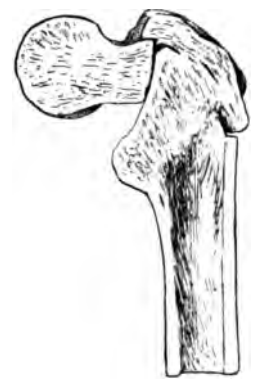

Fig. 373.—Fracture of the neck of the femur and of the great trochanter in section. Impaction; union not firm (Warren Museum, specimen 5225).

chanter will be less than a like measurement on the uninjured side. The position of the top of the great trochanter is determined with reference to Nélaton's line (see Fig. 361). If the leg is rolled outward, dislocation of the hip forward would be suspected, but the

absence of the head of the bone anteriorly and the absence of other positive signs should eliminate dislocation. If the leg is rolled inward, a dislocation of the hip upon the dorsum ilii would be considered. The absence of other positive signs of dislocation and the presence of the head of the bone in the acetabulum should con-

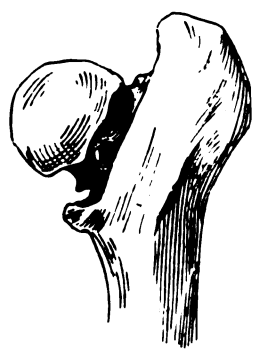

Fig. 374.—Fracture of femoral neck, unimpacted; fibrous union, with absorption of the neck (Warren Museum, specimen 3651).

Fig. 375.—Old impacted fracture of the hip; penetration of the inner wall of the neck into the head of the bone; displacement and rotation of the head downward and inward (Warren Museum, specimen 1086).

Fig. 376.—Fracture of hip: impaction of neck of bone into the head; rotation of head downward and backward; view from behind (Warren Museum, specimen 1086).

vince one of the nonexistence of dislocation. In an elderly person who presents no well-marked sign of fracture, but who is unable to use the limb after ever so slight an injury, a fracture of the hip should be so strongly suspected that, until the Röntgen ray proves it absent, he should be treated as if a fracture were present.

Prognosis and Result.—In the very aged and feeble the shock of a fracture of the neck of the femur is severe. The danger to life in these cases is great. An elderly patient may die of shock within two or three days, or within a week of hypostatic pneumonia, or he may live several weeks and die of exhaustion because of pain and the enforced confinement. If the fracture can be treated with proper immobilization, union will occur in most cases. The impacted cases will unite; the unimpacted cases may unite. Slight shortening with a little deformity, some limitation in the movements of the hips, a limp, but a fairly useful limb, are to be hoped for (see Fig. 378). Chronic rheumatism will often prevent a fractured hip from ever becoming useful.

Nonunion of the hip-fracture does not preclude a useful limb (see Fig. 379). Ununited fractures of the hip are greatly benefited

Fig. 377.—Method of palpating the trochanter of the right femur.

by proper ambulatory apparatus. They may be made to unite by mechanical means even several weeks and months after the injury. This is particularly true of fractures occurring in young adults.

Results after Fracture of the Hip.—Of especial value in this connection are the conditions existing in sixteen cases of fracture of the hip, many years after the accident. These sixteen cases were treated at the Massachusetts General Hospital by gentle traction and immobilization, for periods varying from a few weeks to a few months. The patients then went about with crutches. No other treatment was used. Nearly all the cases were unimpacted either primarily or secondarily. At the time of the accident seven cases were between forty-two and forty-seven years old, the remainder—with two exceptions, whose ages are not stated—were over fifty; three were over sixty years old. These cases reported for exami-

nation from two and one-half to twenty-four and one-half years after the accident. Thirteen of the sixteen cases have impairment of the functional usefulness of the leg; a weakness of the limb, necessitating a crutch in many instances; all movements at the hip somewhat restricted; atrophy of the muscles of the thigh, buttock, and calf of the leg; a decided limp, requiring a cane; pain in the hip extending down the thigh even to the sole of the foot; pain at night in the hip; pain in going up-stairs and in stooping

Fig. 378.—Deformity following an old fracture of the hip.

Fig. 379.—Case: Man, forty-five years old. Fracture of the neck of the femur. Union ligamentous, with displacement. Useful limb (X-ray tracing).

over. In only two cases out of the sixteen could it be said that the leg was functionally useful.

Treatment.—General Considerations.—Fractures of the hip or of the neck of the femur demand the greatest tact in their management. The aged respond readily to care. The patient should be made to feel as comfortable as possible while confined to his bed. Particular attention should be paid to diet and to all little comforts. The discomforts attendant upon immobilization are often very great. Let the days spent in bed be made especially attractive.

Be sure that agreeable friends visit the patient, seeing to it that they do not stay so long a time as to weary him. Let them interest him in the news of the day, so that he may feel that he is keeping up with events. Employ a skilled nurse to minister to his wants; a bright and cheerful woman nurse is ordinarily better than a man nurse. The pulse is to be carefully watched as well as the respiration. A moderate amount of alcohol once or twice a day

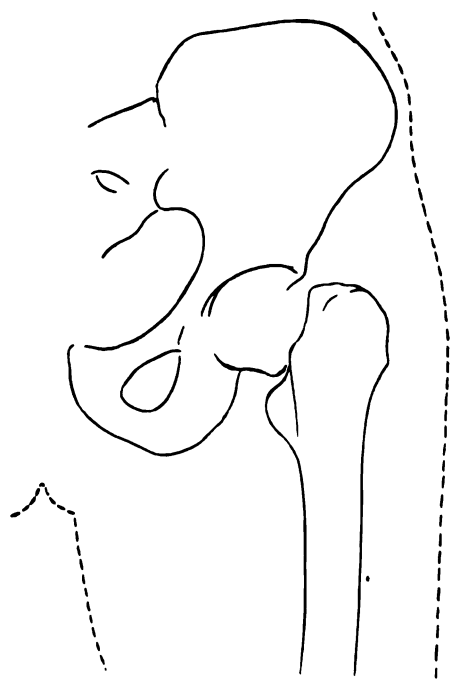

Fig. 380.—Case: Fracture of the neck of the femur (X-ray tracing).

with meals is to be used. The courage of the aged needs bracing. Bed-sores develop with surprising rapidity. Skilled watchfulness and immediate treatment will often check the progress of a red pressure spot. The part exposed to pressure should be kept very clean with soap and warm water; it should be bathed with alcohol, thoroughly dried, and well dusted with powder (starch and oxid of zinc, equal parts); and the pressure should be relieved by proper pads or cushions. If the heel is the part involved, a rubber cushion

or a ring made of sheet wadding wound with a bandage may be used. A certain amount of moving about in bed should be granted to old people. Asthenic hypostatic pneumonia from long-continued resting in one position is not uncommon. Therefore, moving about a little in bed, to the extent of sitting upon a bed-rest at varying angles, is beneficial. Deep rhythmical breathing while lying flat on the back is a splendid stimulator of the circulation. In the case of a fracture of the neck of the thigh-bone occurring in an elderly individual treat the patient and let the fracture be of almost secondary importance.

Treatment of the Fractured Hip.—The patient should be placed upon a comfortable, firm, hair mattress. Underneath the mattress, crossing the bedstead from side to side, should be placed several wooden slats about eight inches apart. These bed-slats prevent sagging of the mattress and much consequent discomfort. Great caution must be exercised that no sudden or forcible movements of the hip are made which might break up the impaction of the bone or cause unnecessary pain. The leg should be placed in as natural a position in extension as possible. The knee should be placed upon a pillow. Extension strips of adhesive plaster should be applied to the leg and thigh as high as the perineum, and should be held to the skin by a gauze roller bandage. A weight of about five pounds should be applied to the extension while the leg is gently rotated and carefully placed approximately in the normal position. The foot of the bed should be elevated to the height of six inches in order to secure counterextension. Long and heavy sand-bags should be placed on each side of the leg and thigh to assist the light extension in affording support and to give a sense of security. The heel, as mentioned before, should be properly protected from undue pressure. The foot should be kept at a right angle with the leg. To afford still greater immobilization, a long T-splint extending from below the foot to the axilla of the injured side may be applied by straps about the leg and a swathe about the body (see Fig. 410).

After-care of the Simple Traction Method.—The general care of the patient should be as outlined previously. He should be kept quiet in bed for about two weeks. During the second week he may be bolstered up on pillows to the half-sitting position. Ordi-

narily, the extension may be removed during the third week. The patient may then be lifted to another bed or divan and be rolled into an adjoining room. In this change the thigh should be supported by sand-bags. The patient may be up in a wheel-chair after the first six weeks or two months with the knee straight on a board or, if comfortable, flexed. He may use crutches and a high shoe upon the well foot, not bearing any weight upon the injured hip, after about two months or ten weeks. He should not bear weight upon the hip even with the assistance of crutches for about three or four months. At the end of a year he may be walking with one cane. The foregoing is the course of a case treated according to the old-time simple extension or partial immobilization method. It is a matter of common observation that many impacted hips recover with fairly useful limbs with this treatment. Impacted hips are known to have recovered with useful limbs without any medical or surgical advice or treatment, the impacted fracture having been thought at the time of the injury to be a severe contusion which would be all right in time. These cases have occurred both among adults and children.

Greater immobilization of the impacted and unimpacted hip is demanded in most cases than can be obtained by the simple traction and countertraction previously described. The simple method is far from ideal: malunion and nonunion with resulting disability too often follow its use, the period of disability is long, and the ultimate results are often most unsatisfactory. Very refractory individuals will have to be left pretty much to themselves. No great restraint can to advantage be forced upon them.

The Fixation Method of Treatment.—In order to put the unimpacted bones of the hip-joint under the very best conditions for union to take place not only must the fragments be approximated by traction, correction of eversion or inversion, and lateral pressure over the trochanter major, but these fragments must be firmly fixed. In order to immobilize these fragments absolutely the body or pelvis and the thigh must be fixed. The simple method already described, in spite of the fact that it has been used for many years in these cases, does not immobilize. The most comfortable and efficient method of immobilization is by the use of the

Thomas hip-splint. The description which follows of the Thomas hip-splint and its use is that given by Ridlon.

The Thomas hip-splint secures posterior support to the fracture, gives fixation without compression of the fractured region except posteriorly, allows the patient to be lifted with ease, does not interfere with the groin, favors cleanliness, admits of traction, can be applied without moving the patient and without assistance, and presents no difficulties after the initial application (see Figs. 381, 382).

The splint is made of soft iron, and consists of a main stem, a

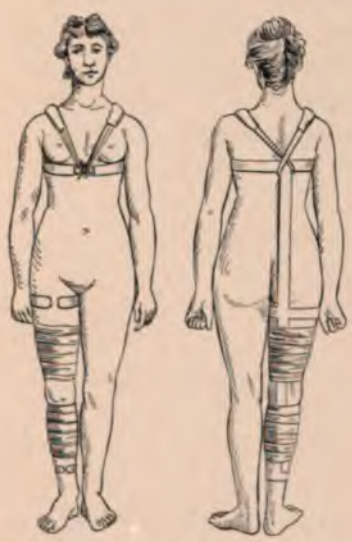

Fig. 381.—Thomas' single hip-splint in position (Ridlon).

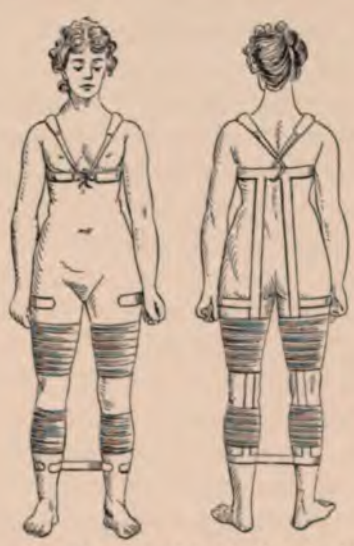

Fig. 382.—Thomas' double hip-splint in position (Ridlon).

chest-band, a thigh-band, and a calf-band. The stem is an inch and a quarter wide and one-fourth of an inch thick, and in length reaches from the axilla to the calf of the leg—the length of the lower portion from the hip-joint to the calf of the leg being equal to that from the axilla to the hip-joint. In the part opposite the buttock two gentle bends are made, the lower somewhat backward and the upper upward, so that the body and leg portions of the splint follow parallel lines from one-half to one inch apart, the body portion being posterior to the leg portion. The stouter

the patient, the more nearly do these parallel lines coincide, and in some cases the main stem may be left entirely straight. To the lower end is fastened, by one rivet, the calf-band, one-sixteenth by five-eighths of an inch, and in length an inch or two less than the circumference of the leg at this point. The thigh-band is one-sixteenth by three-fourths of an inch, and in length an inch or two less than the circumference of the thigh at its largest part; it is riveted to the main stem just below the lower bend, so that when applied to the patient, it comes well up to the perineum. The chest-band is three-thirty-seconds by one and one-fourth inches, and in length nearly equal to the circumference of the chest, being relatively longer than the other bands. It is fastened by one rivet after the upper end of the stem has been forged flat and bent back over it. This arrangement makes a fast joint, and brings the stem between the chest-band and the skin. In each end of the chest-band a round hole is forged of at least one-half of an inch in diameter.

Summary of material and measurements required in making the Thomas splint:

Stem, $1\frac{1}{4}$ inches wide, $\frac{1}{4}$ inch thick, extending from the axilla to the calf of the leg.

Calf-band, $\frac{5}{8}$ inch wide, $\frac{1}{16}$ inch thick; the length is two inches less than the circumference of the calf of the leg.

Thigh-band, $\frac{3}{4}$ inch wide, $\frac{1}{16}$ inch thick; the length is two inches less than the largest circumference of the thigh.

Chest-band, $1\frac{1}{4}$ inches wide, $\frac{3}{32}$ inch thick; the length to nearly equal the circumference of the chest.

A hole is forged at each end of the chest-band, $\frac{1}{2}$ inch in diameter. Any good blacksmith can make this splint in a very short time.

The splint is now bent to fit approximately the patient, padded on the side that is to come next the skin with a quarter-inch thickness of felt, care being taken to leave no inequalities of surface, and then covered with basil leather put on wet and tightly drawn, so that when dry it will have shrunk sufficiently to prevent the cover from slipping on the iron. The splint is applied by opening out the wings of the bands looking to the uninjured side of the patient, and then slipping them, followed by the stem, under-

neath the patient from the injured side; the wings that were straightened are bent again by hand and readily return to their former curves. A closer and more accurate adjustment of the wings may be made by the use of wrenches; these will be found especially serviceable in fitting the chest-band and in drawing in the other bands when the patient is very intolerant of any threatened movement or jarring.

"The splint having been fitted, if retentive traction is not required, the limb is bandaged to the stem from the calf to the upper part of the thigh, rolling the bandage in the direction the opposite to the rotary deformity that may be present; then shoulder-straps are applied by taking a couple of yards of broad bandage or a strip of muslin, looping it round the stem where it joins the chest-band, then over the band and over the shoulders, and down to the ends of the chest-band. Here it is passed through the holes and tied; then it is passed across the intervening space to the opposite hole and again tied. If retentive traction is desired, the shoulder-straps are omitted. To each side of the limb from the upper part of the thigh after the limb has been pulled down to the splint a broad strip of adhesive plaster is applied. The lower ends of the plaster are turned outward and upward around the wings of the calf-band, where they are fastened by a strip of plaster passed entirely around the limb; the whole is then covered with a bandage. By this arrangement the limb is pulled upon only to the extent of correcting the actual shortening, and is held at one and the same length sleeping or waking, whether the muscles relapse or are spasmodically contracted.

"The device aims to prevent motion in the axis of the limb; to prevent lateral motion by bending the limb in any direction; to do this without constricting the region of the fracture; and to enable the patient to have the bed-pan adjusted without pain and without disturbing the relation of the parts. When the splint has been applied and the patient is in bed, the nurse should be instructed in certain manœuvers. The bed-pan is adjusted by passing the arm under both limbs or below the knees and then lifting directly upward, making an incline of the whole patient below the chest-band. By this manœuver it is also more easy to smoothe out wrinkles in the bedding and change the sheet than

in the usual way. The stem should be made to press upon different parts of the skin by pulling the skin night and morning first to one side and then to the other. The patient should be inspected daily for pressure sores by turning him on the sound side. In order to turn a patient upon the sound side support the fractured limb at the knee with one hand and grasp the chest-band with the other; the patient then is readily turned as a whole. The points

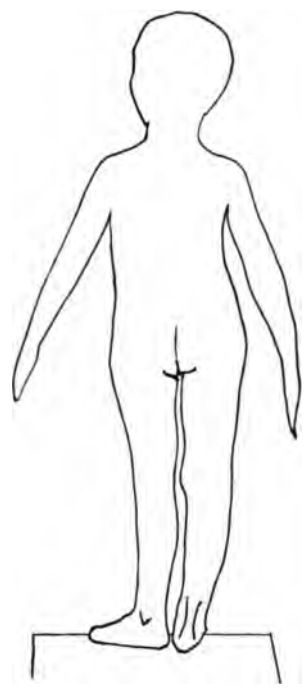

Fig. 383.—Tracing of photograph of patient (see skiagram, Fig. 384) four years after fracture of the left femoral neck, showing the shortening and turning out of the leg (after Whitman).

most likely to suffer from pressure are those at the junction of the thigh-band and stem, the lower bend of the stem, and the junction of the stem and chest-band. Points pressed upon should be lightly dressed with flexible collodion and protected from further pressure by padding above and below. If the pressure of the whole body portion of the stem is complained of, a small, thin mattress of hair or a sheet folded to several thicknesses may be placed between the

splint and the patient's back. Threatened hypostatic congestion is obviated by raising the head of the bed from one to three feet, the patient meanwhile being prevented from slipping down by tying the splint to the head of the bed. In all cases obviously unimpacted and in all cases when the shortening is more than three-fourths of an inch, traction should be applied.

"In all cases the splint should be kept on for from six to eight weeks after all pain has ceased; then the patient should remain in bed four weeks longer without any treatment whatever, unless there is some positive indication to the contrary, in which case the splint is cut off at the knee and the calf-band riveted at this point and the patient permitted to go about with crutches."

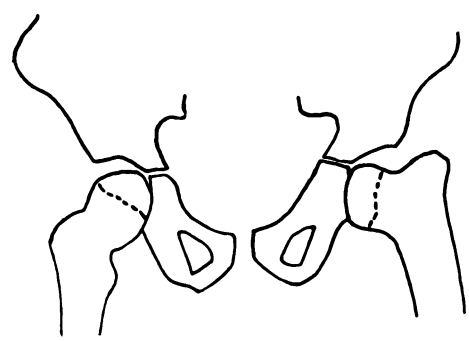

Fig. 384.—Skiagram tracing of patient two and a half years of age, after the accident, illustrating the deformity of the neck and of the upper extremity of the shaft, also the elevation of the pelvis on the affected side (after Whitman).

In addition to the use of the Thomas splint, it may be wise to make lateral pressure, as suggested by Senn, over the trochanter of the broken hip with the expectation of more firmly fixing the broken bone. Lateral pressure may be secured by a surcingle or by a bandage applied over a graduated compress. The spot to which pressure is applied should be carefully watched and protected.

The Operative Treatment.—Suturing or pegging the fragment is very properly to be reserved for fractures occurring in young adults in whom the absolute fixation by the Thomas splint for a reasonable period has not effected union.

Fracture of the Neck of the Femur in Childhood.—Whitman

has called especial attention to this fracture. The anatomical proof of the existence of fracture of the neck of the femur in childhood has been furnished by the specimens of Bolton, Meyers, and Starr. The fracture occurs after traumatism to the hip probably more frequently than separation of the upper femoral epiphysis.

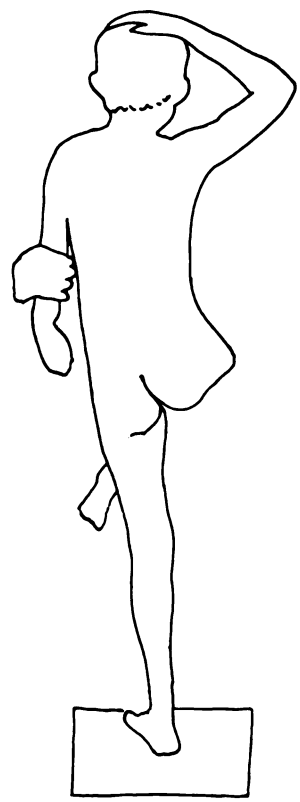

Fig. 385.—Tracing of photograph of patient eight years old, some years after a fracture of the neck of the right femur, showing great projection and elevation of the trochanter, made more apparent by flexing the thigh and leg (Whitman).

It is not so uncommon an accident as has been supposed. The fracture is probably impacted or greenstick. The clinical picture of fracture of the neck of the femur in childhood differs greatly from that furnished by a similar injury in old age. In the first instance a healthy child falls from a height, and presents a shortening of the thigh of from one-half to three-quarters of an inch. There

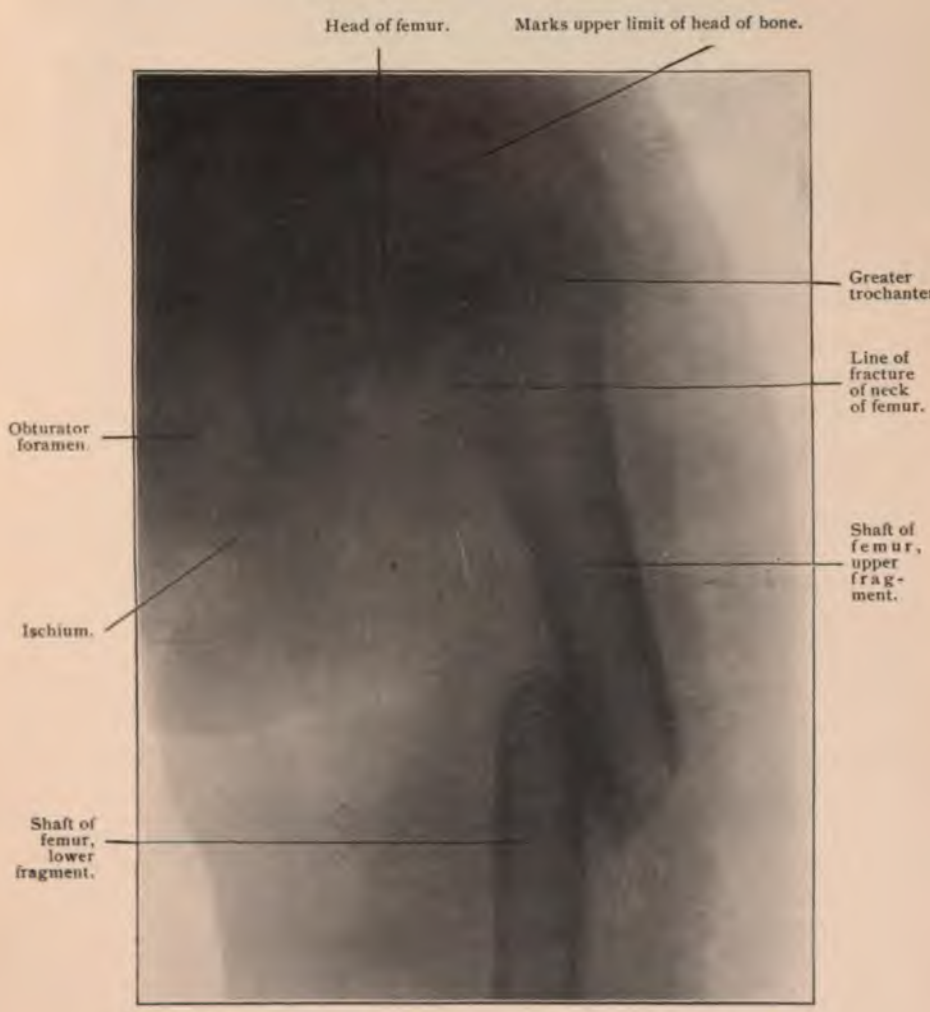

Fig. 386.—Case: Girl 13 years of age. Old fracture of shaft of femur with vicious union. Fresh fracture of neck of femur.

are slight outward rotation of the leg and limitation of motion and slight discomfort in the hip. The child may walk about after a few days with but a little lameness to suggest that any injury has been received. The child recovers with a limp. Months or years later signs of coxa vara appear. In childhood a rather severe injury is followed by immediate symptoms, and later by great disability. On the other hand, in old age a trivial injury is followed by immediate and complete disability. It is often overlooked in the child and is treated for a contusion or sprain of the hip. The immediate result, however, is extremely good even without more than bed treatment, but the ultimate result after several months or years may be disastrous because of the disability due to a gradually increasing bending of the femoral neck. The late result of fracture of the femoral neck in childhood resembles hip-disease in the limp, slight pain, shortening, deformity, and limitation of motion present. Care must be taken not to confound the two conditions. These later stages of fracture are to be treated by rest to the joint. All body-weight and the jar of walking are to be removed by a properly fitting hip-splint with traction. Refracture and operative measures are to be seriously entertained, as in other forms of coxa vara, particularly if the disability is great or is increasing (see Figs. 385–390 inclusive).

The treatment of a fresh greenstick or impacted fracture of the hip in children should be by rest on the back in bed and moderate traction and immobilization of the hip and thigh and body. After a month the child may be allowed up, wearing a traction hip-splint for several months until union is so firm that the danger from coxa vara is practically eliminated. A light plaster-of-Paris spica bandage from calf to axilla will maintain immobility after the splint is omitted.

FRACTURE OF THE SHAFT OF THE FEMUR

Fracture of the shaft of the femur is usually oblique. It is situated either just below the lesser trochanter (subtrochanteric fracture), at the center of the shaft, or above the condyles (supracondyloid fracture). Even in closed fractures there is sometimes great damage to the soft parts: the vessels of the thigh are at times injured.

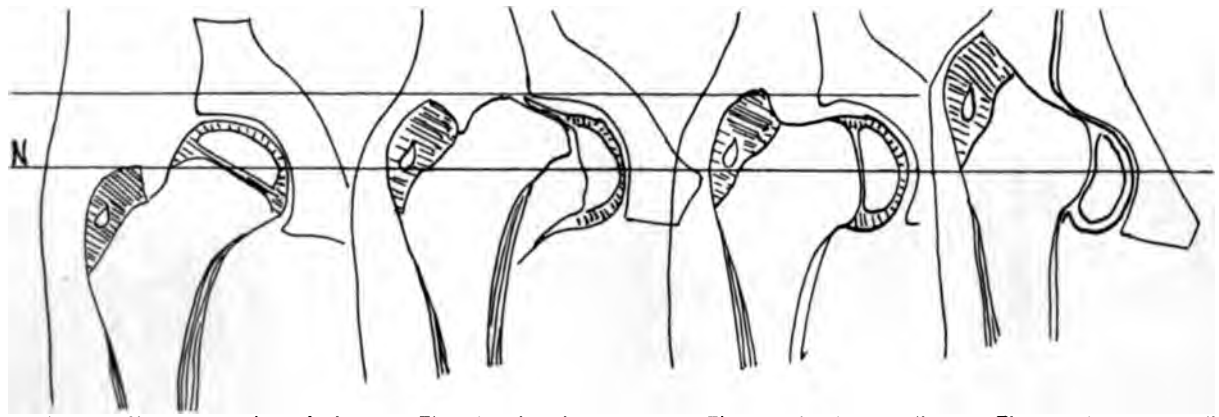

Fig. 387.—Upper extremity of the femur. Exact size at the age of five years, showing the epiphysis of the head and trochanter and the relation of the trochanter to Nélaton's line, N. The shaded area represents the cartilages (after Whitman).

Fig. 388.—A scheme to represent epiphyseal disjunction, showing the separation of fragments necessary to account for upward displacement of the trochanter to the extent of three-fourths of an inch (after Whitman).

Fig. 389.—A scheme to illustrate fracture and depression of the neck of the femur and consequent elevation of the trochanter, also the limitation of the range of abduction of the limb that must result (after Whitman).

Fig. 390.—A scheme to illustrate further depression of the neck and its effect in causing permanent adduction of the thigh (after Whitman).

Symptoms.—There is often great swelling at the seat of fracture. The limb lies helpless. Pain, abnormal mobility, deformity, marked lateral rolling of the leg below the seat of the fracture, and crepitus, one or all, may be evident (see Figs. 391, 392). The limb is shortened.

Measurement (see Figs. 395–398 inclusive) to determine the amount of the shortening is to be made from the anterior superior spinous process of the ilium to the internal malleolus of the same side. Great care must be exercised in taking this measurement so that the patient lies flat upon the back upon a hard and even surface, with the arms at the sides of the body and with no pillow under the head or shoulders. The long axis of the body should

Fig. 391.—Fracture of the thigh at the middle. Characteristic deformity.

be in the same line with the long axis between the legs as they lie with the malleoli approximated—*i. e.*, the chin, episternal notch, umbilicus, the symphysis pubis, the midpoint between the knees, and the midpoint between the internal malleoli should all be in one straight line (see Fig. 398). The line joining the anterior superior spinous processes of the ilia should be at right angles to this long axis of the body and thighs. Any variations from this normal position are attended by errors in measurement, which are important. If for any reason the injured thigh can not be brought easily alongside its fellow, the two limbs should be placed as nearly symmetrical with reference to the median line as possible.

The method of measuring the lengths of the lower extremities used by Dr. Keen differs from the above in that he uses the malleolus as the fixed point, and measures to a line drawn at the anterior superior spinous process of the ilium. The finger and tape are not allowed to touch the skin-mark, and so do not displace it.

Treatment of Fracture of the Shaft of the Femur.—The Transportation of a Patient: The emergency method of putting up a fracture of the thigh or hip is of very great practical importance (see Fig. 399). Limbs are fractured frequently some distance from the proper place for the application of the permanent dressing. It is necessary to transport such cases with the greatest de-

Fig. 392.—Fracture of the right femur at the middle. Characteristic deformity. Inward rotation of leg below fracture.

gree of safety and comfort. In order to accomplish this the knee- and hip-joints should be extended, the leg being held straightened in the long axis of the body. The limb should be placed upon a heavily padded board, the width of the thigh, extending from the middle of the calf to above the sacrum. The side splints of wood should be used—one on the outer side extending from the side of the foot to the axilla, the other upon the inner side extending from the side of the foot to a few inches below the perineum. Upon the front of the thigh is placed a coaptation splint extending from the groin to the patella. All of these splints are carefully padded, preferably with folded sheets or pillow-cases or towels; of course, in

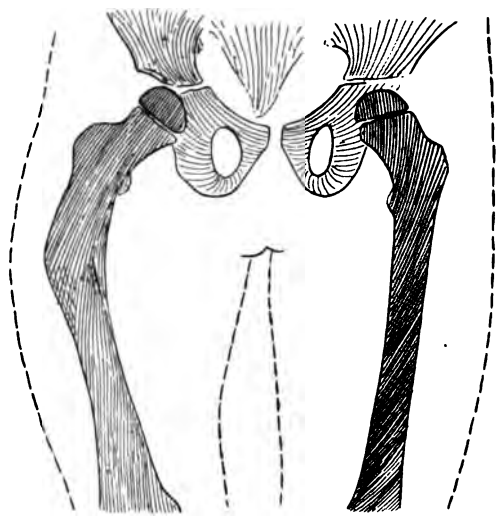

Fig. 393.—Fracture of the upper third of the shaft of the right femur (X-ray tracing).

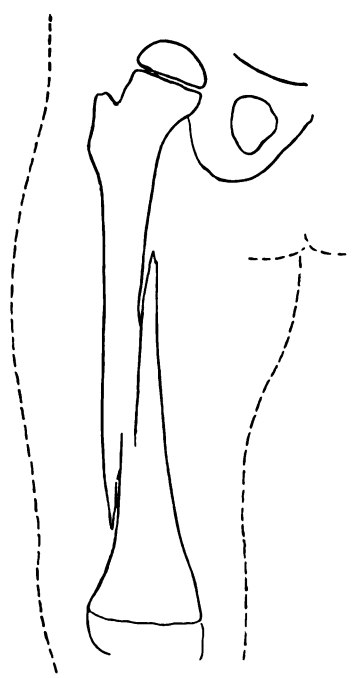

Fig. 394.—Long oblique fracture of the shaft of the femur (Massachusetts General Hospital, 1250. X-ray tracing).

emergency work small pillows or coats or shawls may be utilized. It is important that the padding be evenly and intelligently arranged. It will be necessary to place a wide pad between the upper end of the long outside splint, to prevent it from pressing upon the ribs and side of the chest and causing great discomfort. These splints are held in position about the leg, while gentle trac-

Fig. 395.—Fracture of the thigh. Correct method of measurement from the anterior superior spinous process of the ilium. Position of thumb and finger holding tape.

Fig. 396.—Measurement of lower extremity. Position of thumbs shown. Note position of limb.

tion is being made upon the limb, by straps or pieces of bandage placed above the ankle, below the knee, above the knee, at the middle of the thigh, and at the level of the perineum. The upper end of the long outside splint is held to the side by a swathe about the body and splint. The patient should then be carefully placed upon a stretcher (a Bradford frame is an ideal form of stretcher)

improvised for the occasion. With this apparatus snugly applied, the patient may be securely and comfortably transported.

The objects of treatment are to reduce the fracture, to maintain the reduction immobilized until union is firm, and to restore the leg to its normal usefulness. In the treatment of two of the three varieties of fracture of the femur permanent traction upon the lower fragment and permanent countertraction upon the upper fragment are necessary.

Fig. 397.—Measurement of lower extremity. Patient lying on the back looked at from above. Position of tape, hands, and limb to be noted.

The patient with a fractured thigh should always be anesthetized before putting the thigh up permanently. Never anesthetize the patient until all the different parts of the apparatus are ready and on a table near the bed of the patient. Always put the thigh up in temporary dressings until all is prepared for the permanent splints. About one hour will be consumed in applying the extension apparatus after the patient is anesthetized. There will be no harm in letting the patient rest comfortably in the temporary

splints over one night until all necessary arrangements have been made for the permanent dressing.

Method of Examination: The patient is completely anesthetized in order to secure muscular relaxation. Accurate examination is

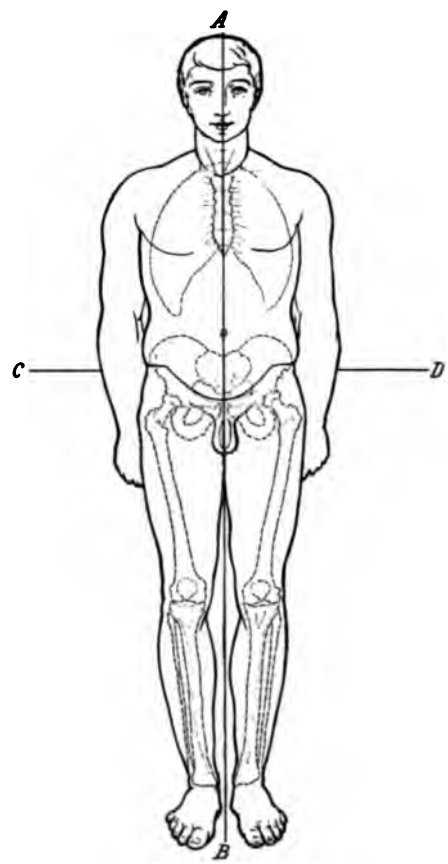

Fig. 398.—Measurement of the length of the lower extremity. Patient represented lying on back, looked at from above. The line joining the anterior superior spinous processes of ilia (*C*, *D*) should be at right angles to the long axis of the body (*A*, *B*). In this position only can comparable measurements be made (Drawn by C. Rimmer.)

now made of the fracture. If the ends of the fragments lie close to the skin, great care must be exercised, by steadying the thigh, to prevent them being pushed through the skin and thus rendering the fracture an open one. An assistant should steady the pelvis

and upper thigh (see Fig. 400). The surgeon should grasp the thigh above the condyles with both hands, and should make traction in the axis of the limb. He then determines the pull necessary to be exerted to hold the fragments reduced. While this pull is maintained by an assistant, the surgeon manipulates the thigh in order to learn with what ease or difficulty the fragments may be held in position.

In adults in fracture of the middle of the shaft of the femur traction and immobilization are best maintained by a modified Buck's

Fig. 399.—Fracture of hip or thigh. Emergency apparatus.

Fig. 400.—Fracture of the thigh. Method of holding leg in order to detect fracture of the thigh. Pelvis is steadied by an assistant.

extension apparatus. Materials needed for a modified Buck's extension: Two strips of *adhesive plaster*, each two inches wide and long enough to extend from the seat of fracture to the internal malleolus. Surgeon's adhesive plaster is nonirritating to the skin, and is prepared in rolls of convenient width. To each strip of plaster at the ankle end should be stitched a piece of webbing the width of the plaster and about six inches long. Prepare five other strips of adhesive plaster, all of which should be one and a half inches wide. Three of these strips should be long enough to encir-

cle respectively the leg above the malleoli, the knee above the condyles, and the thigh an inch below the seat of the fracture. The remaining two strips of plaster should be long enough to extend spirally from the malleoli around the leg and thigh to the seat of fracture. Prepare also a *roller bandage* of gauze or cotton cloth, a curved or straight *ham-splint* properly padded, and three adhesive straps for holding the ham-splint.

In addition, three *coaptation splints* for surrounding the thigh are required, also six webbing *straps* with buckles or strips of bandage to be used as straps; fresh *sheets* or pillow-cases or towels for

Fig. 401.—Pulley arranged on broom-handle to be fastened at foot of bed for carrying extension cord.

padding; a *swathe*, to encircle the pelvis, made of unbleached cotton cloth or medium weight Shaker flannel; and a long outside *splint of wood*, four inches wide, to extend from the axilla to six inches below the sole of the foot. To this last a cross-piece, eighteen inches long, should be fastened, making thus a long T-splint. The list is completed by two *towels* for perineal straps, *safety-pins*, a *pulley*, which can be bought at little cost at any hardware store (see Fig. 401). This pulley should be screwed into a *broom-handle* cut to the right height. A block with hooks above and a pulley below will sometimes be found to be more convenient than the

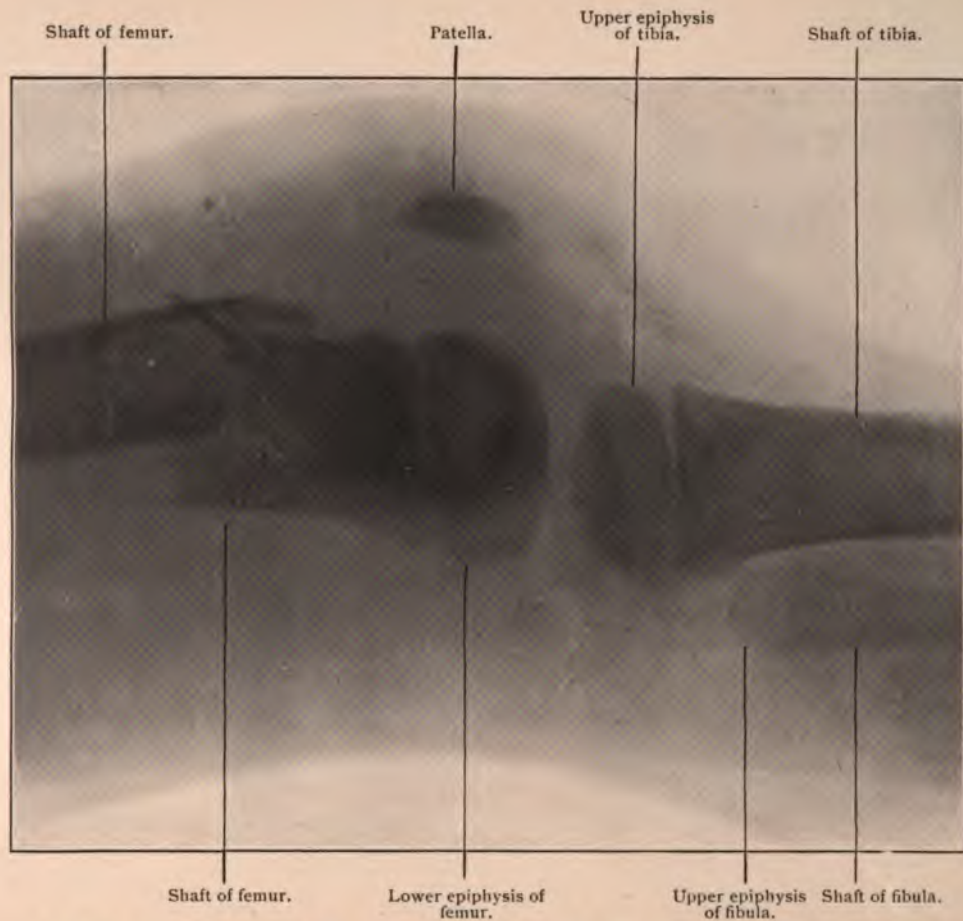

Fig. 402.—Case: Boy 8 years of age. Supracondyloid fracture of the femur. Note splintering of fragments. Displacement of fragments. Epiphyses of lower end of femur and upper ends of tibia and fibula. Note patella. Impaction was broken and the deformity corrected.

broom-handle arrangement (see Fig. 403). A *spreader* (see Fig. 404), which is a piece of wood two inches wide and a little longer than the width of the foot, perforated at its center for the extension weight cord. There should be provided a *cord*, three feet long, size of a clothes-line; *two bricks* or wooden blocks for elevating the foot of the bed; four *sand-bags*, twenty inches long and six inches wide; a *cradle* (see Figs. 405, 406) to keep the weight of the clothes from the thigh—the cradle may be a chair tipped up, or barrel-hoops nailed together.

Application of the Modified Buck's Extension.—All the materials being in readiness and at hand, the patient having been etherized and the fracture examined, the thigh and leg and foot are first

Fig. 403.—Pulley arranged for bed.

washed with warm water and Castile soap and thoroughly dried. The long straight strips of adhesive plaster with the webbing attached are applied to the middle of the two sides of the leg and thigh up to the seat of fracture. The junction of the adhesive plaster and webbing should be brought to just above the malleoli. The two spiral and then the three circular strips should next be applied as indicated (see Fig. 407). Over the extension is placed a roller bandage, snugly and evenly inclosing the foot. The bandage steadies the adhesive plaster, prevents swelling of the foot, and affords comfort. Then the padded posterior coaptation or ham-splint is applied and held by three straps of adhesive plaster, one at each end of the splint and one below the knee (see Fig. 408). If the curved ham-splint is used, the padding (one sheet of sheet

wadding) should be laid upon the splint evenly throughout. If a straight ham-splint is used, the padding should be applied evenly, and at the middle of the ham, behind the knee, should be placed an additional pad (see Fig. 409) in order to support the knee in its natural position. This additional pad should be placed between the splint and the layer of sheet wadding. The tendency of the padding of the ham-splint is to slip away from each end of the splint and thus leave it unduly pressing into the thigh and calf. It is wise to hold this padding in place by strips of adhesive plaster at

Fig. 404.—Spreader of wood for preventing extension straps from chafing ankle and foot. Cord for attaching weight.

each end of the splint. The three thigh coaptation splints should be next put in position—one anteriorly, extending the whole length of the thigh from groin to patella; one externally, extending from trochanter to external condyle; and one internally, extending from just below the perineum to just above the adductor tubercle (see Fig. 409). The best padding for these splints is a towel folded the length of the splints and placed evenly about the thigh. These splints are held by an assistant while three or four straps are tightened sufficiently to hold them firmly in place. While these coaptation splints are being applied it is very important that steady

traction be made upon the lower fragment in order to maintain its reduction. The straps of the coaptation splints are then finally tightened. The long outside splint with the T cross-piece is then padded with sheets and applied to the side of the limb and the body (see Fig. 410). The upper end of the splint is inclosed in a swathe, which passes around the body and is fastened with safety-pins. The thigh and leg are held steadily to the outside splint by

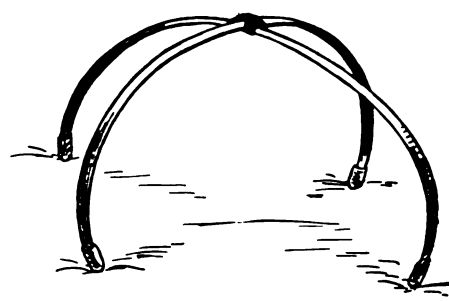

Fig. 405.—Cradle to keep clothes from leg. Made from two barrel-hoops.

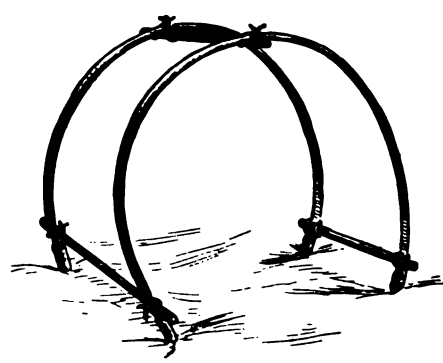

Fig. 406.—Cradle to keep clothes from leg. Made from two barrel-hoops.

two or three straps (see Fig. 411). The assistant, making extension, exchanges his traction for that of the weight and pulley. The foot of the bed is raised upon blocks or bricks, in order to provide the counterextension by means of the weight of the body. The heel is protected from undue pressure by a ring. The foot is kept at a right angle with the leg (see Figs. 412, 413). The sand-bags are laid along the inner and outer sides of the limb to add greater

Fig. 407.—Fracture of the thigh. Adhesive-plaster extension strips; long upright, circular, and obliquely applied strips.

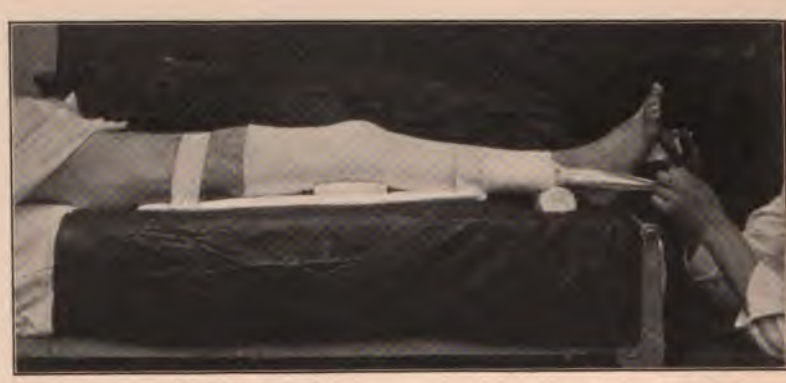

Fig. 408.—Fracture of the thigh. Extension strips applied, covered by bandage. Ham-splint applied; two straps and pad in ham.

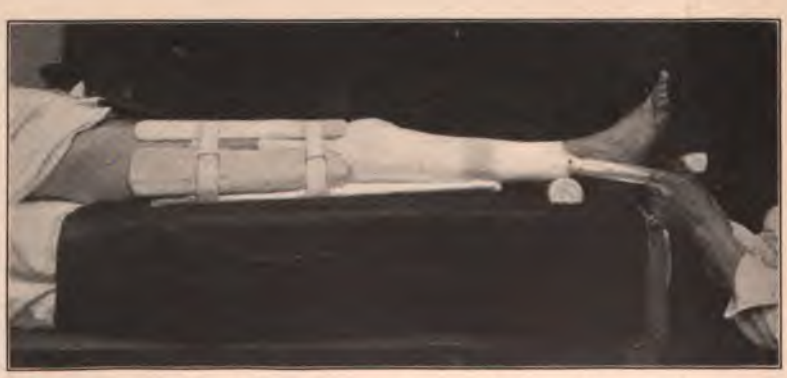

Fig. 409.—Fracture of the thigh. Extension strips applied. Cotton bandage. Ham-splint, straps, pad, and coaptation splints about the seat of fracture. Straps and buckles.

steadiness to the apparatus. The cradle is placed over the foot and leg.

Throughout the course of the treatment of a fracture of the thigh it is necessary to be positive of four things: (*a*) The absence of shortening in the injured thigh; (*b*) the prevention of outward bowing of the thigh; (*c*) the prevention of permanent rotation of the leg and lower thigh outward below the seat of fracture; and

Fig. 410.—Fracture of the thigh. Completed apparatus as in figure 409, and in addition a long outside T-splint, straps, and swathe. Weights applied.

Fig. 411.—Fracture of the thigh. Completed apparatus with bed elevated. The outside splint is broad and without the T foot-piece. The swathe is very snugly applied.

finally (*d*), the prevention of a sagging backward of the thigh at the seat of fracture, causing what appears on standing as a false genu recurvatum.

(*a*) The shortening of the injured leg is prevented by a sufficiently heavy weight for extension. This weight can be approximately but not accurately determined. Ordinarily, in an adult fifteen or twenty pounds are needed to hold the fragments in proper position. Comparative measurement of the legs from the



Fig. 412.

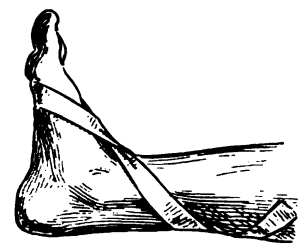

Fig. 413.

Figs. 412, 413.—Forms of stirrup to prevent the foot assuming an equinus position.



Fig. 414.—Diagram of section of leg and splint to show how a strap carried from the back of the leg over the long side-splint can prevent eversion of the foot and leg.

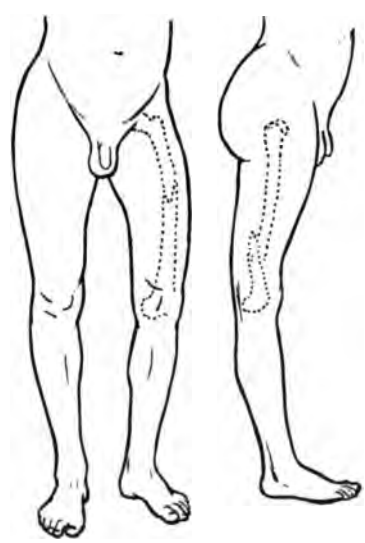

Fig. 415.—The more usual deformities in fracture of the shaft of the femur. Outward and posterior bowing.

anterior superior spinous process to the malleolus should be made regularly every other day, and the measurements recorded during the first two weeks of immobilization and the extension weight correspondingly adjusted.

(*b*) In order to prevent any outward bowing of the thigh, the

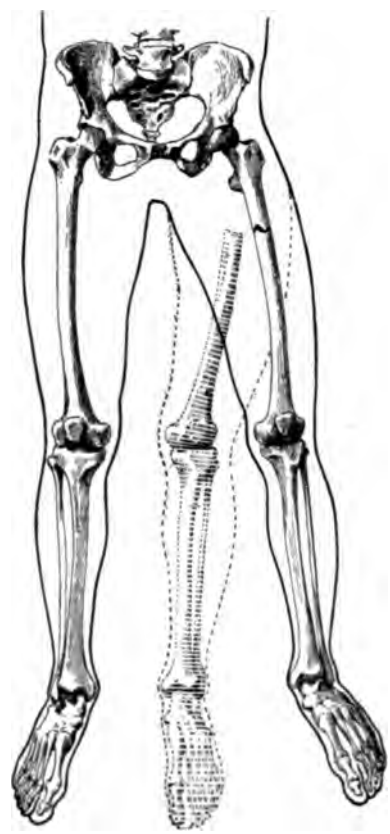

Fig. 416.—Showing the necessity of abducting the injured leg in thigh fracture. In dotted line is shown the position likely to result from neglect of this abduction.

thigh and leg should be slightly abducted after the apparatus is applied, so that the extension is made with the limb in this abducted position (see Fig. 416).

(*c*) In order to prevent the thigh from rotating outward below the fracture and thus carrying the leg and foot with it,—to prevent, in other words, eversion of the foot,—a bandage six inches

wide should be fastened by pins below the calf of the leg to the posterior part of the bandage or ham-splint, and brought up on the outer side of the leg and fastened to the long outside splint or to the cradle above. The leg meanwhile is held in the corrected

Fig. 417.—Action of the muscular pull of the iliopsoas and of the external rotators in producing deformity in fracture of the femur high up. Upper fragment is flexed and abducted upon the trunk.



Fig. 418.—Case: Oblique subtrochanteric fracture of shaft of femur (X-ray tracing).

position. If this bandage is fastened to the cradle, the latter should be fastened firmly to the bed.

(*d*) The sagging backward of the thigh (see Fig. 415) is prevented by the posterior coaptation splint and its proper padding. (See Supracondyloid Fracture of the Femur.)

Subtrochanteric Fracture of the Shaft of the Femur.—Fractures of the upper third of the shaft are comparatively rare. The diagnosis of this fracture is not ordinarily difficult. The displacement is characteristic: The upper fragment is flexed and abducted, and the lower fragment overrides the upper one and is slightly adducted. The treatment should restore the line of the thigh. At times the ordinary extension and counterextension, as for a fracture of the middle of the femur, may prove effective. If it is



Fig. 419.—Spiral fracture of the shaft of the femur high up (X-ray tracing).

Fig. 420.—Spiral fracture of the upper half of the femur. View from in front and externally (Warren Museum, specimen 1103).

not effective,—and it usually is not,—the leg and lower fragment should be elevated upon an inclined plane (see Fig. 434), so as to bring the lower fragment up to the upper one, for it will be found impossible to lower the upper fragment. Traction should then be made in the line of the elevated thigh from above the condyles of the femur. If position and traction are inefficient,—and they usually are,—then suturing of the fragments should be contemplated.

It will be found impossible to correct completely the ordinary

deformity of abduction and flexion of the upper fragment and adduction and riding up of the lower fragment by traction upon the lower fragment, no matter in what position the lower fragment may be placed for traction. Rendering the closed fracture open by incision and suturing the bones in position is the only possible way of securing a perfect result either anatomically or functionally. The surgeon must be judicious in the selection of the patients upon whom he operates. Even though old, if the patient is in excellent

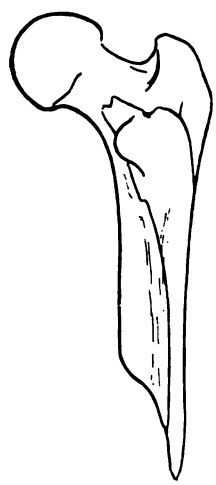

Fig. 421.—Same specimen as figure 420, from behind.

Fig. 422. — Fractured femur, base of neck driven into the shaft. Spiral fracture of shaft just below this (Warren Museum, 6529).

Fig. 423.—Fracture of shaft of femur high up; union with much displacement (Warren Museum, specimen 5993).

general health, the operation may be done with every prospect of success.

Supracondyloid Fracture of the Femur.—The deformity is characteristic and fairly typical (see Figs. 426, 427); displacement of both fragments backward is sometimes seen (see Fig. 432). The upper end of the lower fragment is displaced backward, chiefly through the pull upon it by the gastrocnemius muscle.

Treatment of this fracture in the straight and extended position is usually unsatisfactory. It is necessary either to flex the leg in order to relax the gastrocnemius muscle or to do a tenotomy upon

the tendo Achillis. One of these procedures having been carried out, the thigh and leg should then be placed upon a double inclined plane (see Fig. 434). Pressure by pads may be exerted upon the upper end of the lower fragment in order to lift it forward into apposition with the upper fragment. Slight traction, if possible, should be maintained upon the lower fragment. Repeated examinations with the fluoroscope will indicate when reduction is completed.

The After-treatment and Progress of Fracture of the Thigh.—Inspection of the fractured limb should be made at least daily.

Fig. 424.—Fractures of base of neck and trochanters of femur. View from behind and inner side (Warren Museum).

Fig. 425.—Fracture well below trochanters, with a split running upward through great trochanter. Also fracture of neck of bone with displacement of head up and out. Recent case (Warren Museum, specimen 1074).

Measurement should be made twice a week during the first few weeks, the internal malleolus being reached through the bandage. Parts of the apparatus may need changing, and straps may require tightening or loosening. The heel and sacrum will require attention because of the constant pressure from lying in one position.

Ordinarily, there will be little or no pain associated with the repair of the fracture. After about four weeks all apparatus should be removed and the limb thoroughly inspected, to detect, if possible, any uncorrected deformity, and to determine whether union is yet firm. In from four to six weeks repair in a healthy child or

young adult should have advanced to the stage of firm union. The apparatus should then be reapplied. At the end of the eighth week all apparatus should be finally removed. The thigh should be washed and thoroughly oiled. The patient should be permitted to lie in any position in bed without retentive apparatus for one week. After the splints are first left off and while the patient is still in bed daily systematic massage to the whole limb should be practised, together with slight passive and active motion at the knee-joint. The patient should not be allowed to bear weight upon the unprotected thigh until after the ninth week. At the ninth week he should be allowed up and about with crutches, and a moderately high-soled shoe (two inches) should be worn upon the foot

Fig. 426.—Action of gastrocnemius muscle pulling distal fragment backward and downward.

of the uninjured thigh. He should bear no weight upon the injured leg. The seat of the fracture should be protected by coaptation splints and straps and a light spica plaster-of-Paris bandage from the toes to above the waist. At the end of twelve weeks all support may be discarded. Of course, fractures of the femur vary considerably in the time the patient is able to get about, but the foregoing routine is that of average uncomplicated cases.

It is very probable that massage without any passive motion, as early as the second week, to the region of the knee and thigh, will prevent much of the knee-joint disability and muscular atrophy that so often hinder convalescence in these cases. It is very important also, in order to gain this end, to see that the extension is

made from around and above the condyles of the femur and not, as so often happens, from the knee-joint itself. It ought to be possible to avoid all knee-joint stiffness by the judicious use of massage to the whole limb and passive motion to the knee-joint. These measures in many cases should be instituted and practised regularly and persistently and always cautiously from the second week after the injury.

The ambulatory treatment of fracture of the thigh by means of the long Taylor hip traction splint, a high sole upon the shoe worn on the well foot, and crutches, is of very great value, especially in children and young adults. The hip-splint, consisting of a long outside upright, pelvic, thigh, and calf bands, is applied with two

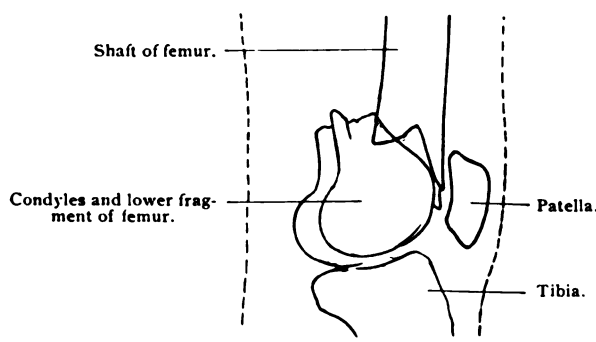

Fig. 427.—Low fracture of the shaft of the femur. Displacement of the lower fragment backward by the gastrocnemius muscle, and of the upper fragment forward. Overlapping of fragments.

perineal straps (see Figs. 435, 436). The traction is made through the windlass at the foot-piece after fastening the extension strips to it. The countertraction is made by the two perineal straps. The thigh is securely held by coaptation splints and a bandage about the thigh and splint. The patient goes about with crutches and a high sole of two inches upon the shoe worn on the well foot, bearing a little weight upon the foot of the splint. As a matter of fact, the real value of this method in fracture of the thigh lies in the improvement to the general health by the early getting into the upright position and out of bed. This application of the ambulatory method certainly is of great comfort to the patient. That it hastens the reparative process is yet to be fully demonstrated. If

the Taylor hip-splint is used, it should be applied when union is found to be firm. After wearing the splint in bed for a few days the patient may get up and be about.

The Prognosis.—What shall be considered a satisfactory result in the treatment of a closed fracture of the shaft of the femur? The degree of restoration of function can not be determined with accuracy until about one year has elapsed after treatment is suspended. The following six requisites for a satisfactory result following fracture of the femur are those reported by a committee

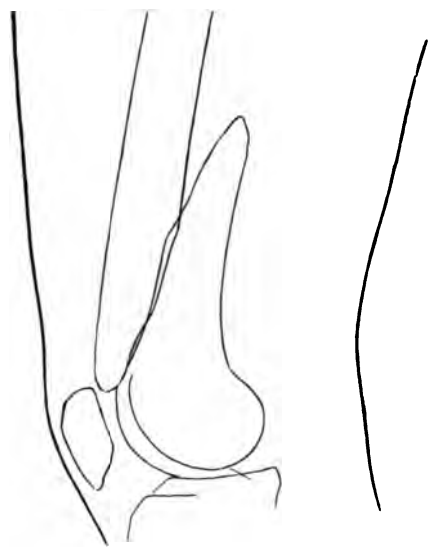

Fig. 428.—Lateral view. Oblique fracture of the shaft of the femur low down. Little backward displacement of lower fragment. Considerable shortening of thigh from forward displacement of upper fragment. Man aged forty. Recovery.

from the American Surgical Association, and generally accepted as forming a good working basis.

For a result to rank as a good one, it must be established that firm bony union exists; that the long axis of the lower fragment is either directly continuous with that of the upper fragment or is on nearly parallel lines, thus preventing angular deformity; that the anterior surface of the lower fragment maintains nearly its normal relation to the plane of the upper fragment, thus preventing undue deviation of the foot from its normal position; that the length of

the limb is exactly equal to its fellow or that the amount of shortening falls within the limits found to exist in ninety per cent. of healthy limbs—namely, from one-eighth to one inch; that lameness, if present, is not due to more than one inch of shortening; that the conditions attending the treatment prevent other results than those obtained.

Results After Fracture of the Thigh.—The prognosis as to the usefulness of the thigh after fracture deduced from the statistics available is of little value, because the details of the cases are not

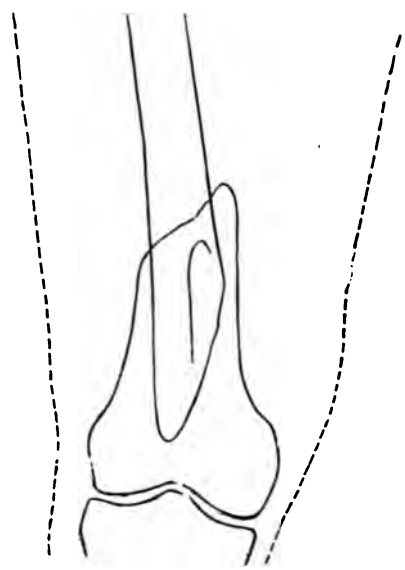

Fig. 429.—Same as figure 428. Anteroposterior view.

presented nor is any discrimination made between the seats of fracture and the ages of the patients. Realizing these facts, I have very carefully examined and classified the final results several years after treatment had ceased in thirty-five cases of uncomplicated fracture of the shaft of the femur treated at the Massachusetts General Hospital. The treatment in all cases was practically the same: a Buck's extension with outside T-splint, or a long Desault apparatus, and, toward the end of treatment, a plaster spica of the thigh, groin, and trunk, with crutches. Even though this number of cases is relatively small, yet, after having most care-

fully analyzed them, it seems highly probable that even if this number should be increased, the ultimate results would not materially differ. These thirty-five cases have been arranged in three groups, according to age: (*a*) Those of childhood; (*b*) those

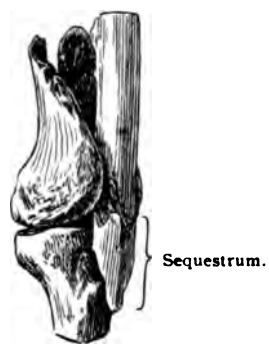

Fig. 430.—Oblique fracture of the shaft just above the knee, with splitting apart of the two condyles. Extreme displacement; necrosis of tip of upper fragment. Patient a man of thirty-seven years, lived for five months (Warren Museum, specimen 1118).

Fig. 431.—Same as figure 430, view from behind.

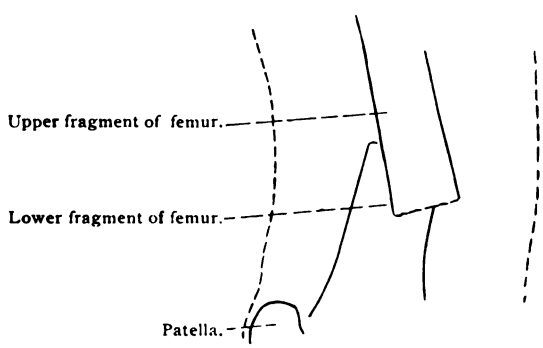

Fig. 432.—Transverse fracture of the femur in the lower third with backward displacement of both fragments. Lateral view.

of adult life; and (*c*) those of old age. (*a*) Fourteen cases occurred *in childhood*, the ages averaging seven and a half years. Patients were heard from or reported for examination one and a half to seven years after the original injury. All cases were treated by bed extension, coaptation splints, and the plaster spica to thigh

and hip. All have perfect functional results. Four cases mention slight pain occasionally. Three of these four cases have a little stiffness of the knee upon the injured side one and a half years after the accident, three and a half, and three years respectively. (*b*) Sixteen cases occurred *in adults* whose ages ranged from eighteen to forty-eight years. These were seen or reported from one to six years after the original injury. Five of these have unqualifiedly perfect results, without pain or stiffness. The remaining eleven cases have limited knee-joint movements, aching in the thigh, pain

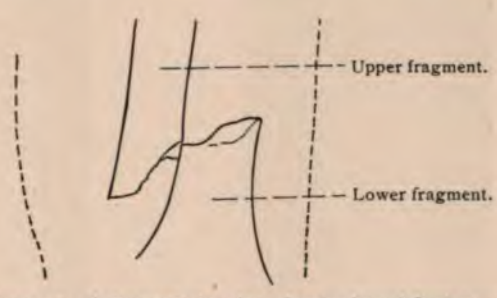

Fig. 433.—Same as figure 432. Anteroposterior view, showing lateral displacement.

Fig. 434.—Diagram of double inclined plane for fractures near the lower end of the femur. Secures good position through relaxation of gastrocnemius muscle and pads beneath lower fragment.

after exercising, pain in wet weather, weakness in the whole leg, and slight lameness in walking. (*c*) Five cases occurred during *old age*. The patients averaged fifty-eight years. These were seen or reported from two to six years after the original injury. None has functionally perfect results. There is one case of non-union of the thigh with shortening of the limb. Two cases must use a cane in walking. The knee is painful and motion is limited in all cases. Swelling of the leg is not uncommon, and pain in wet weather is very commonly complained of by these old people.

Considering these reported cases individually and grouped according to the three age periods, it seems reasonable to conclude that they form a basis for a fairly accurate judgment as to the probable outcome of these injuries to the shaft of the femur. As the age increases the liability to impairment of the function of the limb increases. This liability is very great after fifty years are passed.

Fig. 435.—Fracture of the thigh. Convalescent ambulatory splint without traction.

Fig. 436.—Fracture of the thigh. Convalescent ambulatory splint without traction. Coaptation splints may be applied to the thigh and held by straps inclosing the splint.

It is not very uncommon, even in closed fractures of the femur, to find gangrene of the leg developing because of laceration or pressure upon the great vessels of the limb. Early amputation of the thigh just above the fracture will be necessary in these cases. It should be done early in order to save life. In the aged the shock of the accident may prove fatal. In open fractures the violence,

usually direct, has been so great that the soft parts about the knee and throughout the whole thigh have been greatly torn and lacerated on either side of the fractured bone. The shock in these cases is severe. Recovery is always doubtful.

Fracture of the Thigh in Childhood.—This is usually caused by direct violence. The fracture is often incomplete. The symptoms are those of the same fracture in the adult. The effusion

Fig. 437.—Fracture of the left thigh at the middle. Union solid. Convalescence hastened by use of hip splint with fixation of thigh by coaptation splints and straps.

into the knee-joint is seen perhaps more uniformly than in the adult. This effusion disappears from the child's knee-joint more quickly than from the adult knee-joint.

Treatment.—After reducing the fracture,—making the incomplete fracture complete if perfect reduction can not be accomplished in any other way,—the problem of maintaining the reduction arises.

In children of ten years and older it is possible to use the Buck's extension. A plaster-of-Paris spica splint from the calf of the leg to the axilla is also a possible method of immobilization.

In children under ten years of age the Cabot posterior wire frame with coaptation splints and extension is the very best method of conveniently and efficiently treating a fractured thigh or fractured hip.

The Cabot Posterior Wire Splint (see Fig. 438): The splint consists of two portions—a body part and a leg part. The patient lies upon the body part with the thigh and leg resting upon the leg part, as upon a coaptation splint. Having a vise and simple iron wire the size of an ordinary lead-pencil, this splint can be made in a few moments; the bending of the wire according to the diagram and fastening the free ends by a strip of small-sized wire being all that are required. It is necessary to make the following measurements before bending the wire to the general shape shown in the diagram—namely, D E, the distance from the axilla to the calf of the leg; A D, the width of the trunk; A B, from the axilla to a point midway between the crest of the ilium and the top of the great trochanter; F E, the width of the leg, usually from two to two and a half inches. A D and B C are bent to the curve of the back. B C is so bent that it jumps over the sacrum and does not touch posteriorly excepting at B and C. The long rods are so bent as to adapt them to the posterior curves of the buttock, thigh, popliteal space, and leg (see Fig. 439). The splint is covered, as in the posterior wire splint for the leg, by layers of sheet wadding and cotton bandages. A swathe is attached to the two sides A B and D H of the body part (see Figs. 438 and 440). The child is carefully laid upon this splint, the body swathes adjusted, the extension strips applied, traction made by weight and pulley with the foot of the bed elevated, coaptation splints applied and held in position by straps that include the posterior wire splint. If it is necessary to move the child for the

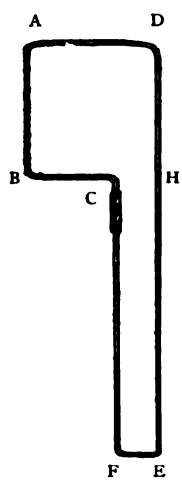

Fig. 438.—Cabot wire splint for fracture of the hip and thigh.

making of the bed, for the use of the bed-pan, or for bathing, the extension may be unfastened temporarily without any injury to the fracture, particularly if the coaptation splints are then temporarily tightened to secure a firmer hold on the thigh. The child

Fig. 439.—The Cabot wire splint ready for use. Lateral view, showing curves of splint corresponding to small of back, buttock, and knee.

Fig. 440.—The Cabot wire splint ready for use. Front view, showing covering of Canton flannel and Canton-flannel double swathe for fixation to chest.

should be, of course, clean from both urine and feces, and the fracture immobilized.

After four weeks of bed-treatment the child may be up, with crutches and a high shoe with the Cabot splint applied. Shoulder-

straps should be attached to the splint when it is worn in the erect position. This is one of the simplest, cleanest, and most efficient methods of treating fracture of the thigh in young children. The child can be moved with freedom and without pain. A light plaster-of-Paris spica bandage may be used in convalescence with crutches and a high shoe on the uninjured side.

Fig. 441.—Bradford bed-frame for fixation of trunk in fracture of the thigh.

Fig. 442.—Fracture of thigh in a child. Bradford frame. Vertical suspension of leg with weight and pulley. Coaptation splints to thigh and fixation of pelvis by towel swathe about frame.

In very small children it is sometimes wise to use the Bradford (see Fig. 441) frame and vertical suspension (see Fig. 442) of one or both thighs. This is an efficient, comfortable, and clean method of treatment. The Bradford frame is an iron, frame-like stretcher, on which the child lies and to which the shoulders and hips are fastened to prevent the child's moving about. Counterextension

is then secured by the immobilization of the pelvis and hip. The extension is applied to the thigh and leg as usual. The limb is flexed on the body to a right angle, coaptation splints being applied to the thigh. After the novelty of the position passes away, the child is perfectly contented. As soon as union is firm, the permanent plaster spica dressing may be applied, and the patient may be up and about with high shoe upon the well foot and with crutches. The use of the long hip-splint will be of great service

Fig. 443.—Old fracture of the thigh with deformity. Due to use of unprotected thigh before complete consolidation of fracture (Warren).

in these cases either with or without the extension foot-piece (see Figs. 435, 436). After fracture of the shaft of the femur in children there should be no shortening and no special difficulty in convalescence. It is wise to guard the thigh a sufficient time after union is firm to insure absolute solidity and freedom from bowing in any direction (see Fig. 443).

The Making of the Bradford Frame.—It is most easily made from $\frac{3}{8}$- to $\frac{1}{4}$-inch gas piping. It should be one inch wider than

the width of the hips, and six inches longer than the height of the child. It should be covered with canvas, so as to leave a space under the buttocks for the use of the bed-pan.

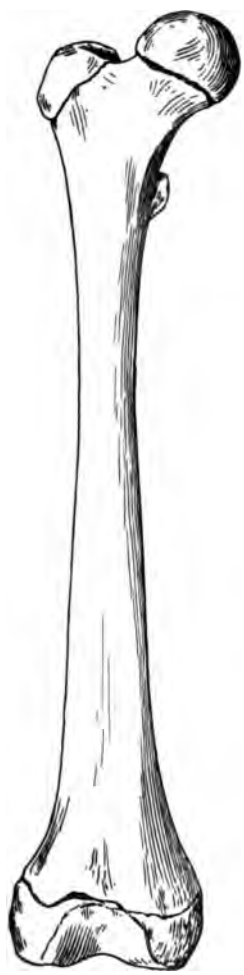

Fig. 444.—Femoral epiphyses at fifteen years. Note relations of lower epiphyseal line to inferior articular surface.

SEPARATION OF THE LOWER EPIPHYSIS OF THE FEMUR

Anatomy.—The lower epiphysis of the femur is the largest of the epiphyses. It unites with the shaft of the bone at or about the twenty-first year. The epiphysis includes the whole of the articular surface of the lower end of the femur. The points of origin of the gastrocnemii muscles are situated upon the epiphysis; a few fibers only arise from the diaphysis. The inner condylar line of the femur is continuous with the inner lip of the linea aspera, and terminates at the adductor tubercle, which can be palpated upon the inner side of the thigh near the knee-joint. The upper and outer angle of the trochlear surface of the femur can be palpated best with the knee flexed. A line drawn from this angle of the trochlear to the adductor tubercle marks the level of the lower epiphysis of the femur (see Fig. 444). In no position of the knee-joint are the bones in more than partial contact. This is one of the superficial joints of the body. The strength of the joint lies in the ligaments and fasciæ about it. Unlike the elbow- and hip-joints, it does not depend upon the contour of the bones for strength. An attempt to overextend and to bend the knee laterally brings very great strain to bear upon the ligaments that are attached to the lower femoral epiphysis. If this strain is

of sufficient force, the epiphyseal cartilage gives way, and the epiphysis separates from the shaft of the femur. The common cause of the accident is the catching of the leg or thigh in the spokes of a revolving wheel. The accident most often occurs to boys about ten years old (see Figs. 445, 446).

The epiphysis usually separates without splintering the diaphysis. The periosteum is stripped for a considerable distance.

Fig. 445.—Case: Boy, eleven years of age. Separation of the lower femoral epiphysis. Photograph taken four hours after the injury. Note inversion of the limb; fullness of lower third of thigh posteriorly; fullness over head of tibia; fullness in popliteal space (X-ray tracing, Fig. 447, explains the evident deformity).

Fig. 446.—Case same as figure 445. Separation of the lower femoral epiphysis of the left leg. Contrast two knees (see X-ray tracing, Fig. 447).

About half the cases are open, the end of the diaphysis projecting through the skin of the popliteal space. The knee-joint is usually unopened. There may be almost no displacement of the fragments. A lateral sliding of the epiphysis has often been observed. One condyle has been found in the popliteal space, but commonly the epiphysis lies in front of the shaft of the femur with its separated surface in contact with the shaft (see Figs. 447, 448, 449). The diaphysis is displaced backward and downward into the popli-

teal space, because of the possible high attachment of the gastrocnemii and the fracturing force. The nerves of this region may be pressed upon or lacerated, and this may be the cause of great pain attending the accident. The popliteal vessels may be compressed, stretched, or even ruptured. Consequently, interference with the circulation may result. This may be moderate and temporary, or extreme and result in gangrene of the leg. The shock attending this accident is often great. Suppuration may appear in closed separations, although it is infrequent; it is much more

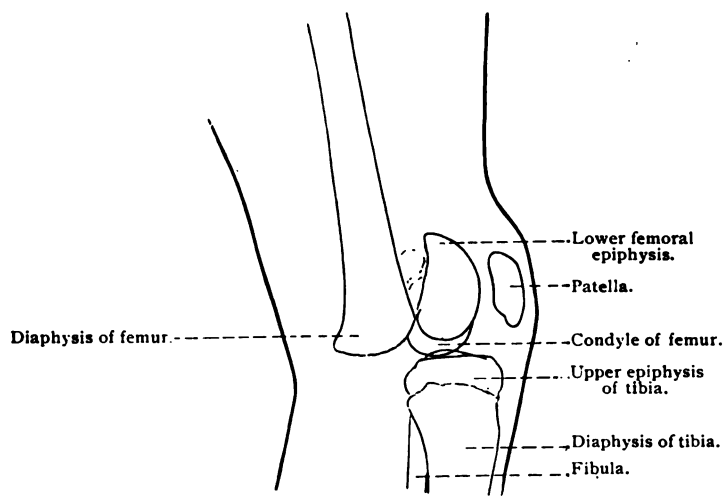

Fig. 447.—Lateral view. Case of figure 445. Boy, aged eleven years. Separation of the lower femoral epiphysis. Displacement forward of epiphysis and backward of lower end of shaft (see Figs. 445, 446. X-ray tracing).

likely to appear in open lesions. Sloughing of the skin is not unusual from the bony pressure. Gangrene of the leg sometimes occurs. Necrosis of bone is not unlikely to result, particularly if the separation of the periosteum is great (see Fig. 450).

Diagnosis.—After severe trauma to the region of the knee there are three injuries that should be considered possible: a dislocation of the knee-joint, a supracondyloid fracture of the femur, or a separation of the lower epiphysis of the femur.

There may be so much swelling that a satisfactory examination is impossible. Ordinarily, careful palpation will detect the bony

outlines of a dislocation. This is extremely rare in children. The crepitus of a supracondyloid fracture is bony and hard, and the displacement of the distal fragment into the popliteal space evi-

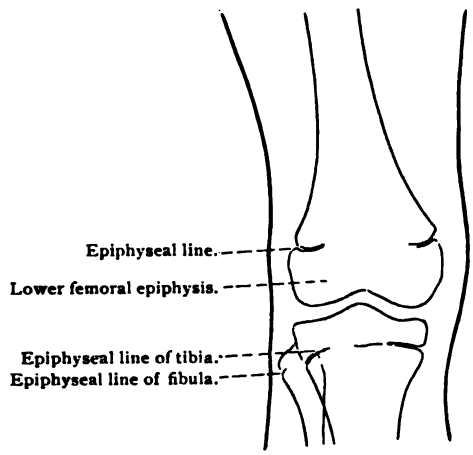

Fig. 448.—Same case as figure 447. Anteroposterior view of uninjured knee in a child eleven years of age, showing epiphysis in position (X-ray tracing).

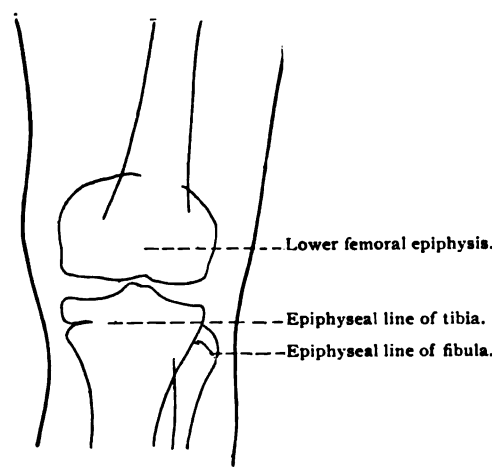

Fig. 449.—Same case as figure 447. Anteroposterior view of displaced lower femoral epiphysis in a boy eleven years old.

dent. All fractures at the knee are not necessarily supracondyloid. Several cases of fracture of one condyle of the femur into the joint are reported. The separated epiphysis itself may be split

through into the joint. A severe trauma to the knee, a cart-wheel accident to a young boy, attended by considerable shock, followed by great swelling of the knee, a fullness in the popliteal space, feeble or absent pulsation in the dorsalis pedis and posterior tibial arteries, increased lateral and anteroposterior mobility at the knee, and soft crepitus form the picture characteristic of a separation of the lower femoral epiphysis.

Prognosis.—It is impossible to state positively that in any given case there will or will not be shortening of the leg upon the injured

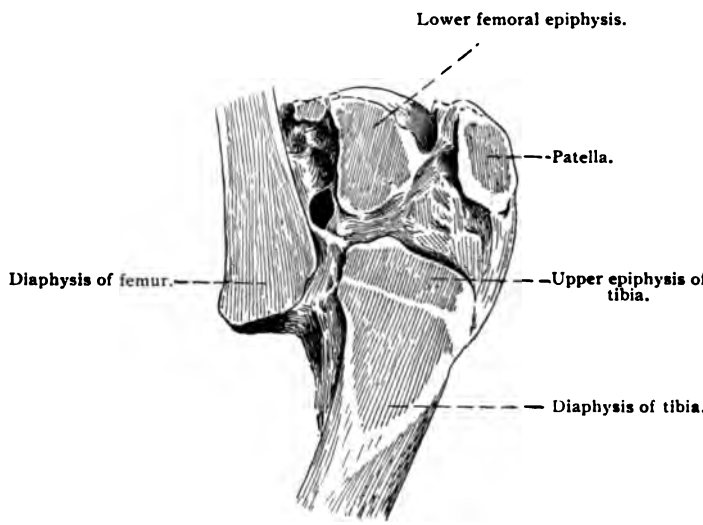

Fig. 450.—Separation of lower epiphysis of the femur with displacement forward and upward between femoral diaphysis and patella (Warren Museum, 8116-1).

side because of a cessation of growth in the femoral epiphysis. If the epiphysis is separated without great laceration and periosteal denudation and is replaced soon after the injury, the chances are that there will be a minimum amount of shortening of the affected leg. After open incision and replacing of the epiphysis in closed fractures good results are to be expected as far as the usefulness of the joint is concerned. Slight necrosis of bone may attend convalescence. If the separation is closed and reduction is impossible by manipulation alone, open incision should be made.

Treatment.—If the vessels are torn; if there is great laceration

of the soft parts, amputation should be performed. If the separation is open and the shaft of the femur protrudes through the wound, and much of the diaphysis is seen to be denuded of periosteum, the diaphysis should be resected to the limit of periosteal separation, and then the bone reduced. It may be necessary to enlarge the opening in the soft parts before it is possible to reduce the bone. If the separation is closed, reduction by manipulation should be attempted; if successful, the leg should be flexed to a

Fig. 451.—Method of grasping knee to reduce a displaced femoral epiphysis. Note thumbs at anterior border of epiphysis and fingers upon the lower end of the femoral diaphysis.

right angle or an acute angle and immobilized in a plaster-of-Paris splint.

Reduction by Manipulation When the Fragment is Displaced Forward.—While an assistant makes traction upon the leg, the surgeon, grasping the thigh above the condyles with the fingers in the popliteal space, making pressure on the upper fragment, pushes with his two thumbs upon the upper border of the displaced epiphysis (see Fig. 451). The leg is gradually flexed. If the reduction is achieved, a soft grating sensation will have been felt, and the shortening of the leg that existed previous to reduction will disap-

pear. The contour of the knee will assume a somewhat normal appearance.

The Operative Method of Reduction.—The obstacle to reduction is no single band or obstruction, it is the retraction and tension maintained by the fasciæ, ligaments, and muscles of the thigh upon the tibia. This retraction is so great that the tibia is held crowded against the lower end of the upper fragment, and prevents the replacing of the epiphysis. An incision is best made over the



Fig. 452.—Diagram to show method of reduction of separated femoral epiphysis by incision. Retractors are upon diaphysis and epiphysis, and lines of traction are shown by arrows.

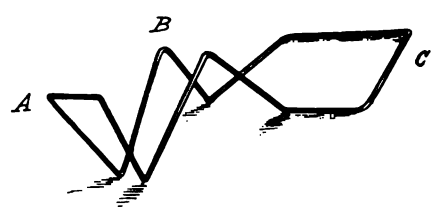

Fig. 453.—Cabot splint arranged as double inclined plane for epiphyseal separation at the lower end of femur. *B*, The part behind the knee-joint, may be bent to a more acute angle; *C*, the body portion, is to be molded to the trunk; *A*, the foot-piece. With the angle at *B* obliterated, the splint may be used for fracture of the leg in childhood.

denuded shaft of the femur on the outer side of the leg. The shaft and the epiphysis are exposed in the wound. Traction should be made by means of periosteal retractors upon the epiphysis, and countertraction upon the diaphysis while the leg is slowly flexed from the completely extended position, as indicated in the figure (see Fig. 450). This will result in the reduction of the displacement. Suture of the bones may be needed to retain the replaced epiphysis in position. The flexed position of the leg will assist

materially in retaining the fragment in position. The application of a light-weight plaster-of-Paris circular bandage from the toes to the groin, with the leg flexed to a right angle, will immobilize the parts.

After-union is firm between the epiphysis and shaft. After three or four weeks the leg may be gradually extended. The foot of the injured leg may be touched to the floor while the plaster splint is in place about five weeks after the injury. Slight weight may be borne upon it. The plaster should be removed after about six weeks, and gentle active and passive motion made at the knee-

Fig. 454.—Case: Boy, aged eleven years. Separation of left lower femoral epiphysis; incision, reduction. Recovery. After six months, useful leg. Knee motion in flexion beyond a right angle as shown (see frontispiece and Figs. 445–450 inclusive).

joint. Massage to the calf of the leg and the thigh should be given daily. A flannel bandage applied to the foot, ankle, leg, and thigh will be all the support that is needed. After about ten weeks the boy should be allowed to step on the foot all he chooses. At first he will do this with fear, but soon with confidence. There will usually be a little limitation of motion in the knee-joint (see Figs. 454, 455).

Traumatic Gangrene, Septicemia, Malignant Edema.—Fractures complicated with laceration of the large vessels are a frequent cause of gangrene. If an acute infectious process starts in a limb with traumatic gangrene, the gangrene spreads with frightful

rapidity. The general disturbance is very great. A septicemia of grave type results. To such cases in which there is much gas formation, associated with edema, and which results in rapid destruction of tissue, the name malignant edema is given. The specific bacillus of malignant edema will be discovered in the blood and tissues far above the wound of the soft parts.

Fig. 455.—Case same as that in figure 454. Separation of lower femoral epiphysis. Note degree of extension possible and cicatrix of incision six months after operation. Note also absence of deformity.

The proper treatment is early high amputation with stimulation of the heart by strychnin and alcohol.

Fat Embolism.—Fat embolism, to a greater or less degree, exists in every case of fracture. It is most evidently present in those cases associated with great laceration of tissue and in open frac-

tures. The soft fat of the medullary tissue is the source of the fat-drops that, getting into the venous circulation, are carried directly to the pulmonary capillaries, where they lodge unless the blood pressure is sufficient to force them out of the lung capillaries on into the systemic circulation. They then lodge in the brain, kidneys, or other organs. The danger in fat embolism is that the patient may die from asphyxiation, due to the imperfect oxygenation of the blood because of the rapid occlusion of the pulmonary capillaries with fat globules.

Symptoms.—Symptoms develop within twenty-four to seventy-two hours after the accident. In fatal cases facial pallor and distress are followed by cyanosis. The patient is first excitable, restless, then somnolent and comatose. Death occurs from asphyxia.

The temperature is usually not elevated. Respiration is rapid. Hemoptysis may exist, associated with pulmonary edema. Fat globules will be found in the urine usually upon the second and fourth days after the accident, for they are eliminated by the kidney.

A difficulty in breathing, cyanosis, and fat found in the urine may be the only evidences of a fat embolism. The prognosis is, of course, dependent upon the extent of the embolism and the strength of the heart. The occurrence of fat embolism is not uncommon. Death from fat embolism is rare.

Treatment.—Stimulation of the heart for its extra work is indicated. Immobilization of the fractured part to prevent more fat from getting into the circulation and the administration of oxygen to relieve asphyxia are important in the treatment.

CHAPTER XIII

FRACTURES OF THE PATELLA

Anatomy.—A knowledge of the anatomical relations of the patella is necessary to a perfect understanding of the fractures to which it is liable (see Fig. 456). Attached to the patella upon its

Fig. 456.—Normal patella: 1, From in front; 2, from behind; 3, from inner side; 4, from outer side; 5, anteroposterior section; *a*, *b*, usual seat of fracture.

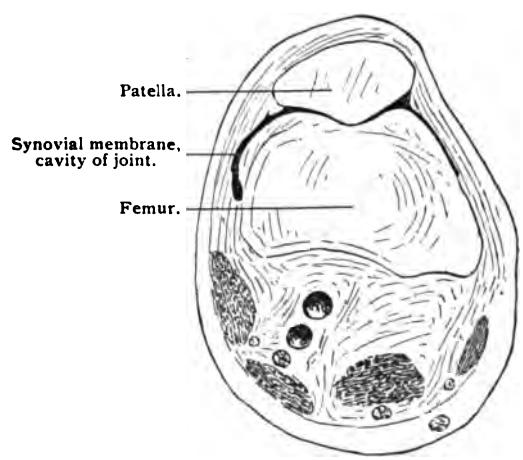

Fig. 457.—Horizontal frozen section of the knee-joint, showing lateral extent of synovial membrane (Professor Dwight's specimen).

upper border is the tendon of the quadriceps extensor muscle. Upon each side of the bone are attached the vastus internus and vastus externus respectively. Below the insertions of the vasti is a portion of the low attachment of the fascia lata of the thigh.

At the lower border of the patella is the patellar tendon. This tendon is inserted into the tubercle of the tibia, and it is separated

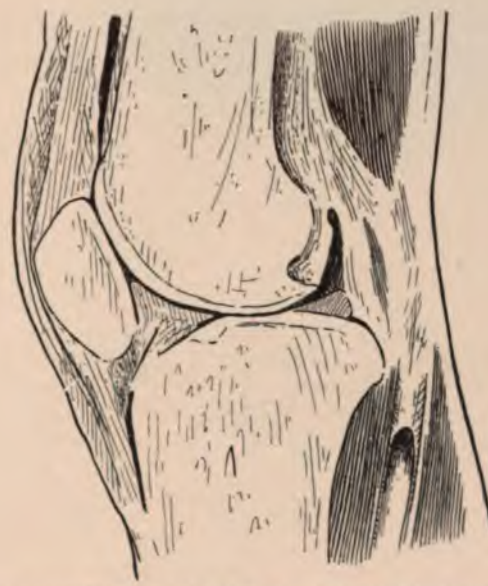

Fig. 458.—Anteroposterior frozen section of the knee-joint, showing extent of synovial membrane superiorly and inferiorly (Professor Dwight's specimen).

Fig. 459.—Ligamentous preparation of the knee, the patellar tendon cut just below the patella, dissected out, and reflected downward. Shows the lateral expansions of the quadriceps tendon extending to the tibia (from dissection by Professor Dwight).

from the head of the tibia by a bursa and a pad of fat tissue. The tendon of the quadriceps, the insertions of the vasti muscles

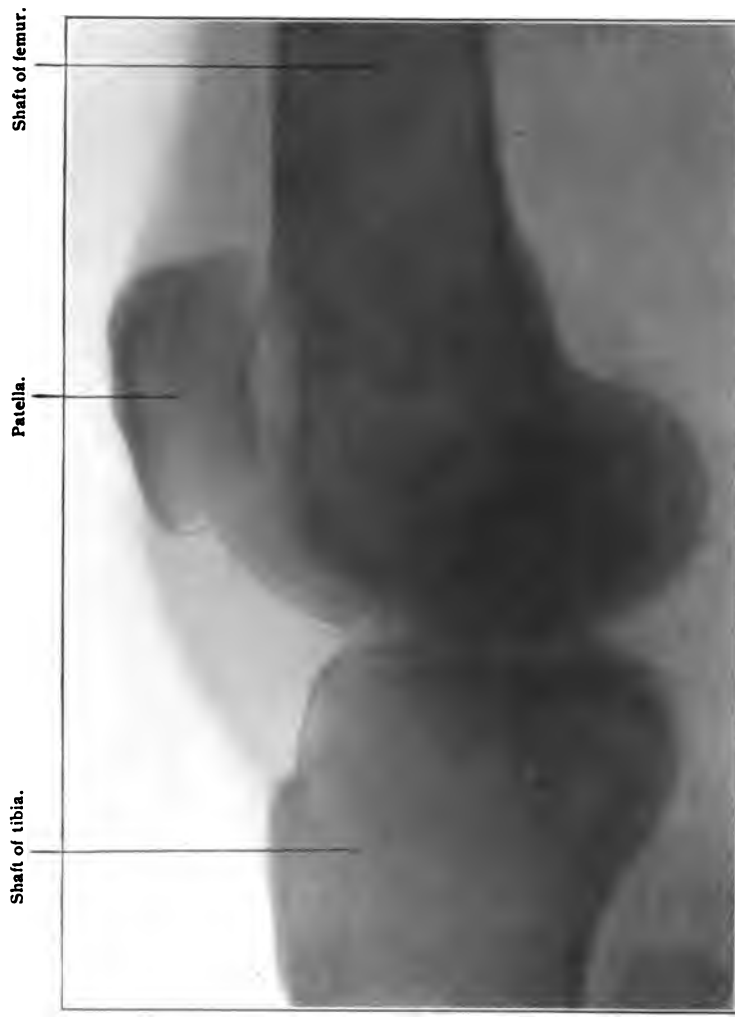

Fig. 460.—Skiagraph of normal right knee-joint in an adult.

the patellar tendon are all continuous with the strong fascia lata surrounding the thigh. The fascia lata is attached below to the condyles of the femur, the sides of the patella, the tuberosities of the tibia, the head of the fibula, and to the deep fascia of the leg in the popliteal space. The patella is seen, therefore, to lie in a strong fibrous sheath that encircles the knee and is attached to

Fig. 461.—*A*, Nearly median section of the knee-joint, the convex surfaces of the femur and of the patella in contact. *B*, Diagrammatic view, showing position in which the patella is subjected to a strain on contraction of the quadriceps, the probable mechanism of many patellar fractures.

various bony prominences (see Figs. 457, 458, 459). The synovial membrane of the knee-joint lies directly beneath and attached to the posterior surface of the patella. Laterally and posteriorly the synovial membrane lies next to the encircling fascia of the joint. The deep bursa of the femur lies in front of the lower end of the femur beneath the quadriceps muscles, and often communicates with the knee-joint. The tubercle of the tibia is on a level

the head of the fibula. The outline and anterior surface of the patella can be palpated throughout. When the leg is completely extended and is at rest, the patella can be removed from side to side. The numerous longitudinal striæ on the anterior surface of the patella can be detected. In these the tendinous bundles of insertion of the rectus are embedded. It is these fibers that fold in over the broken patella and prevent the approximation of the fragments. The ligament of the patella is parallel with the axis of the leg.

Fracture of the patella occurs through either muscular contraction (see Fig. 461) and strain or through direct violence. The form of the fracture is not altogether dependent upon the causative

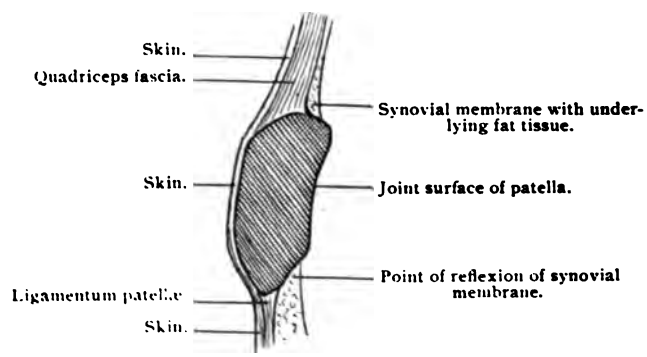

Fig. 462.—Diagram of anteroposterior section of patella and tendons, showing the small extrasynovial portion of posterior surface of the bone.

force. The fracture will be either transverse and clean cut or comminuted and irregular. The knee joint is generally opened: *i. e.*, the synovial membrane is generally torn. The synovial membrane is reflected from the posterior surface of the patella some distance from the most inferior tip of the bone. It is possible, therefore, for a fracture to occur at the lower portion of the bone for some considerable distance from the lower edge without opening the knee joint (see Fig. 462).

Symptoms. There are pain in the knee and immediate disability, varying from partial to complete loss of power in extension and in flexion. The patient may be unable to rise or, if he can stand, he can not move except backward, and then only by drag-

ging the foot of the injured limb upon the ground. The patient is often unable to raise the heel from the bed when lying upon the back. Swelling of the knee, which at first is slight, after three or four hours may become very great (see Fig. 463). The swelling is due to the accumulation of blood and synovial fluid in the knee-joint. A traumatic synovitis exists. The immediate swelling of the knee may become great enough to demand an incision to relieve the tension upon the skin, to prevent sloughing of the skin above the broken patella. Immediately after the accident crepitus may be elicited by pressing the two fragments together. When the knee-joint is distended by fluid, it is often impossible even to detect the fragments of the patella, but as the fluid subsides and

Fig. 463.—Case: Right knee normal; left knee, fracture of patella. Two days after accident. Observe swelling of whole knee. Joint filled with fluid.

the sulcus between the bones is felt, crepitus can again be detected. The degree of the separation of the fragments is dependent upon the amount of distention of the joint and upon the extent of the tearing of the lateral aponeurosis (fascia lata) of the knee, permitting muscular contraction and retraction. If the causative violence is associated with a wound of the soft parts, there will be evident a contusion or an abrasion of the skin or a lacerated wound opening the knee-joint, making the fracture an open one.

Treatment.—The indications to be met are the limitation and removal of the effusion, the reduction of the fragments, the maintenance of the reduction until union is satisfactory, and the restoration of the functions of the joint to its normal condition.

The Limitation and Removal of the Effusion.—If the fracture is

seen before there is great swelling, limitation of the swelling may be effected by immobilization of the knee and the accurate appli-

Fig. 464.—Fracture of patella; fibrous union. Broadening of lower fragment (Warren Museum, specimen 3652).

Fig. 465.—Fracture of patella. Fibrous union with moderate separation; marked tilting forward of fragments; no enlargement of fragments. View from side. *a*, Fibrous union; *b*, extent of articular surface which is now concave (Warren Museum, specimen 1129).

Fig. 466.—Fracture of patella; union with long fibrous band; separation of fragments 3¾ inches (Warren Museum, specimen 5253).

cation of an elastic rubber bandage. If the bandage is not at hand, sponge compresses may be used—viz., two slightly moist-

ened bath or carriage sponges are allowed to dry under pressure sufficient to flatten them. These are placed upon each side of the knee and over it, and are held by a few turns of a roller bandage. Cool water is the poured over the whole. As the sponges absorb the water they enlarge, causing equable and firm pressure on the knee, thus very materially hindering the accumulation of fluid

Fig. 467.—Fracture of patella; bony union; some elongation of bone as a whole. View from side (Warren Museum, specimen 6707).

Fig. 468.—Recent fracture of patella with comminution. Probably from direct violence (Warren Museum, specimen 1130).

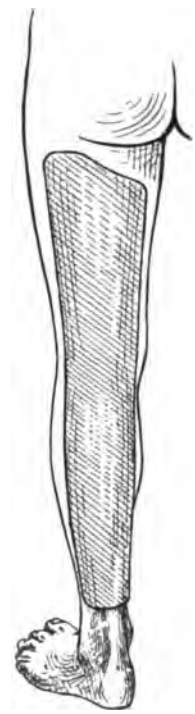

Fig. 469.—Ham-splint without strap, showing proper length and relation to thigh and leg posteriorly.

and favoring its absorption. These wet sponge compresses should be left in position for from twelve to twenty-four hours, and then a fresh set used.

Massage skilfully applied to the whole limb, irrespective of the method of treatment eventually instituted, will not only assist in the absorption of the fluid, but will preserve intact the muscles of the limb. Massage to be effective should be applied at least twice

daily, and from fifteen minutes to half an hour at a time. Slight pain will be felt, but after a time massage will be painless and give great comfort.

The Reduction of the Fragments.—No attempt should be made to reduce the fragments until nearly all the fluid is removed from the knee-joint. Reduction is accomplished by immobilization of the knee-joint, by fixation of the lower fragment, and by trac-

Fig. 470.—Improper method of applying a ham-splint. The knee-joint is not immobilized. Flexion is possible. Straps 1 and 2 are insufficient.

Fig. 471.—Proper method of applying a ham-splint. The third adhesive-plaster strap (3) prevents flexion of the knee.

tion upon and fixation of the upper fragment. The leg should be extended completely and the knee immobilized either upon ham-splint (see Figs. 469, 470, 471) or upon a Cabot posterior wire splint. The ham-splint is preferably made from a plaster-of-Paris bandage. The lower fragment is held fixed by a strap, preferably of adhesive plaster, placed obliquely about the leg and splint, and fastened to the splint above the fragment (see Figs. 472, 473, 474,

475). The upper fragment is drawn down first by elevation of the leg upon an inclined plane, which relaxes the quadriceps extensor muscle, then by traction obtained by a strap passed obliquely above the upper fragment and fastened to the splint below the

Fig. 472.—Expectant method of treating fracture of the patella. Leg extended on posterior wire splint. Fragments held by two straps. Fluid has left the joint. *A*, Side splints; *B*, coaptation splints reflected.



Fig. 473.—Expectant method of treating fracture of the patella. Same as figure 472, with the addition of coaptation splints to the thigh, padding, and straps.

fragment. The upper strap will need repeated adjustment as the plaster slips and as the fluid disappears from the joint. To facilitate traction by this upper strap, the quadriceps muscle should be held firmly by coaptation splints and straps encircling the poste-

rior splint. The quadriceps can not then actively pull upon the upper fragment. The tendency of these two straps thus applied will be to tilt the broken surfaces of the two fragments upward and apart, particularly if there is fluid in the joint. It is important, therefore, to place a third strap over the two broken edges of the fragments, in order to hold them down to their proper level and to assist in bringing them into apposition. The coaptation splints should be removed at every massage treatment, the upper fragment being steadied by an assistant. The straps about the patella need not be removed during the massage. They will be of no in-

Fig. 474.—Expectant method of treating fracture of the patella. Same as figure 473, with the addition of two lateral splints, padding, and straps. A posterior wooden splint, seen better in figure 473, and elevation of the limb.

convenience. As soon as the effusion has left the joint, all will have been gained in the reduction of the fracture that can be gained by this method.

Aspiration of the knee-joint by means of a narrow knife incision or by means of a large-sized trocar is, if done under strictly antiseptic precautions, and forty-eight hours after the fracture, often satisfactory in immediately removing the bulk of the effusion; if firm compression is then made, it effectually prevents the reaccumulation of fluid.

Maintenance of Reduction until Union is Satisfactory.—At the end of about four or six weeks from the injury union will be found.

All fluid will have left the joint. The retentive straps and coaptation splints may now be removed. The leg should be immobilized by means of a plaster-of-Paris splint extending from just below the swell of the calf to the groin. This splint is split on the side or

Fig. 475.—Expectant method of treating fracture of the patella. Anterior view of apparatus complete. The padding of the side splints is shown.

Fig. 476.—Extent of flannel bandage to knee, applied after all immobilizing apparatus is removed. The bandage is started at 1.

posteriorly and arranged as a removable dressing. Proper bathing is facilitated. This enables the masseur to work.

The removable splint is made thus: A light weight plaster-of-Paris roller bandage is applied to the properly protected leg from above the ankle to the groin. It is split in the median line its whole length before the plaster has quite hardened. It is sprung off the leg. After it is hard a narrow strip of leather, upon which

are fastened lacing hooks, is stitched to each cut edge. This splint may now be sprung on the limb and laced snugly in position. A leather splint may be similarly made from a plaster cast and mold of the limb. As soon as union is firm, the patient should be up and about with the light removable fixation splint applied, walking with the aid of crutches.

Fixation (prevention of flexion and extension) on walking is to be maintained for at least six months after the injury. Protecting the knee thus when walking for this period of six months does not preclude active movements of the knee when not bearing weight upon the limb. At the end of that time the patient may be al-

Fig. 477.—Old fracture of patella; great separation of fragments. Condyles of the femur are prominent in between fragments. Leg was useful, but weak. *A*, The lower fragment; *B*, the condyles of the femur; *C*, the upper fragment.

lowed to go about with a cane and a snugly fitting roller bandage (see Fig. 476). This bandage should be made of medium weight flannel, cut straight with the weave and not on the bias. The bandage should be applied from the middle of the calf of the leg to the middle of the thigh when the leg is completely extended. As the patient becomes confident of his strength, the cane need not be carried. Sudden movements are to be avoided. At the end of eight or ten months, varying with the individual case, all support may be omitted from the knee.

The Restoration of the Function of the Joint.—From the day of the injury daily massage to the whole limb is important. It maintains

the muscles in good tone. It prevents adhesion of the fragments to the tissues about the condyles of the femur, a not uncommon cause of ankylosis of the joint. It facilitates the absorption of the effusion of blood and synovial fluid. After the fourth week daily passive motion is to be instituted: at first very slight indeed, barely two or three degrees. If the relative position of the fragments is not altered perceptibly by this passive motion and lasting pain is absent, it may be persisted in with regularly increasing

Fig. 478.—Case: Fracture of the patellæ. Moderate separation of the fragments of each knee-joint. Useful legs.

amounts. At the expiration of eight or ten weeks active motion at the knee-joint may cautiously be allowed. The appearance of persistent and increasing tenderness, sensitiveness, or pain, and increasing separation of the fragments are the indications to diminish or cease passive and active motions.

Summary of the Treatment of Fracture of the Patella by the Expectant or Nonoperative Method.—During four weeks fixation of the knee, elastic compression, douching, massage, the thigh

flexed slightly on pelvis, the leg extended, retentive straps, coaptation splints, are the measures employed. At the fourth or sixth week, remove all apparatus, apply removable splint, allow walking with crutches, and use daily passive motion. At the eighth week, discard crutches, use cane, and permit limited daily active motion. At the sixth month, discard splint, apply flannel bandages, and discard cane. At the eighth to the tenth month, remove all support.

Open Fracture of the Patella.—This is a very serious injury, because one of the largest synovial cavities of the body is exposed

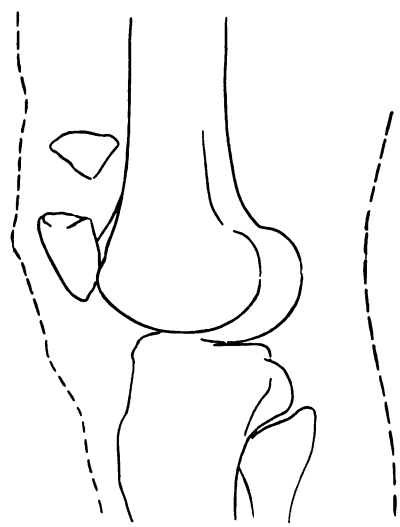

Fig. 479.—Fracture of upper third of patella, showing separation of fragments. Tilting of the upper fragment through rotation upon its transverse axis (X-ray tracing).

to infection. It is safest and wisest to lay open the knee-joint, to thoroughly irrigate it with a solution of corrosive sublimate (1 : 10,000), and then with a sterilized normal salt solution. All blood-clots should be carefully wiped away. All loosely attached fragments of bone should be removed. Particular attention should be paid to the posterior parts of the joint, behind the condyles of the femur. It will be found convenient in cleaning these parts first to flush the joint with sterile salt solution and to flex and to extend the knee. All parts of the joint posteriorly are thus likely to be thoroughly flushed. The fragments should be approxi-

mated and sutured by some absorbable suture. The skin-wound should be closed. The knee-joint should be immobilized in a posterior wire splint and side splints or in a plaster-of-Paris splint.

Prognosis.—Ordinarily, an individual should not follow his occupation for about six weeks to two months after a fracture of the patella—*i. e.*, unless the occupation can be conducted with a leg held stiffly at the knee. The functional usefulness of the limb and not anatomical considerations should be the chief crite-

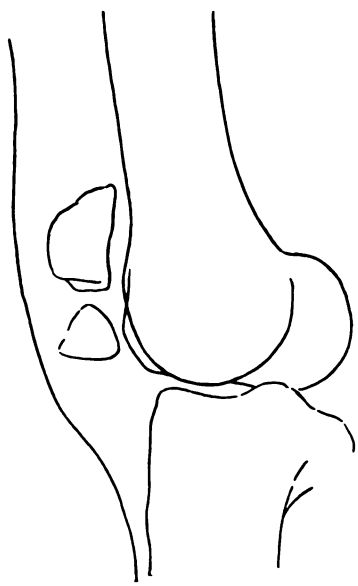

Fig. 480.—Fracture of the patella in the lower third, showing tilting of lower fragment through rotation on its transverse axis (X-ray tracing).

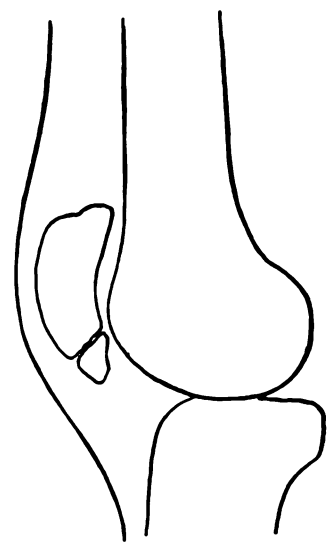

Fig. 481.—Fracture of lower edge of patella. Little separation of fragments. Indirect violence (X-ray tracing).

rion in determining the result following fracture of the patella. If a man can earn his living as before the accident without local discomfort or hindrance, he possesses a useful limb. It makes little difference if there is a slight separation of the fragments or a suggestion of a limp or slight atrophy of the thigh and calf muscles; these conditions are all to be accepted as part of the irreparable damage, and are trivial. In nonoperative cases the union is usually fibrous, although it may be bony. The interval between the fragments may amount to five or six inches. The appro-

mation of the fragments of the patella is not evidence of strength, for the fibrous bond of union may be much narrower than the fractured surface and very thin, and thus easily ruptured. The usefulness of the limb after fracture of the patella is not dependent upon any one factor, either the kind of union or the extent of the separation of the fragments of bone. There are usually no adhesions of the upper fragment to the femur; but injury to the bursa under the quadriceps may cause troublesome adhesions upon the

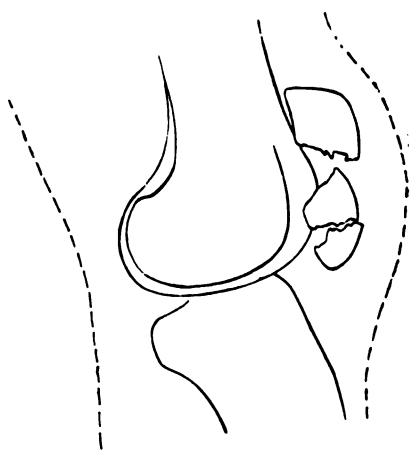

Fig. 482.—Double fracture of patella without great separation of fragments (X-ray tracing).

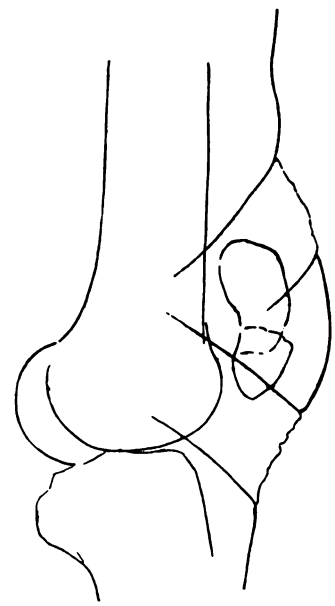

Fig. 483.—Transverse fracture of patella, showing straps in position to hold fragments (X-ray tracing).

anterior surface of the thigh. Full flexion is a common result, but there is often limitation of active extension. There almost always remains a little joint stiffness, despite both massage and active and passive motion; this, unless due to fibrous adhesions, disappears gradually. The majority of cases of fracture of the patella under careful nonoperative treatment will secure a useful limb. A patella once fractured and having united by fibrous or bony union may be broken through the callus of the healed fracture or in an entirely different fracture from the first break.

Results after Fracture of the Patella.—In a series of forty-seven cases of fracture of the patella treated at the Massachusetts General Hospital, occurring between the ages of eleven and sixty-five years, four were over fifty years, thirteen were under twenty-five years, twenty-nine were between twenty-five and forty-five years, one was forty-seven years old; practically, a young adult series. Of this series of forty-seven cases ten were treated by operation and the remainder by the expectant method. These cases are not mentioned in this connection to compare methods of treatment, but to determine the condition of the knee a long time after the

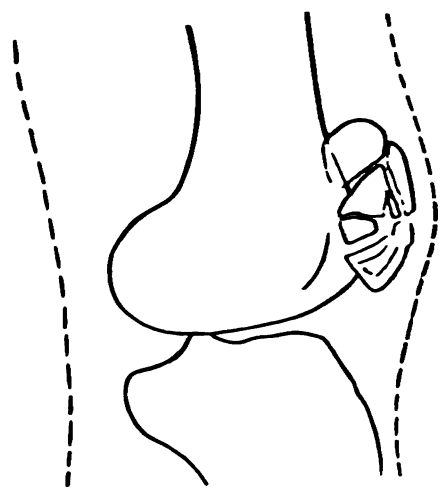

Fig. 484.—Comminuted stellate fracture of patella through direct violence (X-ray tracing).

injury. As a matter of fact, there appeared no greater freedom from the symptoms complained of among the cases operated on than among those unoperated. The results, as carefully recorded in these forty-seven cases, suggest some of the difficulties that patients experience after fracture of the patella. The detailed reports of these cases, from one and one-half to ten and one-half years after treatment ceased, show that about twenty have as good a leg as before the accident. The remaining twenty-seven cases complain of limitation of motion at the knee-joint, that the knee creaks in walking, that it feels stiff, aches, and burns at times. The leg is said to be weak, and is troublesome in going up and

down stairs—stepping up is especially difficult; kneeling is painful; stepping upon irregular surfaces is painful; running with the same freedom as before the accident is impossible; the knee often gives way in walking and causes a fall; the patient can not jump as before the accident, and walks with a slight limp. Pain is present in or about the knee in damp weather and after unusual exertion.

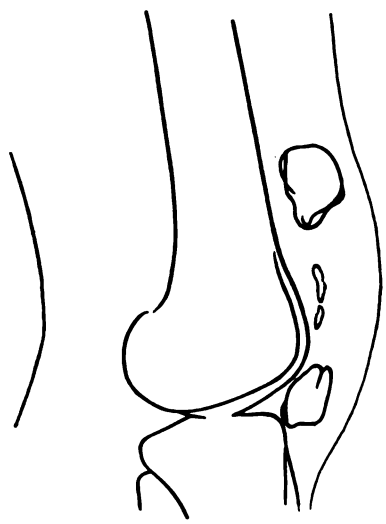

Fig. 485.—Old fracture of patella. Much separation of fragments. Small nodules of bone seen in the band of union (X-ray tracing).

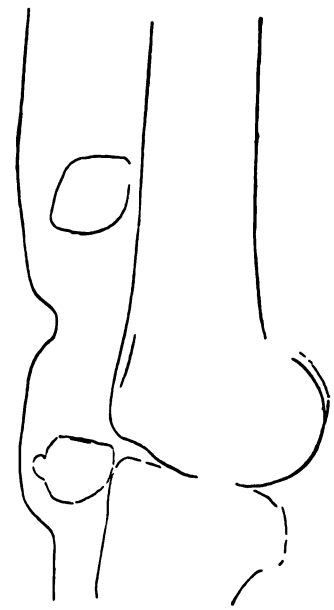

Fig. 486.—Old fracture of patella. Wide separation of fragments. Dimpling of skin. A useful but not a strong leg (Massachusetts General Hospital, 847. X-ray tracing).

Operative Interference in Recent Closed Fractures of the Patella.—In deciding whether a given case should be treated by operation or not the following considerations should be carefully weighed: A closed fracture of the patella does not in itself endanger life. It may be treated by the conservative method without added risk. If properly treated, the result will ordinarily be satisfactory as far as the functional usefulness of the knee is concerned. The operative method consumes less time in convalescence and an

excellent result is achieved, but operation exposes to the danger of sepsis: If sepsis results, the following conditions are imminent: A stiff knee, amputation of the thigh, and possibly death from

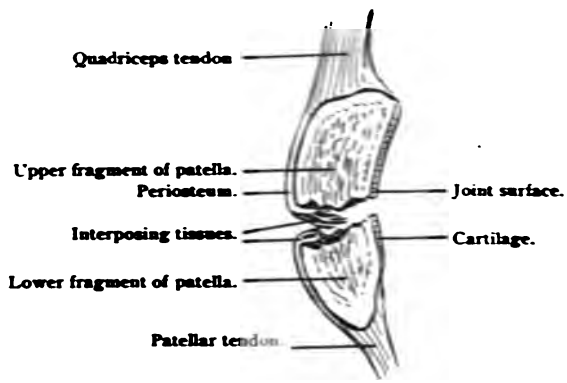

Fig. 487.—Median section of patella and tendons (diagrammatic), showing interposition of fascia and periosteal shreds between the fragments.

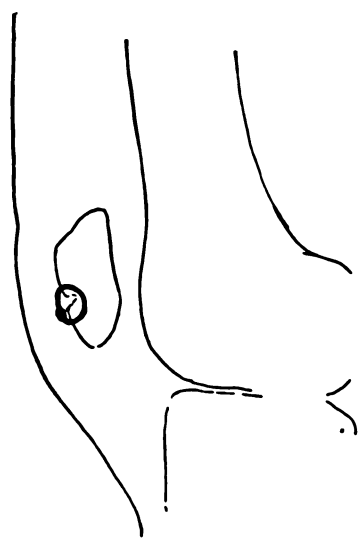

Fig. 488.—Fracture of patella; fragment approximated and sutured with silver wire. Wire seen *in situ* (X-ray tracing. C. B. Porter).

septic infection. Whether operation shall be done or not, therefore, depends upon the degree of safety with which it can be performed. It is the surest method of securing perfect apposition

and bony union. It should be undertaken only by surgeons of exceptional judgment and great skill, who have at command skilled assistants, and who can work under the most rigid aseptic conditions. The acute symptoms should be allowed to subside before operation. The tissues require time to recover themselves from the acute trauma. The operative treatment should be confined to healthy individuals under sixty years of age; to fractures with a separation of an inch or more of the bony fragments and extensive lateral fascial tears (the fascial tears may be recognized

Fig. 489.—Case: Freshly fractured right patella sutured with chromicized catgut. Result after eight weeks. Note flexion of leg to a right angle; line of incision (Warren).

by joint distention and localized bulging); to cases presenting great joint distention that does not disappear quickly. It should be seriously considered if the individual's occupation is arduous and necessitates much standing or walking. The patient should be informed as to the probable outcome by the two methods of treatment. The danger to life and limb should be fairly stated. It should be remembered that the power of extension of the leg is not materially limited by a transverse fracture of the patella in which the tearing of the lateral fascia is absent. Only in direct

proportion to the extent of the lateral fascial tear is there limitation of the power of extending the leg upon the thigh. In open fractures, in refracture, and in cases of impaired function from long fibrous union or from adhesions of the patella or from badly united patellæ mechanically impeding the movements of the joint, operation is always indicated. The working-man who wants to get to work should, under the conditions previously stated, have his patella sutured, for he will go to work quicker and have a better knee-joint than by any method of treatment.

Method of Operation.—The joint and the fractured bones are to be thoroughly exposed by a transverse or longitudinal incision. All clots should be thoroughly washed or sponged out. Any loose small fragments of bone should be removed. In almost all cases a rather dense fascia will be found overlapping the broken surfaces of the two fragments (especially is this seen in a transverse fracture). These bits of overlapping tissue or curtains of tissue should be retracted and removed or utilized in suturing the fragments (see Fig. 487). Whether silver wire is employed to suture the bone directly or whether an absorbable material is used to suture the soft parts seems of little consequence as long as all fascial tears are sutured and the bony fragments are approximated (see Fig. 488). The weight of opinion to-day is in favor of absorbable sutures. Closure of the joint without drainage and immobilization in the extended position followed by the treatment already mentioned are indicated (see Fig. 489).

The Restoration of the Function of the Joint Following the Operative Treatment.—After suture of the patella, massage and gentle passive motion should be begun at the end of two weeks. At the end of three weeks the patient may go about with the knee protected by a light stiff dressing. After about six weeks to two months a flannel bandage and a cane will be all the protection needed to the knee. At the end of three months the knee should be functionally perfect.

CHAPTER XIV

FRACTURES OF THE LEG

Anatomy.—The following structures may be palpated: The internal and external tuberosities of the tibia, the whole of the external tuberosity being subcutaneous; the broad anterior and

Fig. 490.—Middle of the patella, tubercle of the tibia, and midpoint between the malleoli all lie in the same straight line as the leg rests naturally.

inner surface of the tibia, which forms the shin, downward to the internal malleolus; the sharp crest of the tibia throughout its whole length; the head of the fibula, an inch below the top of the

tibia; a little of the shaft of the fibula below the head and the attachment of the biceps tendon; the lower third of the fibula which is subcutaneous. The tubercle of the tibia is distinctly felt on the anterior surface of the upper end of the tibia. It is one inch from

Fig. 491.—Fracture of the tibia; union with displacement forward and outward (Warren Museum, specimen 1140).

Fig. 492.—Fracture of the tibia low down; marked outward bowing; union (Warren Museum, specimen 1146).

the articular surface, and marks the lowest limit of the upper epiphysis of the tibia. Into it is inserted the patellar tendon. The shaft of the tibia arches slightly forward. The shaft of the fibula arches slightly backward. The broad inner malleolus is higher than the outer malleolus, and more to the front of the leg. The

outer malleolus is narrow. The posterior edges of the two malleoli are in about the same plane. The anterior edge of the external malleolus is about an inch behind the anterior edge of the internal

Fig. 493.—Fracture of the left fibula near the lower end; united. View from outer side (Warren Museum, specimen 1150).

Fig. 494.—Fracture of the tip of the lower end of the left fibula; united. View from inner side (Warren Museum, specimen 1151).

Fig. 495.—Fracture of the tibia low down; displacement of the upper fragment backward; union (Warren Museum, specimen 7723).

malleolus. The narrowest part and the weakest place in the tibia is at the junction of the lower and middle thirds of the bone. In the normal leg the middle of the patella, the tendon of the patella,

Fig. 496.—Case: Injury to knee. Note starting of upper epiphysis of the tibia.

and the midpoint of the ankle are in the same straight line (see Fig. 490).

General Observations.—Fractures of the tibia and fibula may occur at any point, depending upon the seat and direction of the fracturing force. If the force is indirect, the fracture of the two bones will be at different levels. If the fracture is high up, the

Fig. 497.—Fracture of both bones of the leg; union with considerable displacement; cross union of the two bones (Warren Museum, specimen 5265).

Fig. 498.—Fracture of both bones of the leg; displacement of upper fragments downward and inward; union (Warren Museum, specimen 8303).

knee-joint may be involved or the popliteal vessels and peroneal nerve may be implicated. If the fracture is low down, the ankle-joint may be involved. The high fracture of the tibia is usually transverse. The low fracture of the tibia is usually oblique. The common seat of fracture is at about the junction of the middle and lower thirds of the leg. The line of the fracture is an oblique

one, extending from above and behind downward and forward through the tibia. The fibula is fractured a little higher than the tibia. If the force is considerable and the sharpness of the fragments great, the overlying skin may be lacerated, an open or infected fracture resulting. The upper and lower epiphyses of the tibia may be separated; these are, however, rare injuries. The tibia and fibula may be fractured separately. In such cases the unbroken bone serves as a splint for the fractured one. The displacement in these latter fractures is slight.

It is not very unusual to find a starting of the upper epiphysis of

Fig. 499.—Method of measuring the length of the tibia rom the internal tuberosity to the internal malleolus.

the tibia as illustrated in figure 496. Dr. Robert Osgood has demonstrated recently that many apparently trivial injuries to the region of the tubercle of the tibia are in reality partial separations, with or without some displacement of the tongue-shaped portion of the upper epiphysis of the tibia, or actual separation of an independent bony center for the tubercle of the tibia. Clinically slight swelling and tenderness in the region of the tibial tubercle and pain upon extension are the chief signs.

Examination of a Fractured Leg.—It is sometimes extremely difficult to detect a fracture of the leg. It is, therefore, important that a systematic examination should be made immediately after

the injury. Deformity will ordinarily be apparent upon inspection (see Fig. 501). Gentle manipulation will suffice to satisfy one of the existence of a fracture, particularly if both bones are broken. An open fracture will be evident if a wound exists in the skin near the seat of fracture. In taking hold of the leg for examination or for moving the leg it should not be grasped lightly by a few fingers but by the whole hand firmly, as one grasps an ax handle in chop-

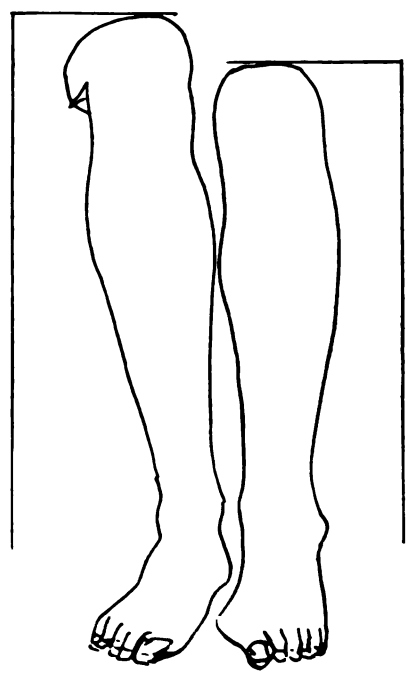

Fig. 500.—Fracture of both bones of the left leg. Comparative height of knees to show shortening of leg. The patient is sitting with knees flexed to a right angle (after Van Lennep).

ping wood: not as one lifts a lead pencil from the table. The leg should be so raised in making the examination that there is absolutely no risk of converting the closed fracture into an open one. In order to guard against this the assistant should grasp the foot at the ankle and make gentle but strong traction in the long axis of the leg as the whole leg is raised. This care in examination will cause the patient a minimum amount of pain. Crepitus is not the only thing that is to be sought at the examination. The freedom

of any abnormal mobility should be noticed, as well as the direction of the motion, the ease with which reduction is possible, and the liability to recurrence of the deformity. If there is any doubt as to the seat or extent of the fracture, the examination should be made with the assistance of an anesthetic. The temporary dressing may be applied at this time. The bones should be palpated. While an assistant steadies the knee-joint the surgeon, grasping the lower part of the leg, attempts motion in each direction. Simply raising the leg and attempting motion in an anteroposterior direction is not sufficient; a fracture of the tibia, if transverse, might remain completely locked except upon lateral movement. The tibia should be measured (see Fig. 499) from the knee-joint line, at the upper border of the internal tuberosity, to the lower

Fig. 501.—Case: Fresh fracture of the leg (both bones). Characteristic deformity. Note normal position of patella, with the foot lying on its outer side. Prominence of upper fragment. Compare this with figure 391 of a fracture of the thigh in which the patella does not look upward.

edge of the internal malleolus to determine shortening. Shortening of the leg may be roughly estimated after union of the bones by comparing the height of the two knees while the soles of the feet rest upon the floor (see Fig. 500). The measurement should be compared with that of the uninjured tibia. It is often difficult in fractures near the ankle to palpate the internal malleolus, on account of swelling. Deep pressure with the thumb will detect it. Inquiry should be made as to whether either tibia has ever been fractured previously. The pulse should be felt for in the posterior tibial and dorsalis pedis arteries to be sure that the large vessels of the leg are intact.

Symptoms.—Ordinarily, the presence of pain, deformity, abnormal mobility, crepitus, and loss of use of the leg will be the evi-

dences of fracture. If the fracture is of the tibia or fibula alone and transverse without much displacement, localized tenderness upon pressure and swelling will be the only signs. It is important



Fig. 502.—Fracture of the tibia, oblique and high up. Almost no displacement (Massachusetts General Hospital, 1235. X-ray tracing).

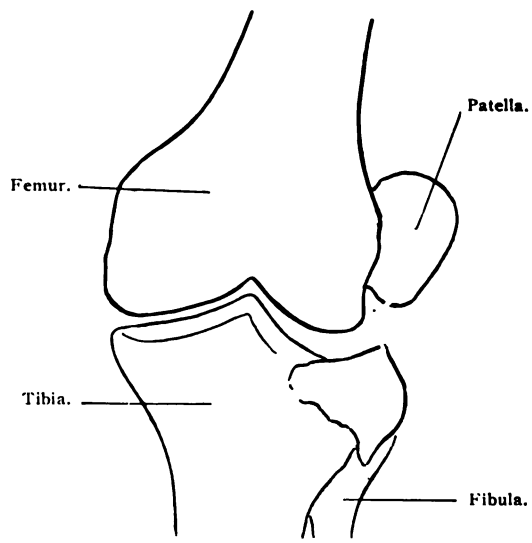

Fig. 503.—Fracture of the external tuberosity of the tibia (Massachusetts General Hospital, 1242. X-ray tracing).

to remember the backward bowing of the fibula in attempting to localize by palpation the tender point of the fracture of that bone.

The deformity is due to the displacement of the upper fragment

forward and of the lower fragment upward and backward. If the fracture is oblique, this displacement will be considerable. The lower fragment is often rotated upon its longitudinal axis, so that the foot rests upon its side, while the upper fragment remains undisturbed by rotation, the patella looking directly upward (see Fig. 501).

The swelling will vary. It may be extremely slight and limited to the seat of the fracture or it may extend over the entire leg. The maximum swelling of the leg is usually reached three or four days

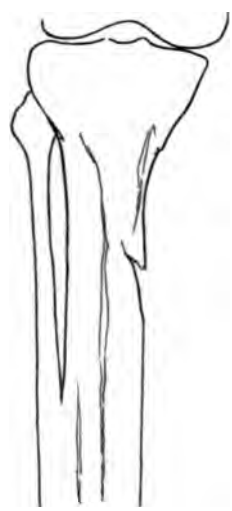

Fig. 504.—Longitudinal fissuring of tibia from blasting accident. Front view (X-ray tracing).

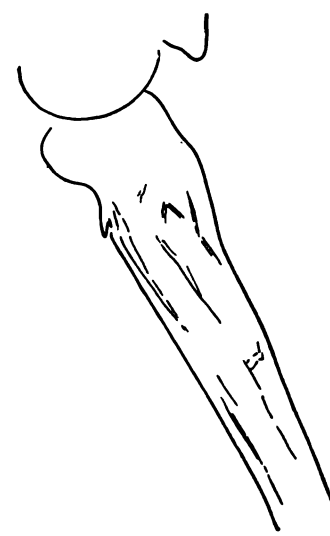

Fig. 505.—Longitudinal fissuring of tibia from blasting accident. Lateral view. Same as figure 504 (X-ray tracing).

after the accident. If the fracture was caused by direct violence and the fragments of bone are sharp, the soft parts will be damaged and the resulting hemorrhage and swelling will be very considerable.

Ecchymosis of the skin appears in from twenty-four to forty-eight hours after the accident; it may extend over the whole leg. Ecchymosis from a sprain is localized more or less about the seat of the sprain; that from a fracture is often extensive. Blebs or vesicles may appear near the fracture during the first week if the

swelling is great. It is necessary to exercise great caution in the care of these blebs, that they do not become infected.

Fracture of the shaft of the fibula may be very obscure, but pressure upon the fibula toward the tibia will elicit pain and crepitus. In separation of the lower epiphysis of the tibia the preservation of the normal relations between the malleoli is of considerable diagnostic importance.



Fig. 506.—Oblique fracture of the tibia low down, and oblique fracture of the fibula at its middle (X-ray tracing).

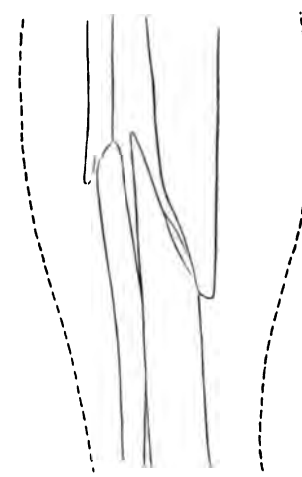

Fig. 507.—Fracture of both bones of the leg at the middle; slightly spiral of tibia (Massachusetts General Hospital, 1134. X-ray tracing).

Treatment.—For purposes of treatment fractures of the leg are arranged into several distinct groups—viz.:

1. Fractures with little or no swelling or displacement.
2. Fractures with considerable swelling.
3. Fractures with a displacement of fragments difficult to hold corrected.
4. Open fractures.

The indications to be met by treatment in each of these groups

are correction of deformity, immobilization of fragments, and restoration of the limb to its normal condition.

Fractures with Little or No Displacement or Swelling.—Fractures of the tibia alone or the fibula alone are properly placed in this group. Fractures of both bones occasionally occur with little or no displacement and with but a trifling amount of swelling. In

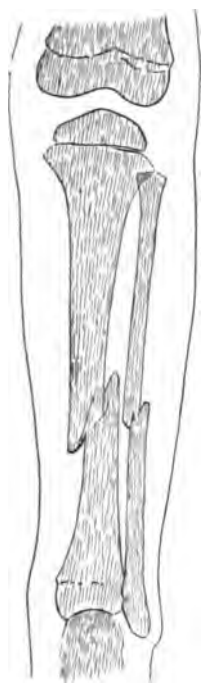

Fig. 508.—Oblique fracture of both bones of the leg. Displacement of the upper fragments in the same inward direction (Massachusetts General Hospital, 749. X-ray tracing).

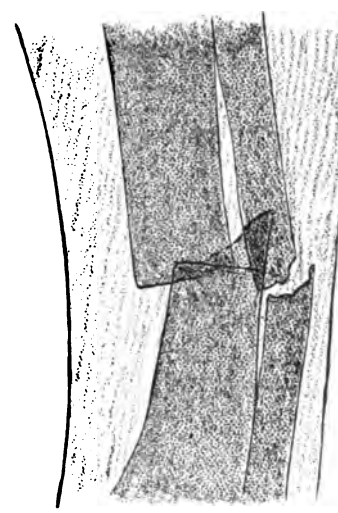

Fig. 509.—Transverse fracture of both bones of the leg at the middle; slight displacement and considerable bowing (Massachusetts General Hospital, 1215. X-ray tracing).

these cases the leg should be elevated for ten minutes in order to lessen the swelling. The foot, leg, and lower thigh are then bathed with soap and water, and thoroughly dried and powdered. The leg being properly protected, a light plaster-of-Paris roller bandage is applied from the toes to the middle of the thigh. (See Details of Plaster Work.) The leg is to be kept elevated for the first week by at least two or three pillows. If good judgment is

exercised in the subsequent care of the case, the placing of such a fracture, as previously indicated, immediately in a plaster-of-Paris splint is attended by no risk. The danger lies in too great pressure upon the circulation, caused by the increasing swelling of the leg within the unyielding plaster splint. Pressure sores and gangrene are liable to result. In applying the splint a liberal amount of sheet wadding should be used. The condition of the circulation should be noted immediately after the application of the splint and at regular intervals thereafter until all danger from undue pressure has ceased. Evidences of too great pressure are persistent or

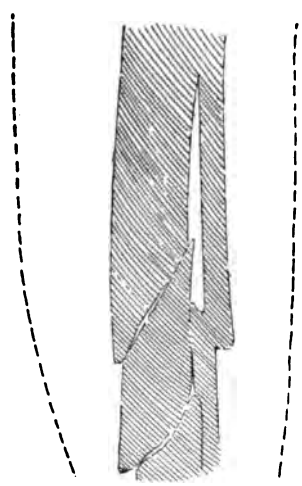

Fig. 510.—Double fracture of the tibia. Single fracture of the fibula (Massachusetts General Hospital, 1055. X-ray tracing).

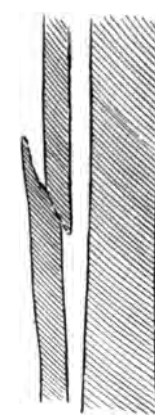

Fig. 511.—Fracture of the fibula without injury to the tibia (Massachusetts General Hospital, 1230. X-ray tracing).

increasing swelling of the toes, blueness of the toes, and pain. It is well, in order to avoid undue pressure upon the leg, to split the plaster the entire length of the splint before it has quite hardened. The splint loses by this procedure none of its immobilizing qualities, for it can be bandaged or strapped tightly together again. Too great pressure upon the circulation can then be immediately relieved by loosening the retaining straps or bandage and thus opening the splint. After the splint has been on the leg for about a week and a half or two weeks, the swelling having begun to subside, the plaster splint will become loose and will cease to hold the

fragments firmly. Unless a new and snug splint is now applied, it will be necessary to cut out a strip of plaster an inch or more wide from the old splint to admit of tightening. During the changing of the plaster splint the leg should be steadied by an assistant while it is thoroughly washed with soap and water and bathed with alcohol.

Fractures with Considerable Immediate Swelling.—Many fractures are not seen by the surgeon until two or three hours after they have occurred, when considerable swelling is present. Associated

Fig. 512.—Fracture of the fibula low down without fracture of the tibia (X-ray tracing).

Fig. 513.—Oblique fracture of both bones of the leg low down. Fracture difficult to hold in good position (Massachusetts General Hospital, 1024. X-ray tracing).

with such primary swelling there will be laceration of the soft parts and possible extensive injury to the bone. Blebs filled with clear or bloody serum may be present about the seat of fracture. These should be evacuated after the part has been rendered surgically clean by washing with soap and water and corrosive sublimate solution, and then dressed with a dry antiseptic powder, powdered dermatol, or aristol. Infection may take place through blebs. Very great care should be exercised in their treatment. Obviously, it is unwise immediately to apply a plaster-of-Paris splint to cases in which there are many blebs and much swelling. The

swelling of the leg may become so great that the life of the limb may be at stake, the danger from impending gangrene becoming imminent. In such cases the skin of the leg becomes tense and shiny, the leg feels hard and board-like, pain may be extreme, and the toes and foot become slightly blue. The hemorrhage, being confined beneath the fascia and skin, causes pressure upon the

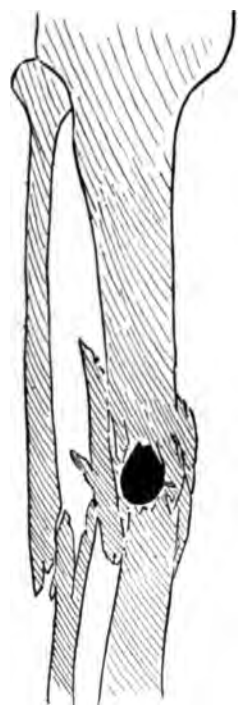

Fig. 514.—Fracture of both bones of the leg from bullet-wound. Characteristic comminution of the bones. Bullet not removed. Recovery with a useful leg (X-ray tracing) (Warren).

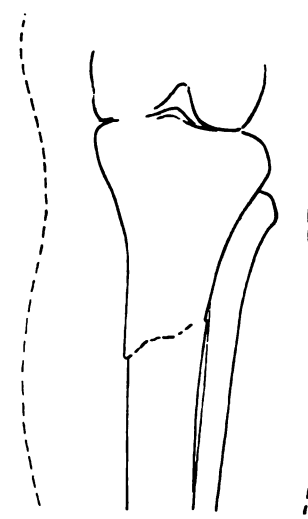

Fig. 515.—Transverse fracture of the tibia, high. Direct violence. Great swelling of leg. Threatening gangrene. Free incisions. Leg saved. Result good. Same case as figure 516 (Massachusetts General Hospital, 1064. X-ray tracing) (Scudder).

circulation. The circulation in the leg is thus impeded. Under such circumstances operation is necessary in order to relieve tension and to check hemorrhage. Incisions in the long axis of the limb through skin and fascia will be followed by a rapid decrease in the swelling of the leg and a cessation of the pain. After incision, the bleeding vessels found should be ligated. The bones may

be sutured at this time if it is thought wise. If these wounds remain aseptic, they may be closed after a few days by suture or may be allowed to heal openly. This method of treatment will usually result in saving the leg (see Figs. 515, 516). If the circulation does not return and gangrene is imminent, immediate am-

Fig. 516.—Case: Closed fracture of the left tibia. Hematoma. Impairment of the circulation. Free incisions. Evacuation of blood. Relief of pressure. Leg saved. Recovery (Scudder).

Fig. 517.—Fracture of the leg. Temporary or emergency dressing. Application of the pillow with straps. Open end of the pillow-case at the foot.

putation of the limb well above the fracture at the lower or middle third of the thigh is the only procedure. Traumatic gangrene is often rapidly followed by general septic infection. It is best to use a temporary dressing in cases in which there is great initial swelling of the leg.

The Temporary Dressing.—The Pillow and Side Splints.—The leg is placed on a pillow covered with a pillow-case; straps are placed under the pillow and drawn snugly up about the leg (see Fig. 517). The edges of the pillow are rolled in against the leg for firmness. Narrowly folded towels are placed between the leg and the straps. The straps are then drawn tighter. The open end of the pillow-case is folded and pinned under the sole of the foot.

Fig. 518.—Fracture of the leg. Pillow and side splints with straps and towels. Compare figure 519.

Fig. 519.—Fracture of the leg. Temporary or emergency dressing. Pillow, side splints, and straps. Pillow held by shield-pins.

Three pieces of splint wood are introduced between the pillow and straps—one is slipped underneath and one upon each side of the pillow. The pillow thus serves as a padding for the box formed by the splint wood (see Fig. 518). Ice-bags may be conveniently placed along the anterior surface of the leg between the edges of the pillow. They relieve pain and are said to check hemorrhage immediately after the fracture. If greater security is thought necessary, the pillow-case, instead of having its sides rolled in,

may be pinned with shield-pins up over the anterior surface of the leg (see Fig. 519).

This temporary dressing is left in place for a week or a week and a

Fig. 520.—Diagram of oblique fracture of the leg. Displacement upward and forward of the lower fragment.

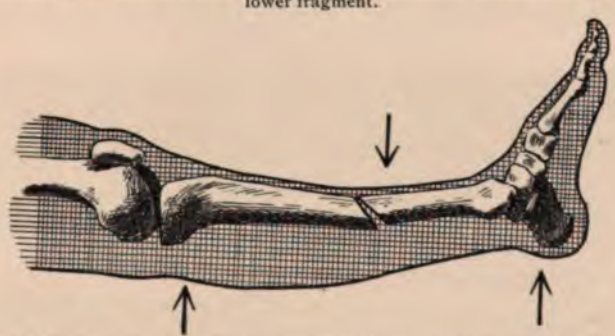

Fig. 521.—Diagram illustrating a frequent method of apparently correcting the displacement, which results in producing a backward bowing.

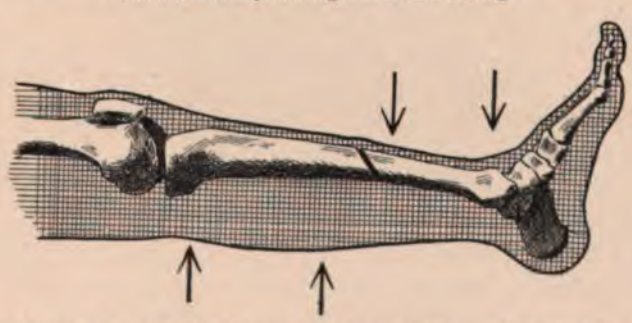

Fig. 522.—Diagram illustrating the proper direction in which, combined with traction, force should be exerted in order to correct the displacement.

half. The swelling will then have partly subsided. If at this time there is little or no swelling and the displacement is slight, a plaster-of-Paris splint may be applied as a permanent dressing; it is split

or not as circumstances indicate. If, on the other hand, at the end of a week or a week and a half it is desired to have the fracture open to inspection and more directly accessible and under the eye of the surgeon, then the posterior wire and side splints should be applied.

The Permanent Dressing for Fracture of the Leg.—Several important things are to be kept constantly in mind in placing a fractured leg in a permanent splint. They are as follows: The alinement of the bones of the leg is to be maintained; rotation of either fragment upon its long axis is to be avoided; the foot is to be kept extended to a right angle with the leg; lateral deviation is to be avoided; the inner side of the great toe, the middle of the patella, and the anterior superior spine of the ilium should be in one straight line; anteroposterior deformity is to be avoided (the con-

Fig. 523.—Padding the Cabot posterior wire splint. Applying sheet wadding. The shape and proportions of the Cabot splint are apparent.

vexity of this curve of deformity is usually backward; it is a hyperextension of the leg at the seat of fracture) (see Figs. 520–522); frequent measurements and inspection of the leg should be made; inspection should be made not only from the front, but laterally as well; readjustment of apparatus is necessitated by changes in the position of the bones.

The Posterior Wire and Side Splints.—The posterior wire or Cabot splint is made of iron wire the size round of an ordinary lead-pencil (see Fig. 523). It is applied to the back of the foot, leg, and thigh, extending from just beyond the tips of the toes to above the middle of the thigh. It is narrow at the heel and broad enough above to permit the thigh to rest comfortably upon it. The foot-piece is at right angles to the leg.

Having at hand the iron wire the size of an ordinary lead-pencil, this splint can be quickly and easily made by means of a vise for holding the wire, and a wrench for grasping the wire while bending it. The two free ends of the wire of the splint may be held firmly together by having them overlap and binding them together with

Fig. 524.—Padding the Cabot posterior wire splint: (1) With sheet-wadding (see Fig. 523; (2) with a cotton roller around the wire, and (3) around both wires, to form a back to the splint.

small-sized copper-wire. These free ends may, of course, be held by solder.

The Covering of the Posterior Wire Splint.—The wire is wound first with a roller of sheet wadding, then with a cotton roller, and finally a cotton roller bandage is wound about both sides of the splint so as to make a posterior surface upon which the leg may rest (see Figs. 523, 524, 525).

The side splints of wood (see Fig. 526) should be about four inches wide, and long enough to extend from the foot-piece to the top of the splint. The side splints may be covered with sheet wadding and cotton cloth, as seen in the figure.

Care of the Heel.—If but slight pressure is maintained upon the heel even for a few days, a pressure sore will develop. This is liable to increase to a considerable size. It is very slow in healing. Many weeks after the fracture of the leg has united the pressure sore may be open. It is, therefore, of very great importance to prevent pressure upon the heel during the treatment of fractures of the lower extremity associated with dorsal decubitus. There are four methods of avoiding pressure on the heel. Position will assist materially. The position of the foot largely determines the

Fig. 525.—The Cabot posterior wire splint padded completely. Note the foot-pad of pasteboard covered by cotton-cloth pinned to the foot-piece of the splint for greater security.

amount of pressure falling on the heel. When the foot rests naturally, it is in the position of slight plantar flexion. The heel presses firmly upon the splint (see Fig. 527). A large part of the weight of the leg thus falls upon the heel. When the foot is extended to a right angle with the leg, the pressure upon the heel is, in a large measure, removed (see Fig. 528). Therefore, in putting up fractures of the leg the right-angle position is the desirable one. Padding above the heel is of service. The ring or doughnut pad around the heel is sometimes efficient. Slinging the foot by adhesive straps applied to the sides of the heel and foot and fastened to the foot-piece of the splint is a very satisfactory method of removing pressure from the point of the heel (see Fig. 529).

The Padding of the Posterior Wire Splint for the Reception of

the Lower Extremity.—Regard should be had for the natural curves of the leg and thigh posteriorly (see Fig. 528). Above the heel, behind the knee, and below the buttock are distinct hollows, at which places the padding, as indicated in the illustration, should be thicker than at other points. Regard should likewise be had for the natural lateral curves of both thigh and leg. Just below the

Fig. 526.—Side splint of splint wood (3). Method of padding: (1) With sheet-wadding; (2) with cotton cloth; (4) pinned in place, and then (5) stitched.

malleoli, above the ankle, below the knee, and above the knee are distinct hollows that will require more padding than elsewhere on the sides of the limb (see Fig. 530). The more carefully the splint is padded, the more nearly perfect will be the result of treatment and the greater will be the comfort of the patient.

The leg is to be placed upon the posterior wire splint, so padded

posteriorly that it rests naturally and comfortably. The foot should be placed at a right angle, drawn down snugly to the foot-piece, and steadied by adhesive-plaster straps carried around the foot and splint in a figure-of-eight bandage (see Figs. 532, 533). The side splints, so padded with pillow-cases or towels as to bring suitable pressure upon the leg and thigh, are applied and held in position by straps and buckles (see Fig. 533). This splint immobilizes the knee- and ankle-joints and the fractured bones. The

Fig. 527.—Normal leg with foot flexed, showing that the heel rests heavily on the table (see Fig. 528).

Fig. 528.—Posterior outline of the normal leg, suggesting the necessary padding to be used on the Cabot splint. When the foot is at a right angle with the leg, the heel rests lightly on the table.

region of the fracture is open to inspection anteriorly. Lateral inspection is facilitated by loosening the straps and lowering the side splints. Any deviation from the normal lines of the leg can be adjusted easily. At the end of three weeks, when the fracture is uniting and the callus is still soft, the leg should be removed from the splint and examined carefully from the front, from the back, and laterally for any deviation from the normal. If any deviation is discovered, it should be corrected and the leg put again into a posterior wire splint or into a removable plaster-of-Paris splint.

The first night after putting up the fracture the patient will probably be most uncomfortable. The new and restrained position, the after-effect of the anesthetic if one has been used, the points of undue pressure yet to be adjusted, the itching of the skin, the inability to move about, the necessity of lying in one position, actual pain at the seat of the fracture—all combine to make life miserable. It will be a wise precaution on the part of the attendant if a little morphin is administered subcutaneously this first

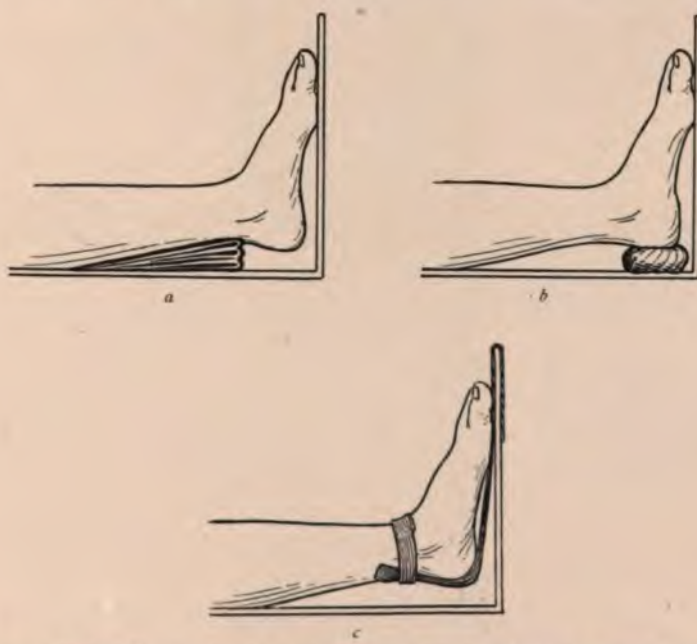

Fig 529.—Method of supporting the foot in fractures of the leg when using a posterior splint *a*, Padding beneath tendo Achillis; *b*, ring under heel; *c*, sling of adhesive plaster.

night, as patient, nurse, and physician will rest better. After the first night there will, under ordinary circumstances, be no especial difficulty. After the plaster splint is applied the Smith anterior wire splint attached to the anterior surface of the thigh, leg, and dorsum of the foot often will enable the leg to be slung just so as to clear the bed. This position is one of considerable comfort. The patient is enabled to move in bed a little and to change his position without disturbing the fracture. This anterior wire splint is made,

like the Cabot posterior wire splint, of iron wire, but is fitted to the anterior surface of the foot, leg, and thigh (see Fig. 531).

Fractures Difficult to Hold Reduced.—These are usually oblique fractures of the tibia, occurring most often in the lower half of the bone. The nearer to the ankle-joint the fracture is, the greater is the likelihood of a displacement which is hard to hold reduced.

Fig. 530.—Fractures of the leg. Cabot posterior wire splint and side splints, showing the space to be padded on each side of the leg and thigh.

The contraction of the quadriceps extensor tends to pull the upper fragment forward, the contraction of the gastrocnemius tends to pull the lower fragment backward and upward. The obliquity of the fracture and the action of these two groups of powerful muscles make it almost an impossibility to hold these fractures reduced. It is often, even under an anesthetic, impossible to cor-

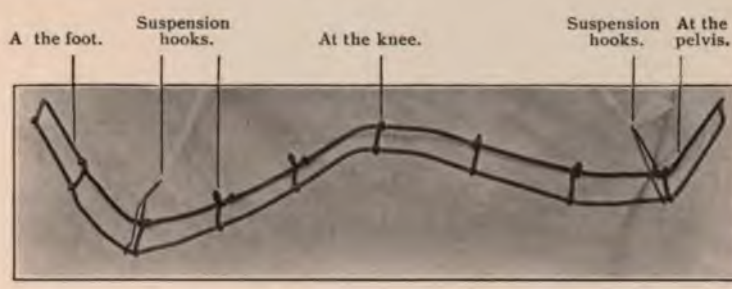

Fig. 531.—The anterior wire suspensory apparatus of N. R. Smith. This splint is applied to the anterior surfaces of the padded foot, leg, thigh, and hip. The splint is fixed to the leg by a bandage. The splint is intended to immobilize the leg and at the same time to suspend it, permitting motion at the hip, and to secure extension upon the distal fragments.

Fig. 532.—Fracture of the leg. Cabot posterior wire splint padded properly according to the curves of the normal leg. Note that the heel is free from the splint (see Fig. 528).

Fig. 533.—Fracture of the leg. Cabot posterior wire splint, side and posterior wooden splint held by straps. Adhesive plaster to foot and ankle.

rect the deformity without doing a tenotomy of the tendo Achillis. A posterior wire and side splints with the foot held fixed, with a moderate traction and pads placed at the seat of fracture, may be of service.

Fig. 534.—Short-Desault splint for the application of traction to lower leg fractures. Fracture at X. Extension strips *up* from the fracture are fastened at the top of the splints. Extension strips *down* from the fracture are fastened to the foot-piece. Tightening the screw at foot-piece makes traction and countertraction.

Fig. 535.—Plaster traction splint: *a*, Application of adhesive-plaster extension strips as in figure 534; *b*, plaster bandage allowing exit of extension straps. Note space left below the sole to allow for effective traction and buckles to which the upper extension is attached.

A plaster-of-Paris splint with extension and counterextension, after the principle of the Short-Desault apparatus and according to Lovett's adaptation (see Figs. 534, 535), will hold some of the more difficult cases.

Method of Application of the Traction Plaster-of-Paris Splint.—

From the seat of fracture running upward and from the seat of fracture running downward are applied extension adhesive plasters, with webbing attachments, as seen in the diagram (see Fig. 535). Below the foot, the size of the sole of the foot and two inches thick, is held a very firm pad of sheet wadding. A plaster bandage is applied to the leg, according to the usual methods, from the toes to above the knee. A buckle looking upward is incorporated in the plaster bandage upon each side of the leg a little above the level of the knee. A slit is left upon each side of the ankle for the lower extension webbings to come through (see Fig. 535). After the plaster has hardened the sheet-wadding foot-pad is removed. The upper extension straps are pulled snugly over the upper edge of the

Fig. 536.—Cabot posterior wire splint, as used or open ractures (lateral view). Note protective padding of splint beneath wound, X, to facilitate dressings without the removal of the leg from the splint.

plaster splint and fastened to the buckles on each side. Then the lower straps are pulled taut over the foot-piece of the plaster. Countertraction and traction are thus maintained upon the fragments of the fracture. A window is cut in the plaster to observe the position of the bones. This apparatus is efficient in many instances in which it is otherwise difficult to maintain reduction.

Operative interference with suture of the fragments of bone is the most effective method of treatment in troublesome cases. It is always wise to delay operating until after the primary effects of the injury have ceased—that is, until after the acute swelling has subsided and the damaged tissues have had time to recover themselves. A delay of ten days is time gained. During these ten days some one of the methods already mentioned may suc-

ceed in holding the fracture satisfactorily so that operation is unnecessary.

Treatment of Open Fractures of the Leg.—Treatment rests upon the presumption that every open fracture is infected. The object of treatment is to convert the open infected fracture into a closed

Fig. 537.—Cabot wire splint in open fractures, viewed from above. Leg in position; wound of soft parts seen; dressing removed; side splints and straps seen. Upper and lower ragments held by permanent bandages during inspection of the wound.

noninfected fracture. It is important that the first dressing of the wound should be a clean one. If it is a temporary dressing, the wound should be douched with boiled water, covered with a clean absorbent dressing, and the leg be placed upon a pillow splint.

The Permanent Dressing.—Every open fracture of the leg

should be anesthetized for careful examination, diagnosis, and the initial dressing. The leg should be washed with soap and water and scrubbed with a gauze sponge or soft nail-brush. The leg should be shaved of all hair in the vicinity of the wound, and should then be washed with liquid sodæ chlorinatæ (chlorinated soda), one part to twenty. This will most effectually free it from all grease and oily dirt.

The Wound of the Soft Parts.—This should be moderately enlarged to allow easy access to its deeper parts. There are, no

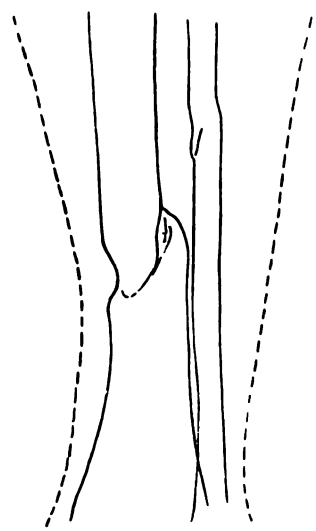

Fig. 538.—Fracture of both bones of the leg. Ununited fracture of tibia. Fibula united (Massachusetts General Hospital, 1190. X-ray tracing).

doubt, cases of fracture of the bones of the leg open from within outward in which the wound is small, evidently made by the bone, in which it is prudent to seal the wound and to regard the likelihood of infection as absent. These cases, chosen in the judgment of a wise surgeon, may do well, but they may not; therefore, the author believes it is safer to advise that all wounds of open fractures be enlarged for thorough cleansing. The blood-clot and detritus should be washed out by irrigating with a warm solution of corrosive sublimate, 1 : 5000. Irrigation should be supplemented by thorough scrubbing of the tissues of the wound by

small gauze swabs held in forceps. These swabs should be small enough to be carried into all the recesses of the wound. All bleeding should be checked. Loose bits of muscle, fat, fascia, and bone should be removed. Often the finger will detect bits of bone when the forceps will not. The firmly attached fragments of bone are to be left undisturbed. Regarding the treatment of the

Fig. 539.—Open fracture of both bones of the right leg in the lower third, six months after the accident. Note the deformity and enlargement of the leg near the ankle.

slightly fixed fragments of bone, the surgeon must judge in each instance. It is a good rule when in doubt about the viability of a fragment of bone to remove it. The deep fascia may need division to permit of a view of the depths of the wound. The fractured bones are then to be approximated and sutured, if practicable. The corners of the wound may be sutured. It is wise to leave the

wound open enough to receive several temporary gauze wicks for drainage during the first few days. Counteropenings may be needed if one is not sure of the aseptic condition of the wound. They do no harm and may prove safety-valves against latent infection. Before leaving the wound it should be thoroughly douched with boiled water. An aseptic dressing is applied, and the leg is immobilized by the posterior wire and side splints (see Figs. 536, 537) or is put up immediately in a plaster-of-Paris splint.

Fig. 540.—Lateral view of figure 539. Note discharging sinuses.

If the plaster-of-Paris splint is used, a window should be cut in it, through which the wound may be dressed.

Care of a Fracture of the Leg after the Permanent Dressing has been Applied.—All fractures of the leg will be placed, sooner or later, in the fixed plaster-of-Paris splint. One week after the splint is applied the patient may be up and about with crutches. At first, the hanging of the leg down may be attended by great discomfort. There may be a sense of fullness and of burning in the leg. The leg may feel as if it would burst. The toes may look blue and be swollen. As the patient becomes accustomed to these conditions, which are in themselves harmless, he will be able to

ignore them; they will grow less and less troublesome, and eventually disappear. At the end of four or five weeks the fracture should be found firmly united. A lighter plaster splint may be applied, extending only to the knee-joint, and allowing flexion of

Fig. 541.—Ligaments of normal ankle. The mortise for the astragalus is seen.

Fig. 542.—Pott's fracture (diagram). Fracture of fibula, tear of the internal lateral ligament. Displacement outward of foot. A sliding of the astragalus upon the articular surface of the tibia without a tilting of the astragalus upon its antero-posterior axis.

the knee. This thin plaster splint should be split, so as to be removable. After about four weeks the leg should then receive a daily bath and massage, with active and passive motion to the knee-joint. At about the eighth week the protecting splint may

be removed, a flannel bandage from the toes to the knee substituted, and the patient be allowed to touch the foot to the floor, bearing a little weight. As soon as the plaster is removed and the bandage substituted, a shoe, preferably laced, should be worn on that foot. From the tenth to the twelfth week after the injury the patient should be walking with a cane. According to present methods, a fractured leg would require from three to five months of treatment before restoration to normal function is completed.

The after-care of a case of fracture of the leg is attended with no little anxiety on the part of the surgeon. The general health of the patient is a matter of considerable concern. The loss of exercise entailed by the cramped and unnatural position causes loss of

Fig. 543.—Case: Open Pott's racture. Wound in soft parts and protruding tibia to be seen.

appetite, headache, constipation, dyspeptic ills, etc. The pain through the whole limb, due undoubtedly to the sprain and wrenching at the time of the injury, the aching at night at the seat of the fracture, combine to render the patient thoroughly uncomfortable, unhappy, and even melancholy. Pressure spots will appear about the most carefully applied bandage, and they must receive attention. Itching of the skin inside the splints is sometimes almost unendurable. To every patient daily general and local massage and bathing will be found to be of unspeakable comfort. The average hospital patient is far less sensitive to all the petty annoyances of an immovable and closely fitting dressing than is the private patient.

The Prognosis.—In children and young people the minimum time is consumed by the process of repair. The restoration of the leg to its normal function is more rapid than in the cases of adults, and there are fewer complications. In adults a chronic arthritis may appear in the neighboring knee- or ankle-joints.

Fig. 544.—Normal leg and foot at a right angle. Note the relative position of heel and leg.

Fig. 545.—Pott's fracture. Posterior displacement of the foot on the leg. Note the shortening of the foot from the toe to the front of the ankle. Compare the relative position of the heel and leg with the same in figure 544.

Swelling of the leg and ankle may persist for some time. Non-union of the bones may result, and necessitate operative measures (see Fig. 538). If the fracture is oblique, shortening may occur even after union takes place if the unsupported leg is used too soon and too much. If the wound of an open fracture heals quickly,

and there is little comminution of bone, repair will take place as in a closed fracture. Otherwise, an open fracture will unite more slowly than a closed fracture. Persistent swelling of the leg, particularly about the ankle, is associated with the convalescence from an open fracture. Necrosis of bone at the seat of fracture may occur in cases of open fracture even many months or years after the original injury. Abscesses and sinuses may form, necessitating operation for the removal of the necrosed bone (see Figs. 539, 540). If the fracture is near the knee- or ankle-joints, the prognosis is more uncertain than if the fracture is at the center of

Fig. 546.—Line of measurement to detect backward displacement of the foot on the leg.

the shaft. A comminuted fracture is more likely to be longer in uniting and to give rise to trouble after repair than is a single transverse fracture.

Results after Fracture of the Leg.—Of value in this connection are the results following fracture of the leg in thirty-five cases treated at the Massachusetts General Hospital, and examined one and a half to ten years after the accident. In the detailed report of these cases the exact lesion and its seat will be stated. In thirteen cases—in ten of which the age was forty-two, the rest under thirty—the result reported was that the injured leg was "as good as the other leg." In twenty-two cases the result was a leg

Fig. 547.—Pott's racture of left ankle. Method of examining ankle. Lateral mobility shown. Note the grasp of the foot and the leg.

Fig. 548.—Case: Fracture of the internal and external malleoli and displacement of the foot inward and backward.

permanently impaired in some particular. Some cases had flat-foot, deformity of the leg, limited motion at the knee-joint, lameness, necrosis of bone, pain in the fracture when the weather was damp. Other cases had pain in the leg upon standing, stiffness of the ankle, pain upon stepping on uneven surfaces, weakness of the leg, swelling of the leg and foot, cramps at night in the calf of the leg, or some combination of these symptoms.

Fig. 549.—Same as figure 548. Lateral displacement of foot inward (see X-ray tracing, Fig. 550).

Thrombosis and Embolism.—Thrombosis of the veins about a fracture, and particularly about a fracture in which there is some laceration of the soft parts, is not at all uncommon. At times, and rather more frequently than is generally supposed, emboli are detached from these thrombi and cause almost immediate death, with symptoms of pulmonary embolism—namely, a sudden cyanosis and great difficulty in breathing associated with intense precordial distress.

Thrombosis of the veins of the leg or thigh is undoubtedly one of the causes of the great edema seen after fracture of these parts.

Refracture of the Bones of the Lower Extremity.—It is not an uncommon experience to find that a patient with a fracture of the thigh, leg, or patella refractures the partially united bone. This refracture is due to either muscular violence or a slight fall. There is ordinarily little displacement of the fragments. The callus of the original injury holds the bones quite securely. The leg is usually bent at the seat of the fracture. Refracture is, therefore, practically a fracture of callus. This accident has even occurred while the patient is wearing a protective splint of plaster-of-Paris. Union in these cases is much more rapid than after the original injury. About one-half the time required for union of the original fracture is necessary for union of the refracture. The patient may, therefore, be much encouraged, for though the accident of refracture is a disheartening one, yet he will not be obliged to look forward to a long confinement.

POTT'S FRACTURE

Anatomy.—The anatomical relations of the lower ends of the fibula and tibia and the astragalus and os calcis should be kept constantly in mind. The os calcis and astragalus are held firmly together, forming the posterior portion of the foot. The astragalus rests mortise-like between the internal and external malleoli (see Fig. 541). The strength of the inferior tibiofibular articulation depends upon the strong inferior tibiofibular ligaments, particularly upon the interosseous ligament.

By Pott's fracture of the ankle is understood the injury caused by forcible eversion and abduction of the foot upon the leg. The lesions which may be present in this fracture are a rupture of the internal lateral ligament, a fracture of the tip of the internal malleolus, a separation of the lower tibiofibular articulation, an oblique fracture of the fibula two or three inches above the tip of the external malleolus, a fracture of the outer edge of the lower end of the tibia. Ordinarily, the mechanism of the fracture is somewhat as follows: As the foot is abducted, the strain is felt at the internal lateral ligament and at the inferior tibiofibular interosse-

ous ligament, and these give way. If the force continues, the fibula breaks (see Fig. 542). If the force still continues, the internal malleolus is pushed through the skin, and an open fracture results (see Fig. 543). If the internal lateral ligament holds against this lateral force, the tip of the internal malleolus may be pulled off.

Symptoms.—The ankle presents a very constant appearance after this fracture. A traumatic synovitis exists. Great swelling appears, at first chiefly upon the inner side of the ankle. The ankle-joint becomes distended with blood and serum. All the

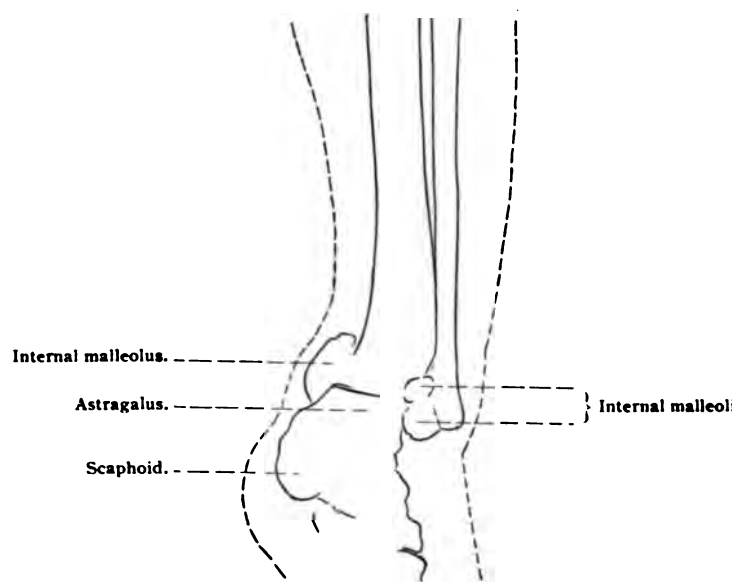

Fig. 550.—Fracture of both malleoli (anteroposterior view). Inversion of foot (X-ray tracing).

natural hollows about the joint are obliterated. The foot is everted, appearing to have been pushed bodily outward. The internal malleolus is unduly prominent. Some of this prominence is masked by the swelling. The bony connections and natural support of the foot having been removed, the foot drops backward, partly because of the pull of the calf-muscles, but chiefly because of its own weight (see Figs. 544, 545). The deformity, therefore, is a double one, a lateral sliding of the foot outward and an anteroposterior dropping of the foot backward. The malleoli

are spread apart; the measured distance between them is increased over the normal. Palpation close above the anterior articular edge of the tibia and the astragalus reveals tenderness over the ruptured tibiofibula ligament. The backward displacement is best measured by the length of the line from the front of the ankle to the cleft between the first and second toes (see Fig. 546). This line will be found shortened upon the injured side. There is tenderness over the fracture of the fibula. If the internal malleolus is fractured, the sharp ridge at the broken edge can be distinctly

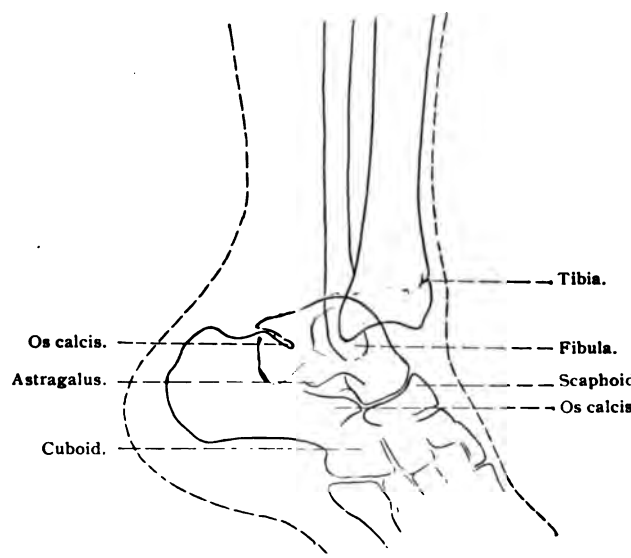

Fig. 551.—Fracture of the tip of each malleolus. Dislocation of the foot backward. Note the prominence in front of the ankle. Same case as figure 550 (X-ray tracing).

felt. Grasping the posterior part of the foot firmly with the whole hand while the other hand steadies the lower leg just above the ankle, abnormal lateral mobility of the foot may be detected (see Fig. 547). The foot will be felt to move inward to its natural position. The moment inward pressure is removed the foot will be seen and felt to slump outward again.

Figures 548–551 inclusive illustrate a reversed Pott's deformity, the foot having moved inward instead of outward as well as having fallen backward.

Treatment.—The indications for treatment are to place the parts

in their normal relations, and to maintain them so until repair is completed, guarding against both the lateral and the posterior deformities. If for any reason, such as the presence of very great swelling of the ankle, it is expedient to delay reduction, the leg should be placed temporarily in a pillow and side splints (see Figs. 517, 518, 519). An anesthetic should always be administered before the reduction of this fracture. The reduction is thus rendered painless and, through relaxation of the muscles, is made far easier. The principles of the old Dupuytren splint are the ones to be applied in the reduction of this fracture whatever the apparatus in which the leg is permanently placed. These consist of the

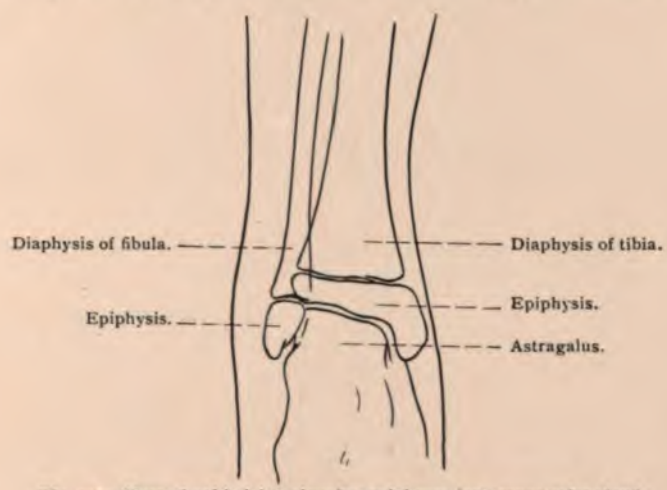

Fig. 552.—Normal ankle-joint, showing epiphyses (anteroposterior view).

making of lateral outward pressure upon the internal malleolus, lateral inward pressure upon the foot, and a forward lift upon the posterior part of the foot or heel. The practitioner may very properly use the Dupuytren splint. It is thought to be uncomfortable, but it is not if properly applied. It is very efficient in holding the fracture reduced.

The Dupuytren Splint.—This is a board from one-quarter to one-half of an inch thick, long enough to extend from the middle of the thigh to six inches below the sole of the foot, and as wide as the calf of the leg from front to back (see Fig. 560). At its lower or foot end it is serrated with three or four teeth, as seen in the

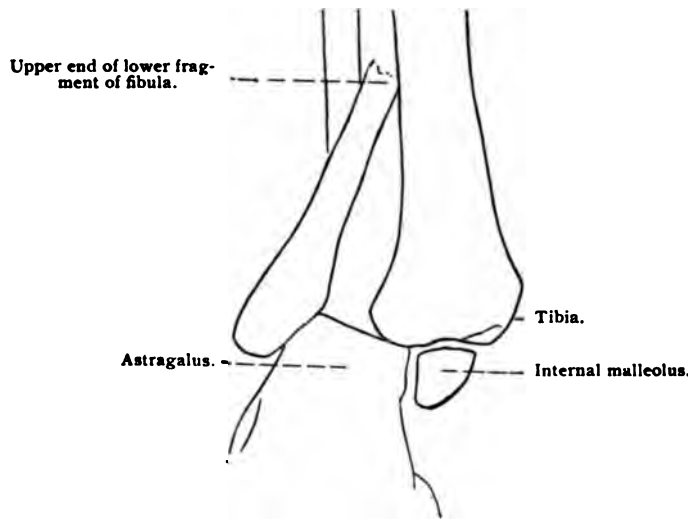

Fig. 553.—Pott's fracture (anteroposterior view). Notice sliding of astragalus outward. Fracture of internal malleolus. Fracture of fibula. Extreme deformity (X-ray tracing).

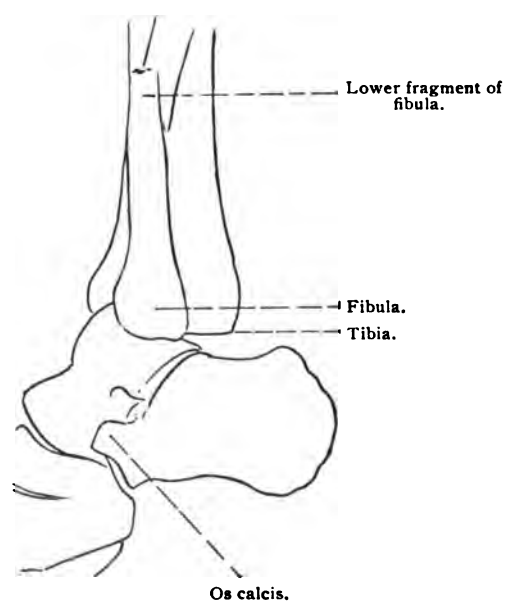

Fig. 554.—Pott's fracture. Same as figure 553 (lateral view).

illustration. It is padded with folded sheets, so that when it is applied to the inner surface of the limb, the padding extends to just above the level of the internal malleolus, the serrated end of the

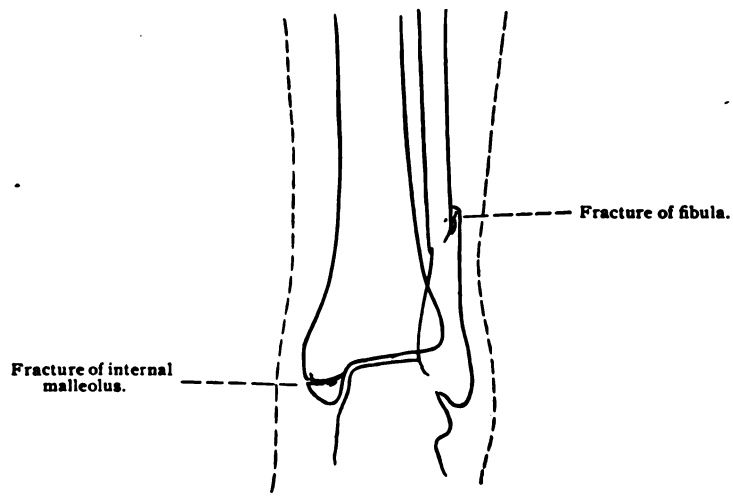

Fig. 555.—Pott's fracture. Almost no displacement. Compare with figure 553 (Massachusetts General Hospital, 828. X-ray tracing).

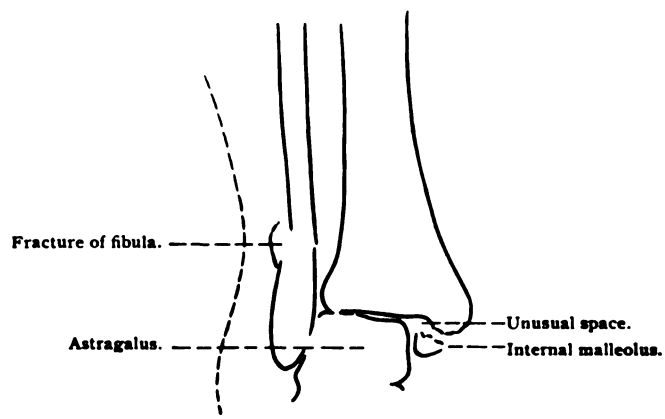

Fig. 556.—Pott's fracture. Notice sliding of astragalus outward. Fractures of internal malleolus and fibula (Massachusetts General Hospital, 548. X-ray tracing).

splint projecting six inches below the sole of the foot. The padding, as seen in the illustration, is so thick at the lower end over the internal malleolus that sufficient room is left for inversion and

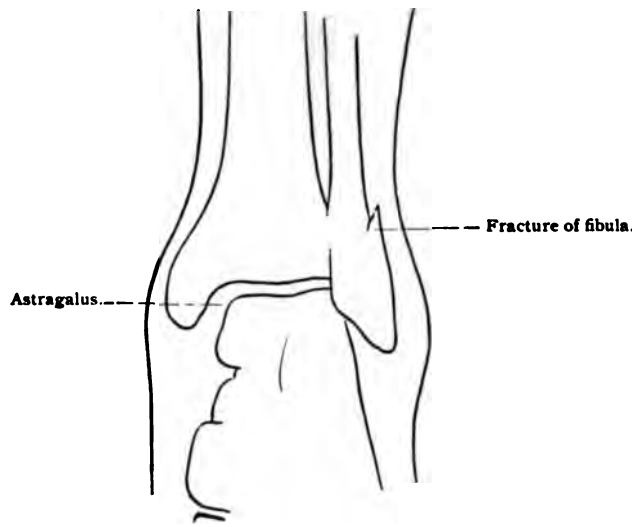

Fig. 557.—Pott's fracture, showing fracture of the fibula and but slight sliding of the astragalus, a sufficient distance, however, to have made a rupture of the internal lateral ligament highly probable (X-ray tracing).

Fig. 558.—Splintering of the lower end of fibula (Massachusetts General Hospital, 1105. X-ray tracing).

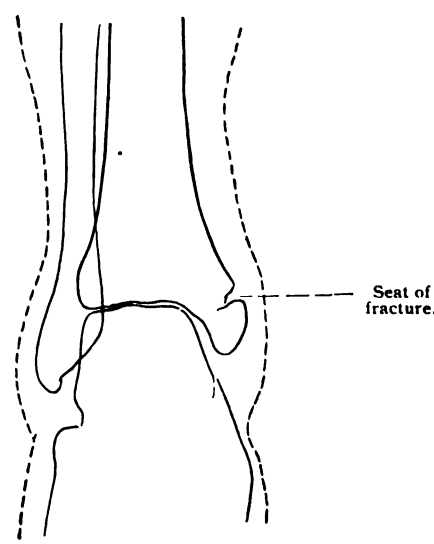

Fig. 559.—Fracture of the internal malleolus (Massachusetts General Hospital, 1084. X-ray tracing).

rotation of the foot upon its anteroposterior axis without its impinging upon the splint in the least. The splint is held in place by straps and buckles: one is placed above the ankle, one above the knee, and a third is placed at the upper end of the splint. For the proper application of the splint an assistant is needed. The splint is applied while the leg rests upon the bed. An assistant steadies

Fig. 560.—Pott's fracture. Dupuytren's splint. Note length of splint; position of straps; arrangement of padding; space between foot and splint.

the splint and the leg so that they both project clear of the foot of the bed. A roller bandage is then applied in circular turns about the ankle and splint from the splint toward the leg. After two circular turns are made, the assistant adducts and inverts the ankle and foot, and this position is held by the third turn of the bandage, which is passed around the forward part of the foot and over one

of the serrations of the splint (see Fig. 561). In order to hold this firmly a turn is then taken around the ankle. A figure of eight is then applied for several turns about the foot and ankle, crossing the ankle in front of the instep at each turn. Each succeeding turn is caught by the succeeding serration of the splint.

Fig. 561.—Pott's fracture. Dupuytren's splint. Note serrations of splint and turns of bandage adducting foot.

Fig. 562.—Cabot posterior wire splint bent at the ankle for a Pott's fracture of the right leg. To be used to assist in maintaining adduction of the foot.

At the same time the foot is lifted forward by pressure from behind, and this forward lift is maintained by circular turns of the bandage. The whole limb is placed upon pillows. Thus, the eversion and posterior dropping of the foot are corrected. This splint forms a good temporary or emergency dressing for Pott's

fracture. This dressing corrects the eversion, but there is great danger that the foot may slump backward unless most carefully watched. This failure to hold the posterior displacement corrected is the defect of the Dupuytren splint.

The Posterior Wire Splint with Curved Foot-piece (see Figs. 562, 563, 564).—The posterior wire splint extending to the middle of the thigh is another apparatus used in treating Pott's fracture.

Fig. 563.—Pott's fracture. Cabot posterior wire splint and side splints. Note position of lateral pads and twisted foot-piece. Side splints are shown unpadded (diagram).

The foot-piece should be twisted at the ankle, so as to hold the foot when inverted (see Fig. 562). The splint is covered and padded in the usual way (see p. 365). The patient is anesthetized. The leg is placed upon the splint. The foot is strongly inverted by great lateral pressure put upon the posterior part of the foot. This inversion of the foot can not be made too strongly, for the deformity can not be overcorrected. The position of extreme inversion is not a painful one to maintain. Ordinarily, the lateral pressure

applied is too slight entirely to correct the deformity. The foot is held to the inverted foot-piece by straps of adhesive plaster, pads, and side splints (see Fig. 563). A pad is applied to the sole of the foot, and so placed as to maintain the long anteroposterior arch of the foot. It is found that if this is not done, there is considerable flattening of this arch upon recovery. The forward lift upon the foot is made and maintained by proper padding posteriorly to the lower leg and just above the heel (see Fig. 564). The lift may be reinforced by smoothly applied strips of adhesive plaster placed laterally on the foot and carried under the heel and up and over the end of the foot-piece. These adhesive-plaster strips serve as a sling for the foot. There is one other way to avoid pressure upon the point of the heel, and that is by placing beneath the heel a ring

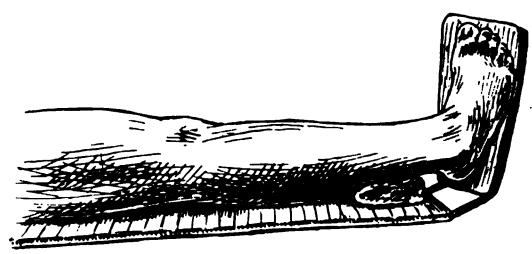

Fig. 564.—Pott's fracture. Cabot posterior wire splint, adapted to the adducting of the foot. See figure 530 for method of slinging foot and preventing its backward displacement (diagram).

of sheet wadding covered with a tightly wound bandage (see Fig. 530). These methods of protecting the heel from pressure may all be used at one time to advantage. The side splints are applied with great care, being so padded as to maintain the outward pressure upon the inner surface of the lower end of the tibia, and the inward pressure upon the outer surface of the foot. Very great care must be exercised that there is no recurrence of the deformity. Frequent readjustments are necessary.

The Lateral and Posterior Plaster-of-Paris Splints (Stimson's Splint).—The *posterior* splint (see Fig. 565) extends from the toes along the sole of the foot around the back of the heel and up the back of the leg to the knee or to the middle of the thigh. The *lateral* splint (see Fig. 566) begins at the external malleolus, passes

over the dorsum of the foot to the inner side under the sole, and upward along the outer side of the leg to the same height as the posterior splint. Each of these splints is made of about six or eight strips of washed crinoline, four inches wide and long enough to extend from around the foot to the bend of the knee or middle of the thigh. The leg is protected by roller bandages of sheet wadding. Plaster cream is rubbed into the crinoline strips one after the other

Fig. 565.—Pott's fracture. Stimson's splint. Posterior plaster (represented two inches too long at the upper end).

until all the strips have been used. The posterior splint is applied first, and held snugly by a gauze bandage to the leg and foot. Then the remaining crinoline strips are likewise covered with plaster cream and applied as the lateral splint (see Fig. 567). This is also held snugly by a gauze bandage to the leg and foot. During the application of the splint and until the plaster-of-Paris has set, the foot should be held in a corrected position by an assistant.

These two plaster-of-Paris splints are preferable to the encircling plaster splint, the ordinary "plaster leg," for by their use the ankle can be inspected. Less judgment is requisite in its application to insure the correction of the deformity than by the use of the ordinary "plaster splint." As the swelling subsides and the plaster

Fig. 566.—Pott's fracture. Stimson's splint completed. Lateral plaster and posterior plaster.

becomes loose, if the splints are kept tight by bandaging, the deformity can not possibly recur.

Care of the Fracture after the Permanent Dressing is Applied.—If the posterior and side splints are used: After the initial swelling has subsided—*i. e.*, after the first week—the leg may be placed in a plaster-of-Paris splint (circular bandage), and the patient allowed

up and about with crutches. The plaster should be split after application and held in place by straps or a bandage. If the Stimson splint is used, the patient may be allowed up and about with crutches at the end of the first week.

Massage may be applied to the exposed parts of the leg and foot daily. At the third week all dressings should be removed, and gentle massage applied to the whole leg from toes to groin, especial attention being paid to the region of the ankle. Massage and gentle passive motion in an anteroposterior direction only should be applied at least once or twice daily after the second week. All lateral motion is to be avoided. After the fifth or sixth week a flannel

Fig. 567.—Pott's fracture. Stimson's splint removed. Lateral and posterior plasters.

bandage will be all the support needed, although comfort may demand a thin, stiff, retentive splint at times. At the end of two months some weight may be borne upon the foot.

Of the three methods of dressing a Pott's fracture the posterior and lateral plaster splint of Stimson is by far the simplest, and it is efficient in every way. Moreover, it allows of massage being instituted early with the least disturbance to the ankle. The posterior wire splint is more difficult of application, and needs careful watching and frequent readjustment. With the posterior wire splint in use the foot or leg is easily accessible to early massage by simply loosening the side splints.

Prognosis and Results.—In young adults there should be no deformity and almost no permanent disability. In adults there will be some stiffness for a time. If the lateral deformity has not been completely corrected, a traumatic pronation of the foot will result. The longitudinal arch of the foot should be supported always by a suitable pad under the instep for at least six months following this fracture, whether there is deformity or not. If there is deformity, it will relieve the pain. An insole of leather with a pad stitched to it for support to the arch of the foot is often of great service. If there is no pain or deformity, it will strengthen the foot until walking is easy again, and will prevent deformity appearing. If the anteroposterior deformity has not been corrected, pain may be experienced upon using the foot. The foot is shortened and dorsal flexion is much hindered, so that the gait is decidedly impaired. The patient will walk with a more or less stiff ankle. In those cases in which there is great deformity associated with extensive laceration of the soft parts, the foot and ankle may for many weeks subsequent to union be painful, stiff, and swollen. Pain, stiffness, and swelling increase with the age of the patient—*i. e.*, the younger the patient, the less discomfort will there be following this fracture.

The Operative Treatment of Old Pott's Fractures.—The indications for operation will be persisting lateral or backward displacements. The only method for the relief of these deformities is by osteotomy of the tibia and fibula. The results following this operation are satisfactory.

Open Pott's Fracture (see Fig. 543).—The ankle-joint is involved. Two things are to be considered in deciding upon the treatment of the injury—the extent of the laceration of the soft parts and the amount of injury to the bones. If the laceration is so great that the foot is useless, amputation is indicated. Amputation is indicated in only two other instances—old age and sepsis. If the laceration is not great, and any existing dislocation can be reduced, it should be reduced without excision, proper drainage being provided, both anteriorly and posteriorly, to the joint. If the laceration is not great and reduction of the deformity is impossible, then either partial or complete excision should be done.

If there is great injury to bone, whether the dislocation can or can not be reduced, a partial or complete excision should be done. In every open Pott's fracture, no matter how small the wound of the soft parts, in order to insure an aseptic wound it should be enlarged sufficiently for thorough cleansing with antiseptic solutions in every part. Extreme conservatism should characterize the treatment of recent open Pott's fracture. In the large majority of cases treated upon the conservative or expectant plan a useful ankle-joint and foot will result. The older the adult patient is, the more radical must be the treatment.

CHAPTER XV

FRACTURES OF THE BONES OF THE FOOT

Fracture of the astragalus is caused by a blow on the sole of the foot, as in a fall from a height (see Fig. 568). Fracture of the os calcis is often present in the same foot with fracture of the astragalus. The ankle-joint may or may not be involved. The diagnosis is difficult without the use of the Röntgen ray. Crepitus may be elicited. Great swelling may appear in the region of the fracture.

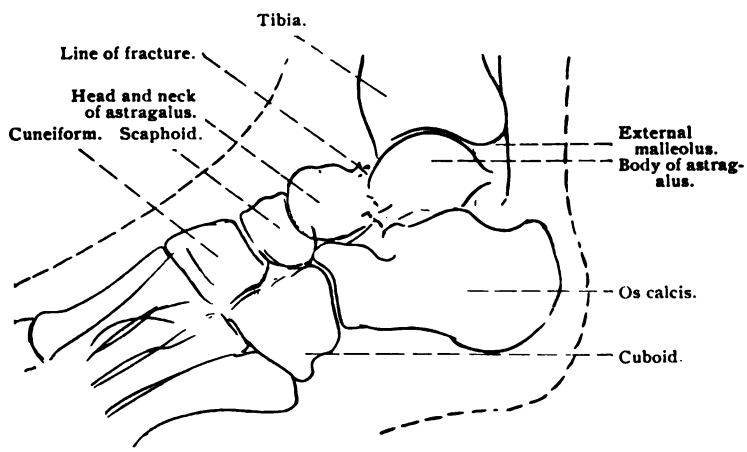

Fig. 568.—Fracture of the neck of the astragalus (X-ray tracing).

It is highly probable that many cases of sprained ankle have been cases of fracture of the astragalus. If there is no displacement, treatment will consist in immobilizing the ankle-joint with the foot held at a right angle with the leg. As soon as the swelling has begun to subside, massage may be used to advantage and convalescence be thus hastened. The most satisfactory dressing is a plaster-of-Paris splint extending from the toes to below the knee, applied and immediately split open, so as to form a removable splint. This may be taken off for massage and passive motion.

Recovery takes place with fair movement at the ankle-joint, so that after from two months and a half to three months the patient can walk without support. After this time complete recovery is

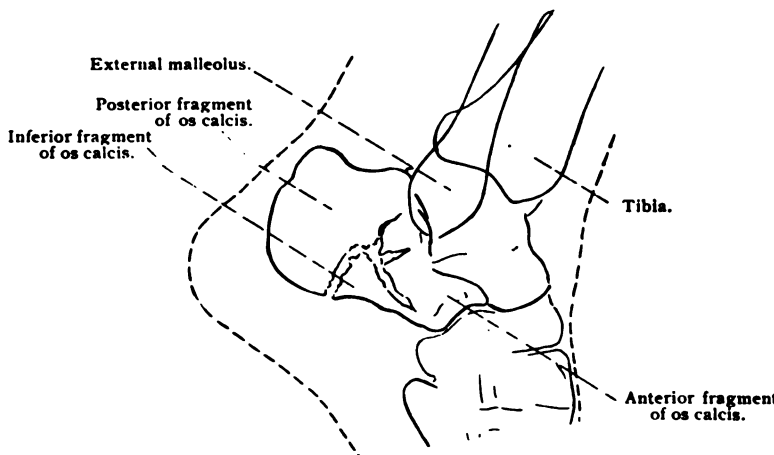

Fig. 569.—Fracture of the os calcis in the body of the bone (X-ray tracing).

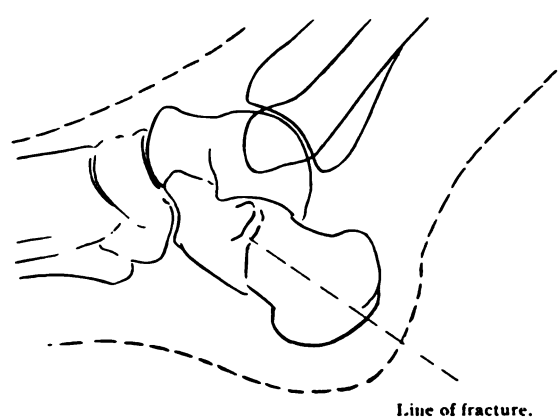

Fig. 570.—Fracture of the os calcis, almost transversely across the junction of the body and neck (X-ray tracing).

slow. More or less stiffness and pain may exist for four or six months after the accident.

Fracture of the Os Calcis.—The os calcis is fractured by a fall on the sole of the foot, as well as by a powerful contraction of the gastrocnemius muscle and strong tension upon the tendo Achillis.

It may be crushed, fractured transversely or longitudinally, or a piece may be torn off from its posterior portion near the insertion

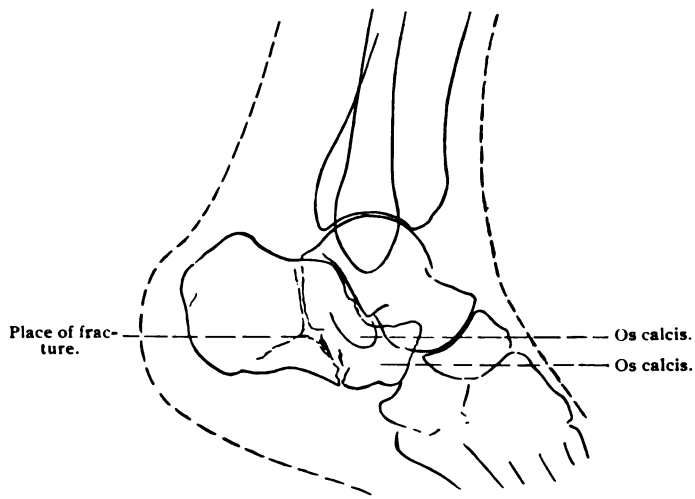

Fig. 571.—Fracture of the left os calcis through the body of the bone (X-ray tracing).

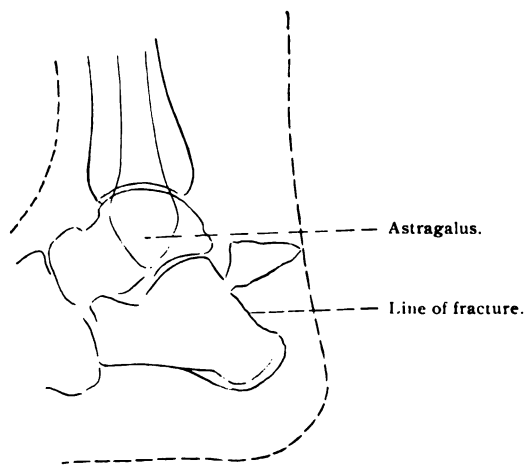

Fig. 572.—Fracture of the os calcis. The part torn off is that to which is attached the tendo Achillis. Notice displacement (Massachusetts General Hospital, 1652. X-ray tracing).

of the tendo Achillis (see Figs. 569, 570 inclusive). The symptoms of fracture will be the usual ones of crepitus, swelling, pain, abnormal mobility. The heel is seen, by comparison with its unin-

jured fellow, to be enlarged. This fracture is sometimes associated with fracture of the astragalus (see Fig. 575). The treatment

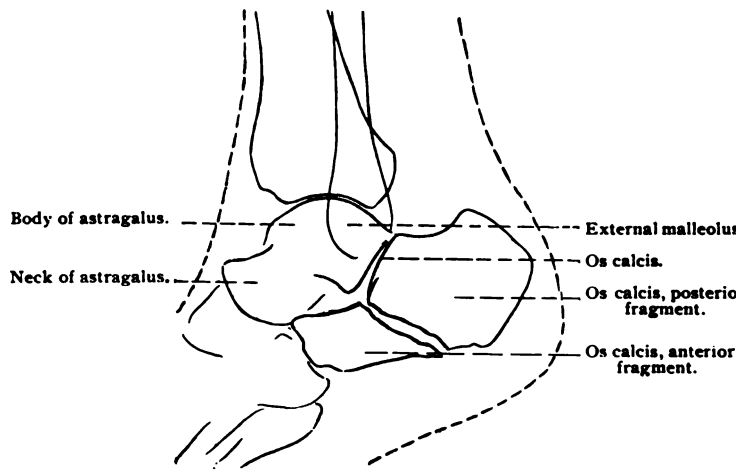

Fig. 573.—Fracture of the right os calcis. Same patient as figure 568.

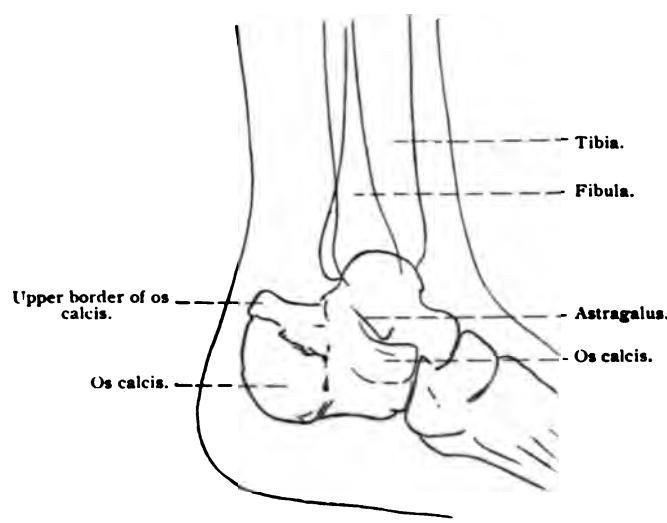

Fig. 574.—Fracture of the os calcis without great displacement (Massachusetts General Hospital, 102. X-ray tracing).

is to immobilize the foot at the angle that will best hold the fragment approximately in apposition. Complete plantar flexion of the foot may be needed to bring the fragments well into position.

The pull upon the tendo Achillis is in this position removed from the posterior fragment. Massage should be instituted early—during the first week. The removable plaster-of-Paris dressing is the best form of splint. After three weeks the splint should be removed, and a close fitting flannel bandage applied, with small pads under the malleoli and on each side of the tendo Achillis. The pads, if applied with considerable pressure, will assist very materially in reducing the swelling and in restoring form to the ankle. It will be about two months before the patient should bear much weight upon the foot. After three to four months walking will be comparatively easy. It is often the case after fracture of the os calcis and also after fracture of the astragalus that there is

Fig. 575.—Case: Posterior view of fracture of right os calcis and of left astragalus. Deformity. Note fullness each side of the tendo Achillis (see X-ray tracings 568 and 573).

considerable disturbance of the normal mechanism of the foot. A traumatic flat-foot results from the accident. This can be greatly relieved by the introduction into the shoe of a leather pad, to raise the instep and take the strain off the injured part. The patient may find that for a period of six months or more the wearing of this pad is a great support and comfort. The hot-air baking is very satisfactory for the relief of the pain and stiffness felt throughout the ankle and foot. The hot-air treatment, combined with massage, helps to hasten convalescence. This treatment should be used once daily until the pain in the foot has disappeared.

Open fracture of the astragalus and os calcis, if treated anti-

septically, recovers with a useful ankle and foot even though the ankle-joint is ankylosed. The mediotarsal joint becomes more flexible than it ordinarily is. The loss of motion at the ankle-joint is compensated for by the mediotarsal joint motion, and the individual may walk with hardly a perceptible limp. Removal by operation of the fractured bone is attended by good functional results, and if the bone is much comminuted or dislocated, operation is indicated.

Fracture of the Metatarsal Bones (see Fig. 576).—This fracture

Fig. 576.—Metatarsus and phalanges, showing epiphyses at fifteen years (Warren Museum, specimen 537).

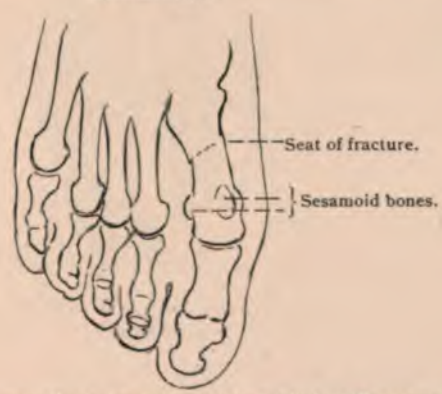

Fig. 577.—Fracture across the first metatarsal of the right foot (X-ray tracing).

is caused by direct violence. There is evidence to show that indirect violence may cause a fracture of metatarsal bones. The first and fifth bones are the ones most often broken (see Fig. 577). The symptoms are swelling, pain, crepitus, and abnormal mobility. The weight can not be borne upon the foot without pain. There is never great displacement. In order to avoid trouble in walking after union has occurred, it is wise to make the approximation of the fragments as nearly accurate as possible. A closed or simple fracture is ordinarily uncomplicated. Union takes place in from three to four weeks. It

will be at least from two to four months before the foot can be used without thought of the injury received.

If the fracture is open, repair will be slower than after a closed fracture. If the wound is kept clean and free from infection, no complications will arise. If, on the other hand, the wound becomes infected, necrosis of bone, abscess formation, burrowing of pus, and great swelling of the foot may occur, all of which will greatly delay the healing process. The foot should be immobilized by a lateral molded splint of plaster-of-Paris. This should be placed upon either the outer or inner side of the ankle, according as the outer or inner metatarsals are broken. The splint should

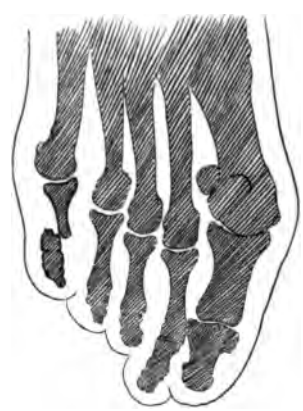

Fig. 578.—Fracture of the first phalanx of the little toe (Massachusetts General Hospital, 115. X-ray tracing).

extend from the middle of the calf of the leg to the tips of the toes. It is held in position by a roller bandage of gauze.

Fracture of the Phalanges of the Foot.—These fractures are rather unusual, except from a crush of the foot (see Fig. 578). They are sometimes open. The same general rules of treatment apply to fractures of these bones as to fractures of the phalanges of the hand. A simple plantar splint of splint wood, padding of the toes, and adhesive-plaster straps will be sufficient to hold the fracture. If the plantar splint covers the entire sole of the foot, it will prove of great comfort. It is sometimes wise to immobilize the ankle-joint by the thin plaster side splint, particularly if there is swelling of the leg and ankle.

CHAPTER XVI

ANATOMICAL FACTS REGARDING THE EPIPHYSES

HITHERTO our knowledge of injuries to the epiphyses has been obtained mainly through clinical and pathological observation. This knowledge is only approximately correct. With the assist-

Fig. 579.—Epiphyses of humerus at eight years (Warren Museum, specimen 334).

Fig. 580.—Relation of the capsule of the shoulder-joint to the upper epiphyses of the humerus (diagram).

Fig. 581.—Relation of the capsule of the knee-joint to the patella, femur, and tibia (diagram).

ance of the Röntgen ray a very great advance is being made in the accuracy of our knowledge of the epiphyses. Whereas there will, perhaps, always exist differences in the times of the appearance of the ossification centers and the times of union of the epiphyses, the

discrepancies in each observer's series of cases will grow less and less.

The importance of an exact knowledge of the epiphyses to those having to do with injuries in the neighborhood of joints is undoubted. The diagnosis, prognosis, and treatment of joint injuries and injuries in the immediate vicinity of joints is far more satisfactory than ever before. The book by John Poland upon "Traumatic Separation of the Epiphyses," from which the following data are largely taken, marks an era in this branch of surgery. Only those facts that are considered especially important for practical everyday use are here mentioned.

THE DATE OF THE APPEARANCE OF OSSIFICATION IN THE CHIEF EPIPHYSES OF THE LONG BONES

(*After Poland*)

At birth	Lower end of femur. Upper end of tibia.
At one year	Upper end of femur. Upper end of humerus.
At one and one-half years	Lower end of tibia. Lower end of humerus.
At two years	Lower end of radius. Lower end of fibula.
At three years	Great trochanter of femur. Great tuberosity of humerus.
At four years	Upper end of ulna. Upper end of fibula.
From five to six years	Upper end of radius.
At eight years	Lower end of ulna. Lesser trochanter of femur.

After a most exhaustive study of pathological and clinical material, both of his own and that of other observers, Poland concludes that the order of frequency of separation of the epiphyses is about as follows:

1. The upper epiphysis of the humerus.
2. The lower epiphysis of the femur.
3. The lower epiphysis of the radius.
4. The lower epiphysis of the humerus.
5. The lower epiphysis of the tibia.
6. The upper epiphysis of the tibia.

The upper epiphysis of the humerus is composed of three separate centers of ossification: That for the head, appearing at two years; that for the great tuberosity, appearing at three years; that for the lesser tuberosity, appearing at four years. These three centers coalesce to form the upper epiphysis, and it unites, at from the twentieth to the twenty-fourth year, to the diaphysis of the humerus (see Fig. 579). (For Separation of this Epiphysis see p. 132.)

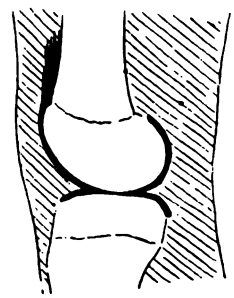

Fig. 582.—Relation of the capsule of the knee-joint to the lower epiphysis of the femur and the upper epiphysis of the tibia (diagram).

Fig. 583.—Epiphyses at the wrist at seventeen years: *a*, Ulna; *b*, posterior surface of the radius; *c*, anterior surface of the radius (Warren Museum, specimen 447).

Separation of the upper humeral epiphysis will not necessarily, excepting in cases of very great violence, open the shoulder-joint, for the capsule is firmly attached to the epiphysis and the synovial membrane is loosely attached to the diaphysis (see Fig. 580). In the adult the epiphyseal line marks the upper limit of the surgical neck.

The lower epiphysis of the femur, the largest epiphysis in the body, appears before birth, attains a good size by two years, and

unites to the diaphysis at from the twentieth to the twenty-third year. (For Separation of this Epiphysis see p. 314.)

The adductor tubercle is on the diaphysis marking the level of the line of the epiphysis upon the inner side of the femur. The two heads of the gastrocnemius muscle are attached to both the epiphysis and the diaphysis, but chiefly to the diaphysis. The plantaris is attached to the diaphysis. Both of these muscles, in a separation of the epiphysis, are stripped from the shaft with the periosteum, and act solely on the detached epiphysis, causing it to rotate upon its transverse axis. In separations without

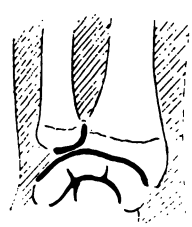

Fig. 584.—Relations of the synovial membrane of the wrist-joint to the epiphyses of the radius and ulna. Note also the inferior radio-ulnar joint and synovial membrane (diagram).

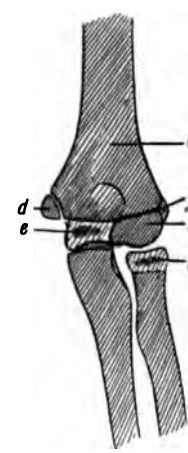

Fig. 585.—Diagram of the epiphyses at the elbow, about the fourteenth year: *a*, Shaft of humerus; *b*, capitellum; *c*, head of radius; *d*, internal condyle; *e*, trochlear; *f*, external epicondyle.

much displacement the knee-joint is not opened. The quadriceps bursa may escape injury (see Figs. 581, 582).

The lower epiphysis of the radius appears about the second year, and unites to the shaft at from the nineteenth to the twentieth year. (For Separation of this Epiphysis see p. 235).

The synovial membrane of the wrist-joint does not touch the epiphyseal line of the radius either anteriorly or posteriorly. It takes its origin from the lower articular margin of the epiphysis. The synovial membrane of the inferior radio-ulnar articulation extends above the epiphyseal lines of both the radius and ulna.

It is loosely connected with the diaphysis of each bone. In epiphyseal separations laceration of the synovial pouch is possible, but is not absolutely inevitable (see Figs. 583, 584).

The lower epiphysis of the humerus is formed from three separate centers of ossification—viz., the capitellum, which appears at three years; the trochlea, which appears at eleven years; the external epicondyle, which appears at thirteen years (see Fig.

Fig. 586.—Tibia showing epiphyses (Warren Museum, specimen 417).

Fig. 587.—Fibula, showing epiphyses (Warren Museum specimen).

585). These three centers coalesce at about the fifteenth year, to form the lower humeral epiphysis. The epiphysis unites to the diaphysis at about the seventeenth year. The epiphysis for the internal epicondyle forms no part of the lower humeral epiphysis. It appears at about the fifth year, and joins the diaphysis at from the eighteenth to the twentieth year. (For Separation of this Epiphysis see p. 175.)

The synovial membrane at about the fifteenth year and after-

ward overlaps the epiphyseal line. The epiphyseal line is a little higher on the outer side than on the inner. It inclines obliquely downward and inward. The epiphysis is thinner internally than externally.

The epiphysis of the lower end of the tibia appears about the second year, and unites to the diaphysis about the eighteenth or nineteenth year. Neither anteriorly nor posteriorly does the synovial membrane come in contact with the epiphyseal line, so that, unless great violence is exercised or the epiphysis is fractured, the ankle-joint is unopened in separation of this epiphysis (see Figs. 586, 587).

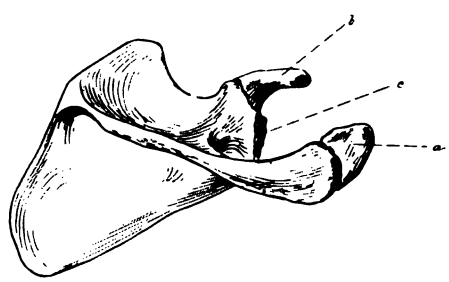

Fig. 588.—Right scapula from above and behind: *a*, Epiphysis of acromion; *b*, epiphysis of coracoid process; *c*, epiphysis of glenoid cavity (from specimens in Warren Museum).

Fig. 589.—Relation of the capsule of the hip-joint to the upper epiphysis of the femur.

The epiphysis of the upper end of the tibia (see Fig. 586) appears at about the first year, and unites to the shaft at the twentieth or twenty-second year. The synovial membrane is quite a little distance from the line of the epiphysis. The epiphyseal line runs quite close to the superior tibiofibular articulation.

The acromion process of the scapula (see Fig. 588) presents an epiphysis that appears at from the fourteenth to the sixteenth year, and unites at from the twenty-second to the twenty-fifth year. The epiphysis includes the oval articular facet for the clavicle. The coracohumeral and acromioclavicular ligaments are attached to it. The epiphysis joins the acromion behind the acromioclavicular joint.

CHAPTER XVII

GUNSHOT FRACTURES OF BONE

THE civil surgeon rarely has opportunity to study the effect upon bone of bullet wounds. He may see in his practice a few gunshot fractures. His experience is necessarily limited. The facts contained in this brief chapter are taken from the experience of such military surgeons as Kocher, Treves, Nancrede, Makins, Senn, Borden, La Garde, and others who have during the past few years studied scientifically this important class of wounds.

In the construction of the modern military rifle several important changes have been made. The bore of the rifle has been reduced. The caliber of the bullet has been lessened. The velocity of the bullet at the muzzle has been increased. The trajectory is more flat. The revolution of the bullet upon its long axis is increased.

As a general result of these various changes the modern military rifle has a great range and great accuracy. The effect of the modern bullet upon bone is described as concisely as is possible in the following paragraphs.

The amount of the damage done to bone is dependent upon several factors: The greater the velocity of the bullet when the bone is struck, the greater will be the destruction of the bone. The muzzle velocity of the modern bullet is ordinarily about two thousand feet a second. The less the velocity, the less will be the destructive effects. The velocity may be just sufficient to break the bone and not to carry the bullet through the limb. The severity of the injury therefore decreases in proportion to the distance which intervenes between the rifle and the object struck. The trained military surgeon may read the range in the character of the damage done. The more pointed bullet secures for itself greater penetration and perforation. The bullet acts like a steel wedge driven with great velocity through the soft and hard parts.

The primary collision area is small. The only indisputable evidence of a low velocity is the lodgment of an undeformed bullet. The resistance offered by the tissues is lessened and the resulting

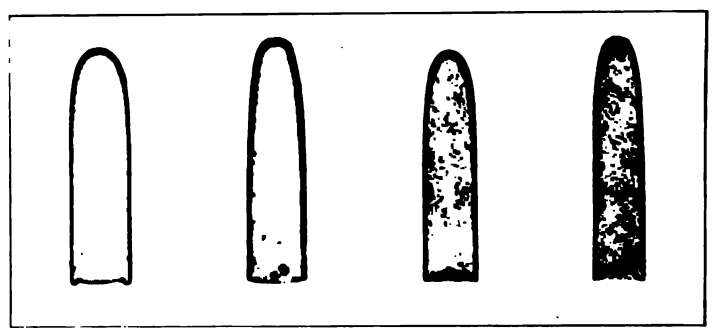

1 2 3 4

Fig. 590.—Sections of bullets to show relative shape and thickness of mantles: 1, Geudes: regular dome-shaped tip; mild steel mantle; thickness at tip, 0.8 mm.; at sides of body, 0.3 mm.; 2, Lee-Metford: ogival tip; cupro-nickel mantle; thickness at tip, 0.8 mm.; gradual decrease at sides to 0.4 mm.; 3, Mauser: pointed dome tip; steel mantle plated with copper alloy; thickness at tip, 0.8 mm.; gradual decrease at sides to 0.4 mm.; 4, Krag-Jörgensen: ogival tip as in Lee-Metford; steel mantle plated with cupro-nickel; thickness at tip, 0.6 mm.; gradual decrease at sides to 0.4 mm. Note the more gradual thinning in the Lee-Metford (from Makins' "Surgical Experiences," etc.).

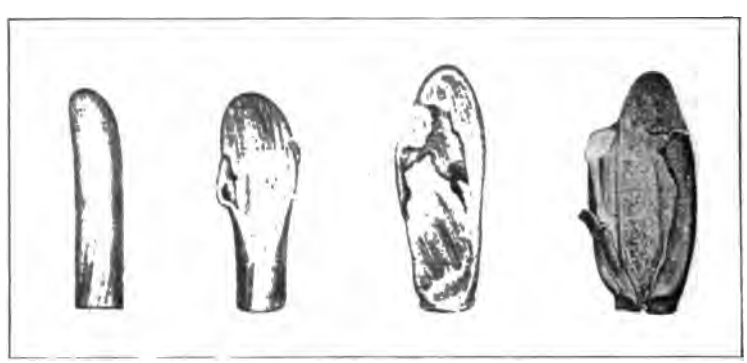

Fig. 591.—Four common types of lateral Mauser ricochet bullets (from Makins' "Surgical Experiences," etc.).

wounds are neat. Important parts are seemingly miraculously avoided by the bullet. The revolution of the bullet on its long axis facilitates a neat wound of entrance through the skin. The

Mauser bullet revolves on its own axis once in $8\frac{11}{16}$ inches, or about half of a full revolution in the perforation of a limb. The amount of destruction suffered by any part of a bone depends primarily upon the amount of resistance which it opposes to a bullet. There is more resistance offered by the cortex found in the shaft than by the spongy tissue of the ends of the long bones. When the hard shaft or cortical bone is hit, the force of the bullet is expended in breaking this dense and resistant bone into minute pieces.

The explosive effect of a bullet is dependent upon the velocity remaining to be expended upon the small particles of bone broken off by the initial impact. The carrying of these particles of bone

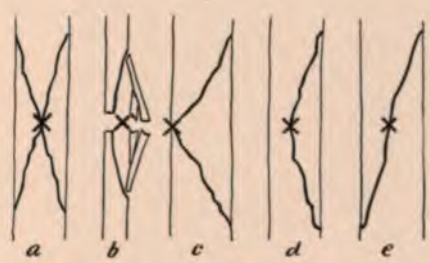

Fig. 592.—Five types of fracture: *a*, Primary lines of stellate fracture; *b*, development of the same lines by a bullet traveling at a low degree of velocity; the two left-hand limbs seen in (*a*) absent; in their places is seen a transverse line; *c*, typical complete wedge; *d*, incomplete wedge; *e*, oblique single line (from Makins' "Surgical Experiences," etc.).

forward into and through the tissues causes the laceration and tearing so characteristic of the so-called explosive effect of a bullet. The detached bony particles become really secondary missiles.

Kocher has classified the parts of the long bones injured as the diaphysis, the epiphysis, and the part between the two, the metaphysis. The cortical layer of the metaphysis is thin and the spongy tissue is in evidence. Uncomplicated injuries of these three parts of the bone are usually quite characteristic (see Figs. 594, 595, 602). The flat bones show a clean perforating wound similar to that seen in the short bones. The cancellous or spongy tissue of bone is ordinarily perforated completely and the wound of the bone is usually pretty clean-cut. Clean-cut perforations with-

out fracture are the rule in the neighborhood of the joints and epiphyses. Makins noticed in South Africa, among the wounds he studied, "the striking contrast of clean perforation and extreme comminution in different cases"; "the occasional occurrence of fracture of a very high degree of longitudinal obliquity"; "the rarity of any that could be termed transverse fractures"; "the general tendency of longitudinal fissuring, when it occurred, to

Fig. 593.—Diagrammatic view of a type of fracture of the femur, the bullet entering on the anterior surface of the bone causing extensive longitudinal fissuring of the shaft. The articular ends of the same have not been involved in the fracture (after Kocher).

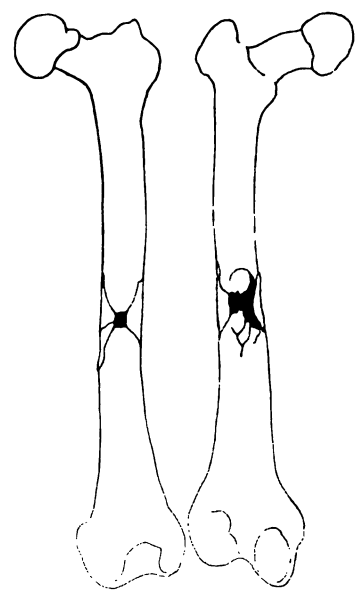

Fig. 594.—Diagram of a type of fracture. The entrance wound clean-cut, the exit wound lacerated and larger than the wound of entrance (after Kocher).

stop short of the articular extremities of the bones." If explosive effects are but slightly marked it is probably because the velocity remaining was insufficient to impart enough motion to the detached particles to convert them into secondary missiles. The greater the distance between the rifle and the bone struck, the lower will be the velocity of the bullet. Consequently the splinters of bone will be fewer, longer, and more adherent. On the con-

trary, the nearer the bone to the rifle, the splinters will be more numerous, shorter, unattached, and pulverized with bone sand.

A small skin wound may conceal a serious injury to the bone beneath. The flesh wounds of entrance inflicted by the modern rifle are mostly trivial. The missile with its great velocity, in face of slight resistance, will retain nearly all its energy, imparting little or none to the tissues. The exit wound may be small or large, depending upon the presence or absence of the explosive effect and

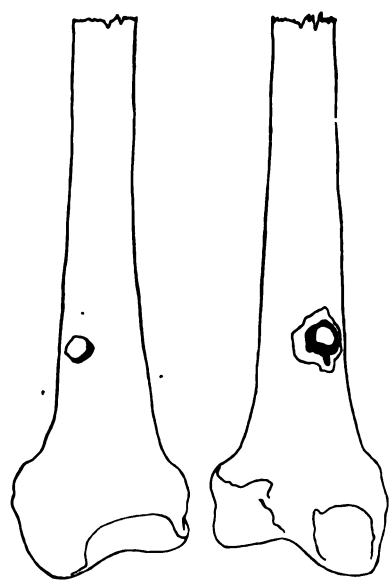

Fig. 595.—Diagram of a bullet wound of the metaphysis of the femur. The smaller entrance wound contrasts with the larger exit wound. The absence of fissuring is rather characteristic of bullet wounds in this region of the ends of the bones (after Kocher).

also upon the deflection of the bullet. Deflection of the bullet at the distance at which many wounds are received, as pointed out by Nancrede, occurs more commonly than is taught. Between the discharge of a bullet and its arrival at the mark many things may happen to it, resulting in a complicated wound of the soft parts and an extensive comminution of bone.

The turning of a bullet by impact with an obstacle in its course is spoken of as ricochet. The bullet which ricochets may enter the body not necessarily end on, but in any position and wobbling

about. Under these circumstances the wound of entrance is greatly increased, and, the velocity being impaired, a lodged bullet often results. However, if great velocity remains, a ricocheting bullet may cause very great damage. A ricochet bullet is dangerous because its penetrative power is diminished, it is liable to be retained in the tissue, serious damage results to the bone if it is struck, and a badly lacerated wound may result in the soft parts.

These facts are perhaps of interest: The old flint-lock ball was $\frac{7}{10}$ inch in diameter. The Minie rifle (Crimean) ball was $\frac{6}{10}$

Fig. 596.—Gutter fracture of second degree, perforating the skull in the center of its course. The external table alone carried away at either end (from Makins' "Surgical Experiences," etc.).

inch in diameter. Martini Henry ball was $\frac{4}{10}$ inch in diameter. The modern small bore Lee-Metford is $\frac{3}{10}$ inch in diameter. The Mauser is slightly smaller than the latter. The latter two bullets have the new cupro-nickel case. The others were the old lead bullets. The Mauser bullet is 1.21 inches long, weighs 172.8 grains, is 0.275 inch in diameter, has a muzzle velocity of 238 feet per second, and makes 1 turn to the left every 9 inches. The English Lee-Metford is 1.25 inches long, weighs 215 grains, is 0.303 inch in diameter, and has a muzzle velocity of 2000 feet per second.

As La Garde has justly remarked, the employment of smokeless

powder, a flatter trajectory and greater penetration, and the change to the smaller jacketed projectiles will increase the number of the wounded in war, but the wounds, as a whole, will be less grave—more humane. Soldiers will be more often restored to the State useful members of the community, instead of cripples and pensioners. In point of economy the new projectiles confer a great advantage.

Treatment.—The principles underlying the treatment of closed fractures are to be followed in the case of gunshot fractures. But there are a few considerations worthy of note. Avoid exploration of a fresh gunshot fracture upon the field. Local

Fig. 597.—Diagrammatic transverse section of complete gutter fracture: *A*, External table destroyed, large fragment of internal table depressed (low velocity or dense bone); *B*, pulverization and comminution of both tables at the center of the track; *C*, depression of inner table (low velocity) (from Makins' "Surgical Experiences," etc.).

examination to determine the number, size, and position of fragments is unwise. The modern bullet is usually aseptic, smooth, and not heated. There is no urgency for its removal. It appears (Borden) that neither ricochet passage through other objects nor lowered velocity markedly increases the proneness of the jacketed missile to produce infection. The lodgment of a bullet does not necessitate the treatment of the wound as if it were an infected one. The dictum of von Nussbaum—"The fate of the wounded rests in the hands of the one who applies the first dressing"—applies nowhere with as much force as to the wounded in battle. The first field dressing is of the greatest importance.

Consideration of gunshot traumatism of the shaft of long bones, as shown by the Röntgen ray in connection with the ultimate outcome of the cases, points indubitably to the conclusion that infection or noninfection of the wound should influence treatment, rather than the amount or extent of bone damaged (Borden).

In noninfected wounds extensive comminution is not, as a rule, an indication for operative interference of any kind. Occlusive

Fig. 598.—Clean gutter fracture of the ilium (range about 300 yards). The gutter was clean-cut and admitted the forefinger. The inner and outer tables of the bone were in part blown out of a large, irregularly circular exit opening about 1½ inches above the crest of the ilium. The cancellous tissue was probably entirely blown out. Plates of the outer and inner tables still remained connected by their periosteum to that deep aspect of the iliacus and gluteus medius muscles. The peritoneal cavity was not opened. The patient did well. Compare with gutter fracture of the skull, seen in figure 596 (from Makins' "Surgical Experiences," etc.).

dressings and immobilization give assurance of the best possible results. Where there is considerable comminution shortening of the limb will probably occur as a result of the comminution and the displacement of the bone fragments. But excellent functional use of the limb may be restored, unless the lesion of the soft parts is extensive and motion is restricted by the formation of cicatricial connective tissue in the traumatic spaces (Borden).

Where infection exists removal of the cause under aseptic or antiseptic precautions is indicated. In such cases complete cleansing of the wound and removal of all loose bone fragments, followed by drainage and antiseptic dressings and irrigation, will usually suffice, and excision or amputation will only have to be resorted to in extreme cases (Borden). Amputation for extensive fracturing of the long bones is almost unknown (Nancrede).

As to the disinfection of the limb, primary cleansing, mainly by soap and water, of course should precede the exploration; and when the latter has been carried out, a second cleansing, preferably with corrosive sublimate, is imperative.

Fig. 599.—Superficial perforating fracture, illustrating lifting of the root at both entry and exit openings (from Makins' "Surgical Experiences," etc.).

Immobilization is a more difficult problem. Makins' remarks: A question of constant difficulty is that of frequency of dressing. In a stationary or base hospital this is not difficult. When the patient is, however, being moved from the field to the stationary hospital, and thence to the base, the movements during transport disturb the fixity of the dressing. No fractures of the thigh or leg, and few of the arm, can be transported for any distance without material disadvantage.

If possible, all fractures of the arm, thigh, or leg should be kept at a stationary hospital for a period of three or more weeks.

The necessity for primary amputation chiefly depends on the nature of the injury to the soft parts, less commonly on the extent

of the injury to the bones, and should be decided on exactly the same lines as in civil practice. So-called intermediate amputations are always to be avoided if possible. The results have been bad and the operation should only be undertaken in cases of severe sepsis where little can be hoped from it, or for secondary hemorrhage. When the operation could be tided over until the septic process had settled down and localized itself, secondary amputation gave very fair results. In either intermediate or secondary amputation for suppurating fractures it was necessary to bear in mind the special likelihood of an extensive osteomyelitis (Makins).

The very great mortality attending gunshot fracture of the femur previous to the introduction of the small-bore rifle makes it important to consider this fracture in some detail. I quote

Fig. 600.—Diagrammatic longitudinal section of fracture shown in figure 599 (from Makins' "Surgical Experiences," etc.).

Makins as having had the best recorded clinical experience in these cases.

First with regard to the primary signs and symptoms. A very considerable degree of general or constitutional shock usually accompanied them, and this was perhaps more constant than in the case of any other injury in the body. Local shock to the part was also a prominent feature. Abnormal mobility was very free in the badly comminuted cases. Crepitus was often loose, and of the "bag-of-bones" variety. The result of local shock and consequent flaccidity of the muscles was to reduce the development of primary shortening; in some cases of severe comminution this was practically *nil* during the first day or two, when, with return of tone in the muscles, it sometimes became very considerable.

The long and difficult transport is the most unsatisfactory element to contend with in the treatment of fractures of bone in the field. There are advantages in having a field hospital behind the firing line. Sir Wm. MacCormac has said that the ideal treatment

of a gunshot fracture of the femur would be to erect a tent over the man where he fell and not to transport him at all.

The plaster-of-Paris splint (roller bandage) spica to both thighs, with a long outside splint from axilla to below the foot, is the most satisfactory immobilization apparatus for these cases of compound thigh fracture.

The operative mortality following compound or open fractures of the femur during the Crimean war was about 73 per cent. During the American war it was about 53 per cent. During the Franco-German war it was 65 per cent. among the Germans and 90 per cent. among the French. The conservative mortality—*i. e.*, in the unoperated cases—was, under these same conditions: Crimean war, 72 per cent.; American war, 49 per cent.; Franco-German: German, 28 per cent.; French, 9 per cent. In the recent war with Spain in Cuba, although the results are not all tabulated, during 1898–99 the general mortality in operated and unoperated cases together was but 10 per cent. in this serious

Fig. 601.—Perforation of lower third of tibia, showing lifting and fissuring of the compact roof of the tunnel. Compare with figure 599, of a fracture of the cranial vaults (from Makins' "Surgical Experiences," etc.).

Fig. 602.—Oblique perforation, implicating both epiphysis and diaphysis. Large fragment detached at exit aperture. Caused by a bullet traveling at a low rate of velocity. The dotted lines indicate the course of the track (from Makins' "Surgical Experiences," etc.).

injury. Modern surgical methods used upon wounds of bone caused by modern military weapons will bring the mortality-rate very low indeed. All those interested in this department of surgery will await final statistics with hopeful expectation.

Prognosis in Fractures of the Femur.—From Makins' "Surgical Experiences": "As regards mortality, fractures in the upper third of the bone proved one of the most formidable injuries which came under treatment. Suppuration was common, at least 60 per cent. of the wounds becoming infected. This depended on several reasons, often inseparable from the injuries, or, from their treatment in field hospitals; such as (1) the exit wound being situated in the dangerous region of the thigh; (2) ineffective dressing and fixation; (3) the impossibility of insuring primary cleansing and removal of detached fragments of bone; (4) the necessity of the early transport of patients to the stationary or base hospitals, often for great distances; (5) the comparatively long period that often had to elapse before the opportunity of doing the first efficient dressing arrived. Fractures in the middle and lower thirds of the bone were more easy to treat successfully, but these also added to the list both of amputation and fatalities. Punctured fractures of the lower articular extremity were usually of little importance, as they progressed without exception, as far as my experience went, favorably."

CHAPTER XVIII

THE RÖNTGEN RAY AND ITS RELATION TO FRACTURES

BY E. A. CODMAN, M.D.

On January 23, 1896, Röntgen read his announcement of the discovery of the X-rays before the Physico-medical Society at Wurzburg. The extraordinary news fled over the world in an incredibly short time. Within a few months skiagraphs of the bones of the hands appeared in every newspaper that could afford an illustration, and the reporters indulged their imaginations and dwelt on the advantages the new discovery would bring to medicine and surgery. The strangeness of the subject offered an unusually brilliant field for the imaginative and humorous, and in consequence it will undoubtedly be years before the public is disabused of its first erroneous impressions. Perhaps more people err now on the side of incredulity than credulity, and are inclined to regard the wonders they heard of at first as "newspaper talk." Medical men are particularly subject to this criticism, and there are many who seem to feel a disappointment in the results. It is unfortunate that Röntgen's original article was not widely published in the first place, for it is a model of scientific accuracy, and contains not a single statement that has not been substantiated again and again. To those men who understood the limitations of the X-ray that this article pointed out, the results have not been disappointing. On the contrary, the improvements in apparatus and technic have enlarged the scope of its use and increased the importance of the information it gives us. The X-ray department has become a necessity in every large general hospital.

In discussing the value of Röntgen's discovery in a book on the treatment of fractures it has seemed wise to point out some of the mistakes that are commonly made in the interpretation of skiagraphs. To those who have done practical work with the X-rays

this chapter will be valueless; but those who have not may find in it some assistance in their effort to learn what real value the new science is to this branch of surgery.

Among other misconceptions the Crooke's tube was supposed to emit a very powerful light. It is not a powerful light, but merely a faint one of such quality that it is able to penetrate substances that ordinary light does not. It is its peculiar quality, not its intensity, that enables it to penetrate opaque objects. It is invisible to our eyes, but has the quality of causing chemical action on a photographic plate or of affecting crystals of certain substances so as to make them emit a faint light. A sort of sand-paper made of these crystals, finely ground, forms a fluorescent screen. A fluoroscope is made by inclosing such a screen in a light tight box with an eyepiece to allow the observer to see the crystal side of the sand-paper. When this instrument is brought near a Crooke's tube in action, the crystals become luminous and any substance that is not easily penetrated by these rays, when placed between the source of light and the screen, will cut off the rays and cast a shadow on the sand-paper that can be seen on the side away from the object. This shadow will be more or less deep, according to whether the substance cuts off more or less rays. Thus, iron casts a darker shadow than wood; bone, a darker shadow than flesh. In general the opacity of different substances varies directly with their atomic weights. In the same way the substance placed between the source of light and a photographic plate will cut off some of the rays from the plate. Where these are cut off, chemical action does not occur; where some of the rays go through, it occurs slightly; where the object does not interfere at all and the rays strike the plate directly, the action is greatest. When the plate is developed, we get a picture of the shadow of the object with its most dense parts most deeply shaded.

Many people confuse an X-ray picture with a photograph They take it to be a photograph by X-ray light. It is not a photograph, but a shadow-picture, a compound silhouette, a projection of the parts of an object. A photograph of the hand is made by the light reflected from the hand to the photographic plate, and shows the surface of the skin. A skiagraph of the hand is made by the light that has passed through the hand, and shows a chart of

the different densities of the different constituents of the hand, as bone, muscle, fat, and skin. As the other parts of the hand are of about equal density and this density is much less than that of bone, the bones appear prominently on the chart. The thickest portions and most dense portions of the bone appear more deeply marked than the lighter and spongy portions. As every little gradation of density is registered, the whole forms a picture.

As far as we know, the effects of the X-rays are only obtainable in the immediate neighborhood of their course; that is, a small point on the platinum reflector in the Crooke's tube. From this point they radiate in all directions, their power gradually diminishing until at a distance of about a hundred feet or a little more they are not appreciable by any means now at our command. Practically, they are only strong enough for skiagraphic purposes within a few feet of the tube.

Since they proceed from a point, and are not approximately parallel like the sun's rays, their shadows are necessarily distorted. We are all familiar with the distorted shadows thrown on the wall by a candle. The same distortion takes place in an X-ray picture in a lesser degree. Since the rays proceed from a point, all parts of an object can not stand in the same relation to that point and the surface of a plate at the same time. The least distortion will take place when the object is in contact with the plate, and as far from the light as is consistent with obtaining sufficient effect to take the picture: that is, to have the rays penetrate the less dense portions of the object. Let the distance from the point to the plate remain the same. It follows that:

(*a*) Shadows will be enlarged in proportion to the distance of the object from the plate, toward the light.

(*b*) Shadows are distorted of any object or part of an object not in a perpendicular line from the point of light to the surface of the plate, and that distortion takes place in a line drawn from the base of such perpendicular through that object or part of an object.

As an illustration of these distortions, we have represented in figure 603 the projection of a cubical block of wood (*a*). For convenience of drawing, the shadow (*b*) is represented at an angle. The outside square of *b* represents the upper surface of the block, while the inner square represents the lower. The density of the

shadow is greatest at the edges of the lower square, for they represent the longest paths of the rays through the block. From the consideration of figures 604, 605, 606, and 607 the reader will readily observe that any change in the tilt of the plane of the plate (Fig. 605, *a*) in the shape or density of the object, or in the distance of the point of light (Fig. 606), will produce a definite alteration of the shadow or picture. It is, therefore, necessary in looking at a skiagraph to know how the plane of the plate lay, how far distant

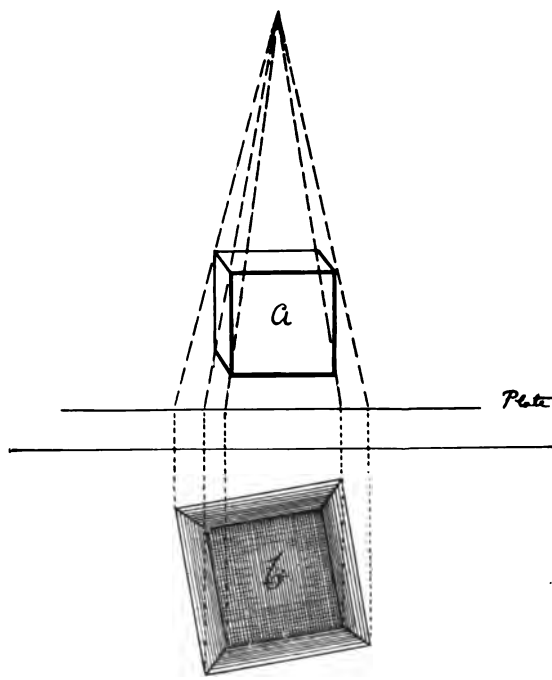

Fig. 603.

the light was, and, in general, what the shape and density of the different parts of the object were.

Just as it is true that the shadow of any object increases in size as it is moved from the plate toward the light, so also it is true that the density of the shadow decreases as its size increases. Each object that is translucent to the X-rays seems to have the ability to cut off a certain amount of X-ray light. In other words, it contains a certain amount of shadow-casting material. As it is

moved from the plate toward the light its shadow increases in size, but diminishes in density, since only a certain amount of light can be obstructed by that object.

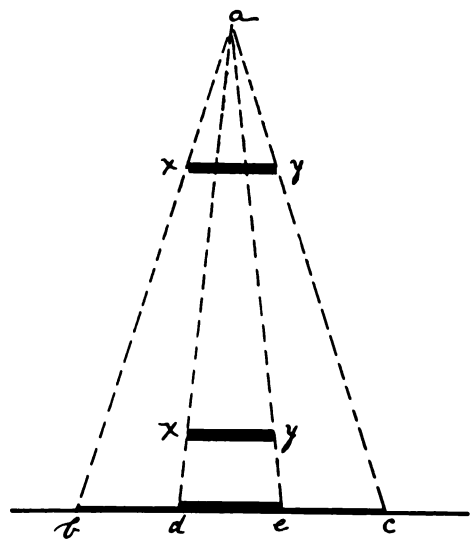

Fig. 604.

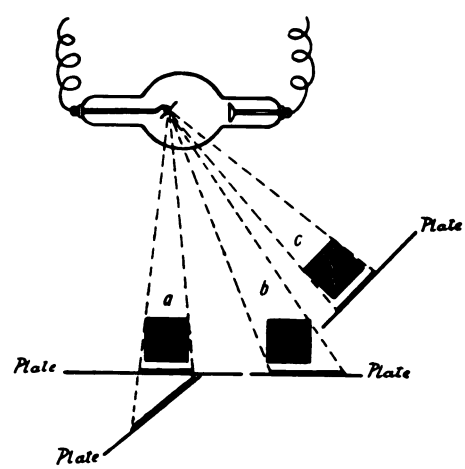

Fig. 605.

Putting it in another way, we see that the object *x y* (Fig. 604) in the angle *a b c* interferes with three times as much light as if in the position of *a d e*, but since it can only cut off a certain quantity

of rays in either position, the shadow in *d e* will be darker, though smaller than *b c*. Of course, if *x y* were not penetrated at all by the rays, the shadow would be at a maximum in both cases. In *a b c* there are three times as many rays to go through, but *x y* can only subtract a certain number. It can subtract that number from *a d e* where there will be a smaller remainder and hence a deeper shadow. This is an especially important point to keep in mind, for the range of variation of density of different bones is very small, and a very slight change in position in relation to the

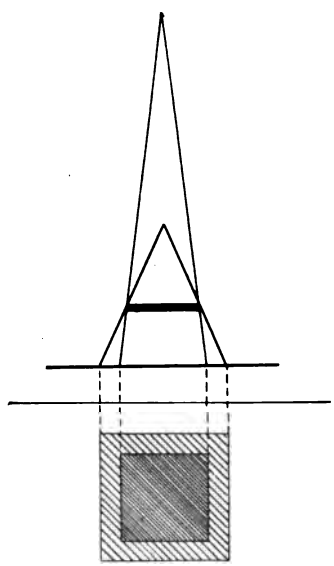

Fig. 606.

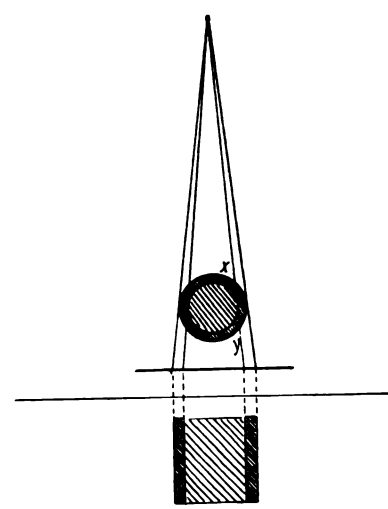

Fig. 607.

plate may make an enormous difference in the resulting picture. For example, figure 608, a skiagraph of the knee taken from behind,—*i. e.*, with the plate behind,—*C* shows little or no sign of the patella. While with the plate in front (*B*) and the tube behind, the outline of the patella is distinguishable through the shadow of the femur. This is the more decided if the tube is brought quite near to the back of the knee (*A*), for then the size of the shadow of the femur is increased and its density diminished, while that of the patella remains nearly the same in both size and density.

Another point that, though simple, seems to cause misunder-

standing is illustrated in figure 607, representing the shadow of a section of one of the cylindrical bones. It is intended to show why a long bone appears like a longitudinal section in a skiagraph. Though the whole circumference may be of the same thickness, the rays that pass through the sides, x–y, meet more resistance than those through the center; hence the medullary cavity appears on the plate.

It is often of great assistance to plot out on paper a projection of the salient points of the subject, as in figure 603, at the same time bearing in mind that variations occur in density as well as in size.

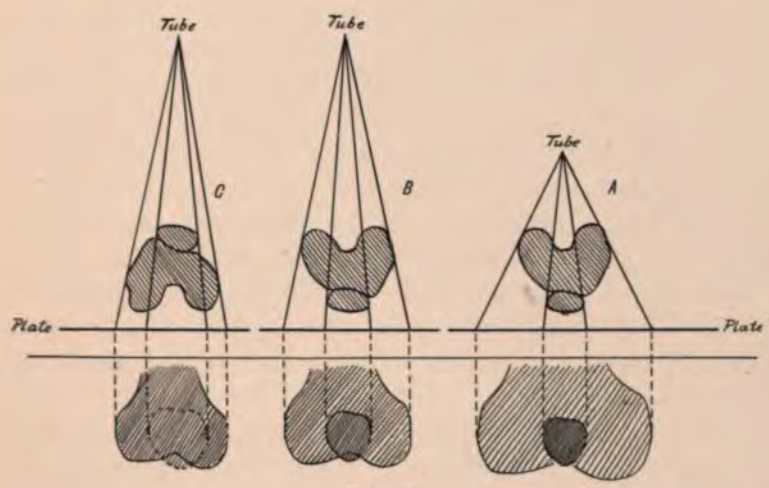

Fig. 608.

We should like to go into the question of the deceptiveness of skiagraphs at greater length, because we regard it as of the utmost importance that every physician who uses this means of diagnosis should fully understand the way in which any conclusion should be drawn from one of these pictures. *Though the pictures themselves are inaccurate as pictures of the object, they are accurate pictures of the shadows of the different parts of the object, and the reasoning of conclusions drawn from them should be exact.*

In answer to the question of what help the X-ray has been in increasing our knowledge of the pathology and treatment of fractures, we may mention first the general points and then the par-

ticular fractures in which we find it to be of benefit. Although surgeons have always realized very nearly accurately the position of the displaced fragments in the common fractures, there can be no doubt that the production of pictures of the exact condition in individual cases gives more reliable information of the condition and relation of the broken ends than can possibly be obtained by palpation. A more definite knowledge of the pathology brings greater exactness of treatment. When the splints are applied, it can be ascertained whether the position is good without removing the bandages. Little details that otherwise would escape notice are brought out. The patient is spared painful manipulation or etherization and the bruising and laceration of the tissues from unnecessary handling. The question of a cutting operation to reduce otherwise intractable fragments may be decided by an exact knowledge of the positions of the parts. This subject of the advisability of interference by making a simple fracture compound is one that is attracting more and more attention, and will lead to its being made the rule in cases where a good result can not be expected by the simple method. When asepsis can be practised, there is little danger of making an incision, and the time saved in cases where approximation of the fragments is prevented by loose bits of bone or soft parts is well worth this slight risk.

At present we find the X-rays of more assistance in the study of the pathology of fractures than we do in their treatment. For though we believe that in each individual case of fracture a skiagraph is of decided assistance, yet it must be confessed that the cases where it leads us to modify the treatment to any considerable extent are few in number. An exact diagnosis of fracture without skiagraphs is always open to doubt, while with a careful X-ray examination there is seldom a doubt. We appreciate the X-ray, too, when, after applying our splints, even if plaster, we assure ourselves of the correct alinement of the bones.

As a means of demonstrating to students the pathology of fractures, a series of lantern-slides of skiagraphs is of the greatest assistance. The knowledge that the pictures are of actual cases and not theoretic diagrams gives a practical interest that is akin to clinical instruction. The plates when shown at the same time

as the case at a hospital clinic also serve to illustrate the pathology and indications for treatment.

A not unimportant result of the use of Röntgen's discovery is the exactness it offers as a method of record in the rarer fractures. Heretofore statistics on the uncommon forms of fracture have always been open to the doubt of mistaken diagnoses, and we have been dependent on the chance of securing postmortem specimens in order to obtain accuracy. In future the recorded cases of this kind can be illustrated by skiagraphs, and we may look forward to not only greater accuracy, but to a much greater number of cases that were formerly considered rare. Every large hospital will be able to turn to its records and say definitely in what percentage any given fracture occurred. At the same time, each individual case has the benefit of a definite record, and the result can be compared with the extent of injury.

The reader will now ask in what forms of fracture can we say the X-ray is of great assistance. In general, those bones that can be brought near the plate or that are not overshadowed by other bones give the most satisfactory skiagraphs. Therefore, little can be expected of skiagraphs of the bones of the head or vertebræ, while those of the extremities come out with great precision. The pelvic and shoulder-bones stand midway between these, but with a good apparatus and care in the choice of the relative positions of the plate, tube, and the particular portion of the bone to be taken, we may expect a definite picture. Even in the case of the skull and vertebræ we occasionally find a skiagraph of advantage. The entire contour of the lower jaw can be easily investigated; the nasal, alveolar, and mastoid processes and malar bones come out sharply; the cervical vertebræ, both from behind and from the side, can be brought out with great detail, while the dorsal and lumbar, though not appearing clearly, sometimes show the rough outlines of bodies and articular, transverse, and spinous processes. Any particular portion of any particular rib, except the necks, can be taken with great accuracy; since the plate can be laid almost directly upon it. The clavicle, too, comes out clearly. The sternum is too much overshadowed by the dense dorsal vertebræ to show definite outlines.

Fractures in the shoulder-joint are often impossible to recognize

without the X-ray, particularly in those cases where the swelling and effusion about the joint prevent manipulation. Fractures of the tuberosities of the humerus, of the surgical and anatomical necks, can be differentiated with great certainty. When separation and dislocation of the epiphysis have occurred, we may decide the question of operation; and the same question may be answered in those puzzling cases in which fracture of the neck has occurred with dislocation. Separation of the tuberosities we now find is a much more common accident than we had supposed. Even in breaks of the shaft of the humerus and the other long bones we gain much information. The extent, direction, and plane of cleavage, with the exact amount of displacement, are guides for the application of padding and splints. It is in fractures of the long bones particularly that a second series of skiagraphs with the splints in position is of value. The amount of shortening is shown more accurately than by measuring the landmarks, for the overlapping can be distinctly seen. If necessary, the approximation of the fragments can be aided by proper pads.

It is not out of place here to refer again to the question of distortion, for in these cases one must remember that not only may the bones be magnified, but also the interspace between them. Two or more pictures must be taken, for a view from the side will often show a displacement that is not brought out in the shadow from in front or behind. The fluoroscope is particularly useful in this sort of work, for, while it does not give the detail that can be seen in a plate, it is clear enough to assure one of the alinement of the parts and avoids the trouble of taking and developing the plates. In general work, however, we place less reliance on the fluoroscope than on the skiagraph. As will be pointed out later, the use of the fluoroscope, also, is not without danger of dermatitis.

It is in injuries about the elbow-joint that we must be more than ever upon our guard to avoid false conclusions from the distortions that we have endeavored to point out. It will be most useful to any practitioner who intends to do X-ray work to take a series of skiagraphs of the normal elbow-joint from different positions and in different positions, and to study most carefully the projections of the parts in each. Such a series of injuries occur in this region that the diagnoses are most difficult, and the skiagraph correctly

interpreted is of the greatest help. Cases that formerly appeared in hospital records as "injury to elbow" are now divided into "fractures of head of radius," "neck of radius," "separation of coronoid process," etc. A feature which is now thoroughly brought out is the common occurrence of fracture with dislocation. Injuries to the elbow are particularly puzzling in children, since the ossification of the epiphyses is found in different stages, and the cartilaginous portions do not show in our plates. We may expect better results in this field when, by study and experience, we learn more of the time and mode of formation of the epiphyses.

In the wrist Röntgen's discovery has taught us much. We find in the fracture of the lower end of the radius a variety of types. Breaking of the styloid of the ulna is found to exist much more often than was supposed. The styloid of the ulna was fractured in 80 per cent. of 140 cases of Colles' fracture. Fracture of the scaphoid is also not uncommon both alone and in conjunction with Colles' fracture. Fractures of the semilunar and os magnum are also reported. The metacarpals and phalanges offer a less interesting field, but in the former, when impaction into the distal extremity has occurred and it is impossible to obtain crepitus or mobility, a skiagraph shows clearly the condition.

Improvements in apparatus and technique have enabled us to get, as a rule, clear pictures of the upper extremity of the femur when normal or recently broken. When diseased or surrounded by much inflammatory thickening or calcareous deposit, the outlines are blurred and unsatisfactory, but yet throw light on the diagnosis. There are often puzzling cases when fracture, dislocation, tuberculosis, and coxa vara all have to be considered, and in which a skiagraph is of the greatest assistance. Any portion of the shaft of the femur can be taken, and, since portable X-ray apparatus have come into use, the picture may be obtained without disturbing the patient or his dressings. Of the knee we get very clear plates. Of the method of taking the patella we have already spoken. We can compare the results of the traction treatment with those of suture and wiring. It is of assistance in determining whether the fragments are not too much shattered to admit of wiring.

In injuries of the lower leg we may apply what has already been

said of the other long bones, and in addition mention a case in which a fragment from the external malleolus lodged back of the astragalus under the tendo Achillis. In the foot, as in the wrist, the X-ray has taught us much. Numerous cases of breaks in the os calcis, astragalus, and scaphoid have been reported, and, though fractures of the other tarsal bones have not fallen within our experience, their occurrence might easily be recognized. Gocht points out that many swollen feet of uncertain diagnosis prove to be fractures of the metatarsals. He also reports fracture of one of the sesamoid bones of the great toe.

It is commonly said that the X-ray is dangerous to the patient and burns the skin and destroys the hair. This is true as a possibility, but nowadays is only to be feared in connection with gross ignorance and carelessness. It is a fact that Crooke's tube in action is capable of causing an effect on the tissues similar in many respects to a burn. But this action does not take place unless the tissues are exposed to the tube for a considerable period of time and at a very short distance: For instance, eight inches from the tube for an exposure of five minutes we should consider perfectly safe; one inch from the tube and five minutes, dangerous. Danger increases as we prolong the time of exposure or diminish the distance of the tube from the skin. Repeated exposures at short intervals are approximately equivalent in time to one exposure equal to the sum of all. Probably the skins of different people vary in susceptibility to this influence, but we doubt if injury ever occurred unless the tube was within a foot of the patient.

Danger to the hands of the operator of the apparatus is quite another matter, for repeated exposure may produce the same condition. The most severe cases occur when, in the use of the fluoroscope, the operator puts his hand near the tube, either to hold the patient's limb in place or to demonstrate the bones of his hand to an audience. Physicians who are called upon to use the fluoroscope often should wear rubber gloves to protect the hands, or cover the tube with a grounded aluminium screen. Most of the recorded cases of severe injury took place when the new light was first used, and experience had not pointed out these cautions. To-day, with our improved apparatus, the penetration and definition render a closer approach to the tube than twelve inches un-

necessary. The cause of these burns has been a subject of much discussion, and it may still be considered an open question. There are many who believe it to be due to an electrostatic effect, while others, among whom is Professor Elihu Thomson, affirm that the Röntgen rays themselves are responsible. Professor Thomson certainly should be an authority on this point, for he has not only the advantages of his electrical knowledge, but also of experimental experience. The following is a quotation from a personal letter from him in November, 1896, describing a somewhat heroic experiment.

"Hearing of the effects of the X-rays on the tissues, especially on the skin, I determined to find out what foundation the statements had by exposing a single finger to the rays. I used for this the little finger of the left hand, exposing it close up to the tube, about one and one-quarter inches from the platinum source of the rays, for one-half an hour. For about nine days very little effect was noticed; then the finger became hypersensitive to the touch, dark red, somewhat swollen, stiff; and soon after, the finger began to blister. The blister started at the maximum point of action of the rays, spread in all directions covering the area exposed, so that now the epidermis is nearly detached from the skin; underneath and between the two there is a formation of purulent matter that escapes through a crack in the blister. It will be three weeks today since the exposure was made, and the healing process seems to be as slow as the original coming on of the trouble."

Four days later: "The whole epidermis is off the back of the finger and off the sides of it also, while the tissue even under the nail is whitened and probably dead, ready to be cast off. The back of the finger for a considerable extent, where it received the strongest radiation, is raw and will not recover its epidermis, apparently, except from the sides of the wound."

Not entirely satisfied with this experiment, Professor Thomson shortly afterward repeated it on another finger, which he covered with some aluminium foil in such a way as to convince him that the tissue, while still exposed to the X-ray, was shielded from the brush discharge. As he obtained the same result, he concluded in favor of the Röntgen ray itself. In a recent article on the subject he shows that this effect is due to those of the rays that are less

readily transmitted by the tissues and are less valuable for skiagraphic purposes.

This quotation is made not only from its value as an experiment, but also because it is so clear a description of this form of dermatitis. The long period before the effects become evident is quite characteristic, although in many cases they have appeared sooner. It seems probable that the direct effect is on the vasomotor or trophic nerve supply, which eventually affects the nutrition of the part.

This chapter has been mainly devoted to warnings of the dangers of the Röntgen ray, and may in a measure discourage practitioners from its use. It should be stated, however, that when the limits of error are kept clearly in mind, the actual value of the discovery to surgical science is very great. When there is doubt of the diagnosis of a fracture, no physician has done his full duty by his patient if he can command skiagraphic examination and has not used it. This is particularly true in medicolegal cases where there is a question of liability.

CONCLUSIONS EXPRESSING THE VIEWS OF THE AMERICAN SURGICAL ASSOCIATION UPON THE MEDICOLEGAL RELATIONS OF X-RAYS; ADOPTED IN MAY, 1900.

1. The routine employment of the X-ray in cases of fracture is not at present (1900) of sufficient definite advantage to justify the teaching that it should be used in every case. If the surgeon is in doubt as to his diagnosis, he should make use of this as of every other available means to add to his knowledge of the case, but even then he should not forget the grave possibilities of misinterpretation. There is evidence that in competent hands plates may be made that will fail to reveal the presence of existing fractures or will appear to show a fracture that does not exist.

2. In the regions of the base of the skull, the spine, the pelvis, and the hips, the X-ray results have not as yet been thoroughly satisfactory, although good skiagraphs have been made of lesions in the last three localities. On account of the rarity of such skiagraphs of these parts, special caution should be observed, when they are

affected, in basing upon X-ray testimony any important diagnosis or line of treatment.

3. As to questions of deformity, skiagraphs alone, without expert surgical interpretation, are generally useless and frequently misleading. The appearance of deformity may be produced in any normal bone, and existing deformity may be grossly exaggerated.

4. It is not possible to distinguish after recent fractures between cases in which perfectly satisfactory callus has formed and cases which will go on to nonunion. Neither can fibrous union be distinguished from union by callus in which lime-salts have not yet been deposited. There is abundant evidence to show that the use of the X-ray in these cases should be regarded as merely the adjunct to other surgical methods, and that its testimony is especially fallible.

5. The evidence as to X-ray burns seems to show that in the majority of cases they are easily and certainly preventable. The essential cause is still a matter of dispute. It seems not unlikely, when the strange susceptibilities due to idiosyncrasy are remembered, that in a small number of cases it may make a given individual especially liable to this form of injury.

6. In the recognition of foreign bodies the skiagraph is of the very greatest value; in their localization it has occasionally failed. The mistakes recorded in the former case should easily have been avoided; in the latter, they are becoming less and less frequent, and by the employment of accurate mathematical methods can probably in time be eliminated. In the mean while, however, the surgeon who bases an important operation on the localization of a foreign body buried in the tissues should remember the possibility of error that still exists.

7. It has not seemed worth while to attempt a review of the situation from the strictly legal standpoint. It would vary in different States and with different judges to interpret the law. The evidence shows, however, that in many places and under many differing circumstances the skiagraph will undoubtedly be a factor in medicolegal cases.

8. The technicalities of its production, the manipulation of the apparatus, etc., are already in the hands of specialists, and with that subject also it has not seemed worth while to deal. But it is

earnestly recommended that the surgeon should so familiarize himself with the appearance of skiagraphs, with their distortions, with the relative values of their shadows and outlines, as to be himself the judge of their teachings, and not to depend upon the interpretation of others, who may lack the wide experience with surgical injury and disease necessary for the correct reading of these pictures.

CHAPTER XIX

THE EMPLOYMENT OF PLASTER-OF-PARIS

MANY fractures of the upper and lower extremities may, at some period, very properly be treated by the plaster-of-Paris splint.

The plaster-of-Paris should be of the best quality and dry. Crinoline is used for bandages. Commercially it is called Arrowwanna Crinoline Lining. It is a lining material that is coarser meshed than the cheese-cloth used for gauze bandages, and is also stiffer than cheese-cloth. It should be cut into four-yard lengths, folded, and stitched together. Crinoline contains considerable sizing or glue. This is detrimental to its use as a plaster bandage. It should, therefore, be washed of the sizing in lukewarm water, thoroughly rinsed, and rough dried. The stitching holds the material firmly together during the washing. It should then be cut into strips the widths of the desired bandages. Three widths are ordinarily useful—namely, widths of two inches, three inches, and five and one-half inches. These four-yard strips are made into roller bandages. A fine-meshed gauze bandage is being used quite commonly in place of crinoline.

Rolling the Plaster.—It is a simple matter to make one's own plaster roller bandages. It is possible to purchase plaster bandages in sealed packages. These are ordinarily made with unwashed crinoline and are less desirable. A shallow box or tray is needed to hold the plaster. Two persons can roll the bandage with facility. "A" manages the roll of crinoline, straightens it as it unwinds, spreads the plaster with a light piece of board, the size of the hand, while "B" draws the crinoline across the tray from under the board held by "A," and rolls up the bandage loosely and evenly. "A" with the board held still and plaster heaped upon the bandage behind it, regulates, by more or less pressure upon the bandage, the amount of plaster distributed over the crinoline. It requires but ten or fifteen minutes to make enough

Fig. 609.—Shoulder-cap of plaster-of-Paris, used in injuries to the shoulder-joint and upper end of humerus. Note shape of crinoline, which has been filled with plaster cream. First step in application. The shoulder may be covered with a protective layer of sheet wadding.

Fig. 610.—Shoulder-cap of plaster-of-Paris. Application to shoulder and front of chest. Second step in application. Note that shoulder and upper arm are well covered.

Fig. 611.—Shoulder-cap of plaster-of-Paris. Application completed. Anterior view.

Fig. 612.—Shoulder-cap of plaster-of-Paris. Application completed. Posterior view.

Fig. 613.—Shoulder-cap of plaster-of-Paris. Application of retentive roller bandage of cheese-cloth. Anterior view. A sling should complete the dressing.

bandages for a plaster splint for the leg or thigh. An advantage in making one's own bandages is that they are made of the desired width and have the proper amount of plaster. They are fresh and more likely, therefore, to set readily upon being wet. If many bandages are made at a time, they may be kept in a tin cracker box. If the closed box is put in a dry place, these band-

Fig. 614.—Fracture of the elbow or orearm. Application of sheet wadding for protection. Method of holding the arm at a right angle.

ages will keep indefinitely. Should the plaster become damp, the bandages should be placed in a warm oven until dry. It is important in making the plaster rollers to put just enough plaster into the bandage and to distribute the plaster evenly through the meshes of the crinoline. The proper amount of plaster to put into a bandage can only be learned by experience in making and using the bandages. It is a common error to spread the plaster too

thickly. The water in which the bandages are dipped should be lukewarm and of sufficient depth to cover the bandages when set up on end. The water working its way into the meshes of the bandages displaces the air in the bandage, which is indicated by the bubbles rising to the surface of the water. As soon as the bubbles have stopped rising the plaster is thoroughly wet throughout the bandage. Table salt, two teaspoonfuls to four quarts of water,

Fig. 615.—Fracture of the elbow or forearm. Application of plaster-of-Paris bandage. Method of holding the arm.

hastens the setting of the plaster. Its use, however, is to be deprecated, because the plaster has to be applied too quickly for the best results in plaster work, and the brittleness of the plaster resulting from the use of salt is undesirable. The plaster bandage should be lifted from the water carefully with both hands holding the two ends so as to retain as much plaster as possible within the roll. The bandage should then be wrung free from water while

Fig. 616.—Fracture of the elbow or forearm. Plaster-of-Paris splint being applied. Elbow at a right angle.

Fig. 617.—Anterior and posterior splints being applied after having become firm upon the forearm. For fracture of forearm bones.

Fig. 618.—Anterior and posterior splints in position. To be held in place by adhesive-plaster strips and a bandage. A light, durable, cheap, efficient splint.

Fig. 619.—A posterior splint for elbow, forearm, and upper arm. It is most comfortable.

Fig. 620.—Posterior elbow splint in position.

Fig. 621.—Posterior and anterior splints for elbow. Anterior splint being applied.

Fig. 622.—Anterior and posterior splints for the elbow. Note the additional plaster wedge being put in place to strengthen the anterior splint at the bend of the elbow.

Fig. 623.—Anterior and posterior plaster splints applied. Most comfortable and efficient in injuries high up the orearm and at the elbow and lower part of upper arm.

Fig. 624.—Lateral or side splint of plaster-of-Paris for the foot, ankle, and lower leg. Note shape of crinoline. The plaster cream is being poured from pitcher and evenly rubbed into the layers of crinoline.

Fig. 625.—Lateral or side splint of plaster-of-Paris ready for application to leg, ankle, and foot. Plaster cream has been thoroughly rubbed into the meshes of the crinoline.

Fig. 626.—Lateral or side splint of plaster-of-Paris applied to the inner side of leg, ankle, and foot. Held in position ready for bandage. Note the perforated tin strip at the ankle for greater strength. Foot at right angle with leg.

Fig. 627.—Lateral or side splint of plaster-of-Paris. Retentive bandage being applied. Tin reinforcing strip seen at the ankle.

Fig. 628.—Plaster gutter to posterior surface of leg and foot, held in place by a few turns of a cheese-cloth bandage. This plaster posterior splint is made much as is the lateral plaster splint for the leg and foot.

Fig. 629.—Anterior and posterior plaster splints for injuries to the leg below the knee and about the ankle and foot. Anterior splint being applied.

Fig. 630.—Anterior and posterior leg splints applied. Note application of the half cuff of plaster to reinforce the ankle.

Fig. 631.—Fracture of the patella. The leg covered with sheet wadding. The application of the plaster-of-Paris roller.

Fig. 632.—Fracture of the patella. Application of the plaster-of-Paris roller. Bandage being finished.

Fig. 633.—Fracture of the leg. Plaster-of-Paris splint applied from the toes to the groin. Foot at a right angle with the leg. Toes padded to prevent chafing.

Fig. 634.—Fracture of the leg. Plaster cast of leg from toes to below the knee removed.

Fig. 635.—Fracture of the leg. Removable plaster cast of leg. Same as figure 634. Anterior view, showing cut in plaster.

Fig. 636.—Open fracture of the leg. Plaster-of-Paris splint. Window cut in plaster, through which wound is dressed. Window surrounded by oiled silk.

Fig. 637.—Open fracture of the ankle. Window in plaster-of-Paris splint, through which wound is dressed. Gauze seen in the window. Oiled silk about the window.

the hands still grasp its ends. The bandage should be wrung until it does not drip. In the application of the plaster splint to fractures of any part of the body it is important that all deformity should be corrected and that the part should be thoroughly immobilized. This necessitates the presence of one or two assistants.

In applying a plaster splint with the roller bandage the surgeon

Fig. 638.—Ham splint of plaster-of-Paris. The splint is slightly thicker at the ham underneath the region touched by the thumb in the plate. It is thus strengthened. More comfortable than ordinary wooden ham splint.

should do his work so carefully that he scatters no plaster anywhere but upon the splint and in the pail of water. The surgeon should work neatly. The patient should be protected by a sheet. The floor should be protected by a sheet spread under the patient and under the chair of the surgeon. The surgeon should remove his coat, roll up his sleeves, and be protected from unexpected spattering of plaster by an apron or sheet over his body.

One thickness of sheet wadding torn into strips, from three to five inches wide, and rolled into roller bandages and then applied to the limb forms the best protection to the skin in applying the plaster splint. The sheet wadding is purchased at any of the dry-goods stores. It may be purchased by the quarter bale or by the single sheet. The plaster bandage should be applied to the protected part slowly, deliberately, and accurately. The bandage should be applied smoothly, and should have no wrinkles or thick awkward places anywhere. It is well to rub the bandage as fast as

Fig. 639.—Fracture of the patella. Leather knee-cap with hooks for lacing. Made from plaster cast. Worn as a protection to knee after fracture.

it is laid upon the part with the palm of the hand slightly wet to distribute the plaster cream thoroughly and evenly. Over bony prominences the bandage should be very carefully molded. This will insure a good fit and less likelihood of slipping upon change of position. It is well to carry the first roll of plaster as far as it will go, one or two layers thick, completing the whole splint once, and then to go over it again from beginning to end. A sufficient number of layers should be applied to make a firm enough splint for the support of the part when the plaster has set. The splint should be as light as is compatible with strength. Light splints, if accu-

rately fitted, accomplish more good than heavy, ill-fitting ones. It is better to use too few rolls of plaster bandage rather than so many that a heavy and cumbersome splint is made. Immediately after the plaster has set, if it is found to be too weak at any spot, an additional bandage may be used to reinforce at that point. The part bandaged should be held in perfect position until the plaster has set firmly enough to support it. This will ordinarily occur in about ten or fifteen minutes. The weight of the splint may be materially reduced by using tin strips incorporated in the layers of

Fig. 640.—Fracture of the leg. Removable dextrin splint with hooks and lacing.

Fig. 641.—Fracture of the leg. Same as figure 640. Anterior view.

the plaster bandage. These strips should be perforated by holes so as to offer rough places to catch in the plaster bandage. The two ends of the splint should be so finished that pressure and consequent deformity can not occur—for instance, the plaster of the forearm should stop just short of the bend of the elbow. The plaster of the thigh should be so far below the perineum and groin as to permit of flexion of the thigh upon the trunk without excoriating the skin of the groin. The toes and fingers should be left uncovered to admit of inspection.

A certain degree of skill is demanded upon the part of the surgeon

for the proper application of the plaster-of-Paris splint. Plaster-of-Paris, when used for fractured bones, is applied either before or after the swelling has taken place: if applied before, it constricts the seat of fracture, prevents swelling, and may cause great pain; if applied after the swelling has taken place, it becomes loose as soon as the swelling of the soft parts subsides, and motion of the limb in the splint and of the fragments of the fractured bone one upon the other is possible. It is important, therefore, to split the plaster soon after it has been applied, and thus obviate these dangers of too light and too loose a splint. The tightness of the splint should be regulated by straps and a bandage of cheese-cloth.

The Removal of the Plaster Splint.—The removal of the plaster splint is difficult. No instrument has been devised that is more efficient than an ordinary sharp jack-knife. If the plaster splint is split immediately after its application,—*i. e.*, as soon as it is hard,—it will be far easier than if it is cut after it is thoroughly dry. A strip of tin an inch wide laid upon the protected leg and covered by the plaster in its application will often be of great service upon removing the plaster. The tin will serve as a protection to the skin, and the cutting may be done more quickly and easily.

After removing most of the plaster from his hands the surgeon should wash his hands with a little water and granulated sugar or molasses. The sugar assists in removing all traces of plaster and leaves the skin soft and clean. Bandages of plaster-of-Paris are so readily obtained, so efficient, so safe from interference upon the part of the patient, and so easy to apply, that it is surprising they are not applied more often than they are.

The **dextrin bandage** is much slower in becoming firm than the plaster bandage, and yet is very light and serviceable. It is applied exactly as is the plaster-of-Paris bandage. The roller bandage of cotton cloth is first unrolled and rerolled in a basin containing a watery solution of powdered dextrin. Formula for making the solution of dextrin: Add about fourteen ounces of powdered dextrin to a pint of water, boil until dissolved, strain, and add one ounce of alcohol. The bandage is, therefore, thoroughly saturated with the dextrin solution. After covering the part bandaged once, dextrin is painted, with a small paint-brush, over the bandage. This is allowed to dry before a second and a third layer of the band-

age are applied. After each bandage a coating of dextrin is applied. After the final bandage several coatings of dextrin are applied, until a shiny, smooth surface results. This bandage may be cut, and, by the addition of strips of leather along the cut edge upon which are hooks, may be laced and unlaced as necessary (see Figs. 615, 616).

CHAPTER XX

THE AMBULATORY TREATMENT OF FRACTURES

By the ambulatory treatment of fractures of the lower extremity is understood a method of treatment that permits the immediate and continued use of the injured limb as a means of locomotion.

Medical literature contains many references to this method. It has been in use for some ten years. It has not met with general acceptance even among hospital surgeons. It is a radical method and open to criticism. It contains, however, several important suggestions. It will prove instructive to follow the adoption of this method by its advocates, and to discover, if possible, what there is in it of permanent value.

Orthopedic surgeons as early as 1878 conceived the idea of allowing a patient with a fracture of the thigh or of the leg to walk about by means of apparatus. Thomas, of Liverpool, and Dowbrowski used the Thomas knee-splint in the treatment of fractures certainly as early as the year 1881 or 1882. Krause, a German surgeon, published, in 1891, the first account of the treatment of fractures of the bones of the leg in walking patients. Krause demonstrated that plaster-of-Paris could be used as a splint in fractures of the leg and in transverse fractures of the thigh. Korsch, in 1894, presented a paper to the German Surgical Congress demonstrating that compound fractures of the leg and fractures of the thigh may be treated with plaster-of-Paris splints and early use. Korsch makes permanent extension in a thigh fracture, while traction is maintained by an assistant, by applying the plaster directly to the skin, snugly to the malleoli, the dorsum of the foot, and the heel. A padded ring is incorporated into the upper limit of the plaster splint around the thigh, which presses against the tuberosity of the ischium, and thus accomplishes counterextension. Korsch's cases were treated in Bardeleben's clinic.

Bruns, of Tübingen, in 1893, described a splint for use in these cases of fracture of the leg and thigh. Dollinger, of Budapest, in 1893, described a splint for the ambulatory treatment of fractures of both bones of the leg, and reported three cases. Dollinger's method of applying the plaster-of-Paris splint is the one generally used whenever the ambulatory treatment is employed. The method is described later.

Warbasse, at the Methodist Episcopal Hospital of Brooklyn, N. Y., in 1893, was the first in this country to adopt systematically Dollinger's method. Warbasse reports six cases—all in young adults. Bardeleben reported, in 1894, one hundred and sixteen cases treated with walking splints. There were eighty-nine fractures of the leg, complicated and uncomplicated; five fractures of the patella; twenty-two fractures of the thigh, five of which were compound; three cases of osteotomy for genu valgum. Bardeleben lays down the following law: "It is of the greatest advantage to the patient that such a dressing can be applied to the broken leg that he can bear the weight of the body upon it and walk about; but such a method of treatment should be applied only under medical supervision, and with the most careful consideration of complications that might arise." Korsch presented to the German Surgical Congress, in 1894, seven cases—three of the thigh and four of the leg. Albers, in 1894, reported seventy-eight cases (fifty-six of the leg, five of the patella, sixteen of the thigh, and one of the leg and thigh) treated by the ambulatory method. He seems to be a little more cautious than other German surgeons in this matter. He says that when great pain is present, it is best to employ injections of morphin.

Elevation of the limb will often reduce the swelling; when this does not suffice, the bandage must be removed. Severe local pain from pressure indicates the necessity for cutting a fenestrum. The first attempt at walking should be made on the day following the application of the cast. A crutch and cane are used at first; later, two canes are employed; and, finally, some patients walk without any support at all. Krause, in 1894, reported seventy-two cases treated. He is of the opinion that the ambulatory treatment in plaster splints must be limited principally to fractures and osteotomies in the region of the malleoli, the leg, and the lower end of

the thigh. He does not employ the method in the handling of oblique fracture of the femur and fractures of the neck of the femur. Bardeleben writes again in 1895, reporting up to that date one hundred and eighty-one cases treated by the ambulatory treatment. This last report, of course, included the one hundred and sixteen cases of the previous record. Dr. Edwin Martin, before the Surgical Section of the College of Physicians of Philadelphia, in December, 1895, reported twenty cases of fracture of the leg treated by this method. Dr. E. S. Pilcher, of Brooklyn, N. Y., in whose wards Marbasse worked, reported to the American Surgical Association the twenty or more cases treated by him in which the results were satisfactory. N. P. Dandridge, of Cincinnati, Ohio, has used the method in eight cases. In most of the cases pain was complained of when weight was borne on the foot. In a feeble woman it was necessary to remove the cast in the third week. In the case of a man,—a compound fracture of the leg,—after walking two weeks he had so much pain that the plaster was removed. Redness and swelling were great at the seat of fracture, and there was much swelling over the internal malleolus. Woodbury introduced the method at Roosevelt Hospital, New York city, and Fiske has reported cases treated at that clinic. Roberts, of Philadelphia, and Woolsey, of New York, have used the method in selected cases with satisfaction. A. T. Cabot, of Boston, has used, in several fractures of the femur, Taylor's long hip-splint. E. H. Bradford, of Boston, has treated cases of fracture at the Children's Hospital by a modified Thomas knee splint, with and without plaster-of-Paris splinting (Fig. 642).

Those advocating the ambulatory treatment suggest its application to fractures of the leg below the knee, both simple and compound, and in fractures of the lower end of the femur. The apparatus is not to be applied for three or four days if there is much primary swelling.

The method of application of the plaster splint in the ambulatory treatment of fractures of the tibia and fibula alone is as follows (this is practically the method of Dollinger): First comes the cleansing of the skin of the leg with soap and water and then the reduction of the fracture. Then, with the foot fixed at a right angle to the leg, a flannel bandage is smoothly and evenly applied

from the toes to just above the knee. This bandage is made to include beneath the sole of the foot a padding of ten or fifteen layers of cotton wadding, making a pad about three-fourths of an inch thick, after it is compressed by the moderate pressure of the flannel bandage. Over this is now applied the plaster bandage from the base of the toes to just above the knee, especial care being

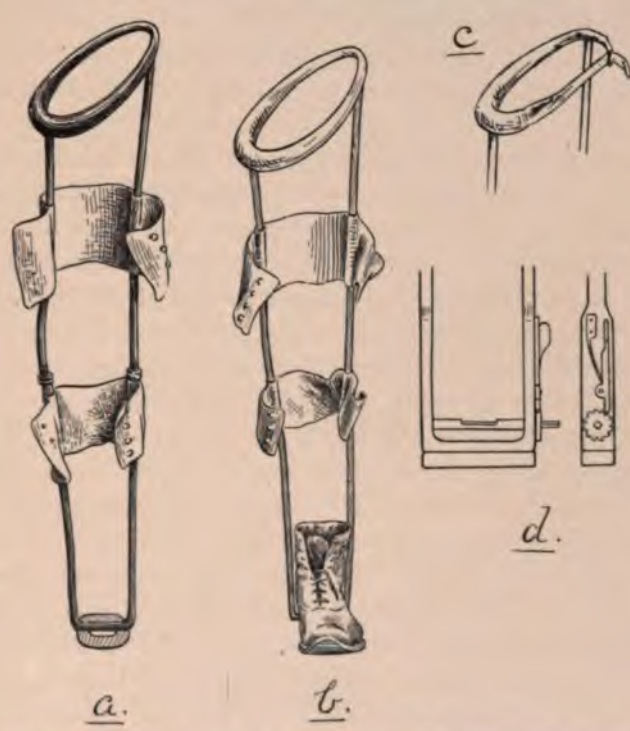

Fig. 642.—Thomas knee splint or ambulatory treatment of leg fractures, used with a light plaster-of-Paris leg splint: *a*, ordinary form; *b*, "caliper" or convalescent splint so fitted as to keep the heel of the foot away from the boot while the toes are used; *c*, the half-ring sometimes used at the upper end; *d*, lower end of splint, as arranged for windlass traction.

taken that the application is made smoothly and somewhat more firmly than is the custom in the ordinary plaster cast. The layers of the bandage should be well rubbed as they are applied, with a view to obtaining the greatest amount of firmness with the smallest amount of material. The sole is strengthened by incorporating with the circular turns an extra thickness composed of ten or

twelve layers of bandage well rubbed together, and extending longitudinally along the sole. The bandage is applied especially firmly about the enlarged upper end of the tibia, and here it is made somewhat thicker. As it dries it may be pressed in so as to conform more closely to the leg just below the heads of the tibia and fibula. The assistant who stands at the foot of the table and supports the leg makes such traction or pressure as is required to keep the fragments in proper position while the plaster is being applied. The operation requires about twenty minutes, and by the time the last bandage is applied the cast should be fairly hard.

It is seen that when this cast has become hardened the leg is suspended. When the patient steps upon the sole of the plaster cast, the thickness of the cotton beneath the foot separates the sole of the foot so far from the sole of the cast that the foot hangs suspended in its plaster shoe. Thus the weight of the body, which would come upon the foot, is borne by the diverging surface of the leg above the ankle. The chief of these is the strong head of the tibia. A lesser rôle is played by the head of the fibula and the tapering calf in muscular subjects.

In thigh fractures the use of the long Taylor hip-splint, together with a high sole upon the well foot and crutches, is generally accepted as the best method of ambulatory treatment.

The advantages claimed for the ambulatory method are:

Time is saved to the business man by this method—he having to give up but about seven days to a fracture of the leg. The time spent by the patient in the hospital is less than by other methods. The general health is conserved; whereas by the old method the appetite is variable, sleep is troubled, the bowels are constipated, and general discomfort prevails. There is greater general comfort by this method than by any other. In drunkards and those with a tendency to delirium tremens this liability is greatly diminished. In old people the danger of a hypostatic pneumonia is lessened. The primary swelling associated with a fracture is often avoided, and always less than by the older methods. The secondary edema and muscular weakness are less. The functional usefulness of the whole leg is greater. There is less atrophy of the muscles of the thigh and leg. The amount of the callus is diminished. There is

less stiffness of neighboring joints. Union in a fracture occurs at an earlier date.

Before this method can be adopted generally and in hospital treatment it must be demonstrated that it is safe, and that it offers chances of better functional results than are obtained under present methods, and that the minor advantages claimed for it by ardent German advocates are real and not imaginary. The first great advantage of the method is stated to be that the stay in the hospital and the time away from one's occupation are much lessened. Regarding this point the Massachusetts General Hospital Surgical Records were consulted for these three periods: before the use of plaster-of-Paris—that is, previous to 1865; just at the beginning of the use of plaster-of-Paris as a splint for fracture, and in 1895, 1896, and 1897. Thirty-five unselected cases of fracture of the tibia and fibula were tabulated from each period. The duration of the average time spent in the hospital in the first period—*i. e.*, previous to 1865—was forty-six days; in the second period—*i. e.*, about 1866—it was forty-five days; at the present time it is sixteen days. In the second period plasters were applied to fractured legs on an average at about the twenty-eighth day; at the present time, on the fourteenth day. In other words, there has been since the introduction of the plaster splints a gradually shorter detention in the hospital, as surgeons have come to recognize the safety of an earlier application of a fixed dressing. On an average, patients with fracture of the leg are detained in the hospital to-day but sixteen days. The very great saving to the hospital in time by the ambulatory treatment does not, therefore, appear. It is impossible to consider the statements made with regard to rapidity of healing, sign of callus, absence of muscular atrophy, and absence of rigidity of joints, because there are no facts available for the purpose. The advantages stated are based, most of them, upon the personal impressions of the surgeon in charge; impressions compared with scientific observations are untrustworthy.

Krause presents a table from Paul Bruns containing the average periods of healing in a series of fractures, and compares these periods with his own fracture cases treated by the ambulatory method. This is the only attempted scientific statement of obser-

vation on this important point. Krause concludes from a study of these tables that, "In the treatment of fractures of the middle and upper thirds of the leg, the ambulatory method shows a great advantage in the period of consolidation as well as in the time when the patient can return to work. It seems that the higher up the fracture is in the leg, the sooner a cure is effected by the ambulatory method of treatment."

Conclusions.—A review of the literature does not disclose any other advantage in the results of the ambulatory treatment over the present treatment of fractures of the leg than that stated by Krause. The present commonly accepted method of treating fractures of the femur by long rest in the horizontal position, with extension by weight and pulley, is not satisfactory. The protracted stay in bed is undesirable. The use of the Taylor hip-splint in the treatment of this fracture, assisted by coaptation splints or a splint of plaster-of-Paris, is of distinct value. This, however, is a somewhat well-known method of ambulatory treatment.

Theoretically and practically, the ambulatory treatment does not perfectly immobilize; therefore, it can not preeminently succeed as a means of treatment. The method in general seems to be unsurgical. Embolism, both of fat and of blood, and the likelihood of pressure-sores in the use of the plaster splint are dangers to be considered. It is wise to allow the injured limb to rest while the reparative process is beginning. Muscular relaxation is desirable in the treatment of fractures. The very admission by the advocates of the ambulatory treatment that muscular contractions take place is reason enough for supposing that complete immobilization is not obtained by this method. However, in certain carefully selected cases of fracture below the knee, particularly of the fibula, if under the care of a competent and skilful surgeon, it is possible to conceive of the ambulatory method being used without doing harm.

A consideration of the ambulatory treatment of fractures should lead to a more careful and early use of the plaster-of-Paris splint in fractures of the leg, and to a proper application of the long hip-splint or its equivalent in fractures of the thigh, and to the early use of crutches and the high sole on the well foot in both of these lesions.

MATERIALS FOR THE ORDINARY CARE OF CLOSED FRACTURES

The materials with which a physician should be provided in order to properly care for the fractures ordinarily met with are comparatively few.

There is scarcely a fracture which can not be treated satisfactorily by the proper use of plaster-of-Paris.

Plaster-of-Paris roller bandages.

Washed crinoline or the common cheese-cloth gauze roller bandage.

Plaster-of-Paris.

A jack-knife for splitting plaster dressings.

A pair of heavy scissors.

Thin splint wood, $\frac{3}{16}$ of an inch in thickness.

Iron wire, $\frac{1}{4}$ of an inch in diameter.

Posterior wire splint, for adult leg.

Anterior wire splint, for adult leg.

Surgeon's adhesive plaster.

Cotton and cheese-cloth roller bandages.

Sheet wadding for padding splints.

BIBLIOGRAPHY

The important contributions to literature which have been consulted are recorded below. Dr. Stimson's book upon "Fractures" will always stand as a classical work in its especial field. Dr. Poland's work upon "The Epiphyses" is also a very valuable contribution to fracture literature. The text has been kept free of all references in order that greater clearness might result.

Hamilton, Fractures and Dislocations.

Stimson, A Practical Treatise on Fractures and Dislocations, Lea Bros., 1899.

Helferich, Atlas of Traumatic Fractures and Luxations, with a Brief Treatise, Wm. Wood & Co., 1896.

Roberts, P. Blakiston, Son & Co., Philadelphia, 1897.

Wharton and Curtis, The Practice of Surgery.

The International Encyclopedia of Surgery; supplementary volume VII, 1895.

Dennis, F. S., System of Surgery, 1895.

Cheever, Lectures on Surgery, Damrell and Upham, Boston, 1894.

FRACTURE OF THE SKULL

Huguenin, Cyclopædia practische Medicin, Ziemssen, Band XII, 1897.

Mills, The Nervous System and Its Diseases, 1898.

Bradford and Smith, Transactions of the American Surgical Association, volume LX, page 433.

Bullard, Medical and Surgical Reports of the Boston City Hospital, 1897.

Dana, Text-book of Nervous Diseases.

Courtney, Boston Medical and Surgical Journal, April 6, 1899, page 345.

Hill and Bayliss, Journal of Physiology, London, 1895, XVIII, page 324.

Walton, American Journal of Medical Sciences, September, 1898.

Putnam, Walton, Scudder, Lund, American Journal of Medical Sciences, April 1895.

Phelps, Traumatic Injuries of the Brain.

FRACTURE OF THE NASAL BONES

Bosworth, Diseases of Nose and Throat, third edition, pages 157–161.

Zuckerkandl, Anat. norm. et Patholog. des Fosses Nasales, volume I, page 429.

Evans, Deflections of the Nasal Septum, Louisville Journal of Surgery and Medicine, volume V, June, 1898, pages 1–4.

Casselberry, Deformities of the Septum Narium, Transactions of the American Medical Association, volume XXII, No. 9, pages 469–471.

Cobb, Fracture of the Nasal Bones, Journal of the American Medical Association, volume XXX, 1898, page 588.

Freytag, Monatschrift für Ohrenheilkunde, 1896, Band XXX, Seiten 217–224.

Zuckerkandl, Anatomie der Nasenhöhle, Band II.
Watsin, Lancet, 1896, volume I, page 972.
Roe, The American Medical Quarterly, June, 1899.

FRACTURE OF THE SPINE

Thorburn, A Contribution to the Surgery of the Spinal Cord.
Walton, Boston Medical and Surgical Journal, December 7, 1893. The Journal of Nervous and Mental Diseases, January, 1902.
Thomas, Boston Medical and Surgical Journal, September 7, 1899, page 233.
Dennis, Annals of Surgery, March, 1895.
Burrell, Transactions of the Massachusetts Medical Society, 1887.
Taylor, Journal of the Boston Society of the Medical Sciences, December, 1898.
Wagner and Stolper, Die Verletzungen des Wirbelsäule und des Rückenmarks, 1898, Seite 415.
Kocher, Mittheilungen Grenzgebieten der Medicin und Chirurgie, 1896.
White, Transactions American Surgical Association, vol. IX.
Cheever, Boston Medical and Surgical Journal, September 28, 1893.
Pilcher, Annals of Surgery, volume XI, pages 187–200.
Prewitt, Transactions American Surgical Association, volume XVI, page 255.

FRACTURE OF THE SCAPULA

Blake, Boston City Hospital Reports, 1899, page 368.

FRACTURE OF THE HUMERUS

Bruns, Deutsche Chirurgie, Theil 28, 2. Hälfte.
Murray, New York Medical Journal, June 25, 1892.
Monks, Boston City Hospital Medical and Surgical Reports, 1895; also Boston Medical and Surgical Journal, March 21, 1895, January 9, 1896, and December 4, 1895.
Lund, Boston City Hospital Reports for 1897, page 389.
Allis, Annals of the Anatomical and Surgical Society, Brooklyn, 1880, II, 289.
Smith, Boston Medical and Surgical Journal, July, 1895.
Stimson, Roberts, Allis, Transactions of the American Surgical Association, 1881 to 1898.

FRACTURE OF THE FOREARM

Pilcher, Paper read to Association of Military Surgeons of the United States, Berlin Printing Co., Columbus, Ohio. Medical Record, 1878, II, 74. Annals of Anatomical and Surgical Association, Brooklyn, 1887, III, page 33.
Moore, Transactions of the Medical Society, State of New York, 1880.
Bolles, Boston City Hospital Reports, third series, 1882, page 340.
Conner, Journal of the American Medical Association, 1894, page 54.
Roberts, Medical News, 1890, LVII, 615. Annals of Surgery, 1892, XVI.
Mouchet, A., Revue de Chirurgie, May, 1900.

FRACTURE OF THE THIGH

Cabot, Boston Medical and Surgical Journal, January 3, 1884, page 6.
Allis, Transactions of the American Surgical Association, volume IX, 1891, page 329. Medical News, November 21, 1891.

Hutchinson, Lancet, 1898, II, 1630.
Packard, International Encyclopædia of Surgery.
Whitman, Annals of Surgery, June, 1897, page 1.
Senn, Journal of the American Medical Association, August 3, 1889.
Ridlon, Transactions of the American Orthopedic Association, 1887, page 186.
Lane, Medicochirurgical Transactions, London, 1888.
Scudder, Boston Medical and Surgical Journal, March 22, 29, 1900.

SEPARATION OF THE LOWER EPIPHYSIS OF THE FEMUR

Annals of Surgery, Philadelphia, 1898, XXVIII, 664.
Annals of Gynecology, November, 1890.
British Medical Journal, December, 1894, page 671.
New York Medical Record, October 5, 1895.
Annals of Surgery, March, 1896.
Archives Générales, March and April, 1884, volume XIII, page 272.
Transactions of the American Surgical Association, 1895.
Liverpool Medicochirurgical Journal, January, 1885, page 41.
Liverpool Medicochirurgical Journal, July, 1883.
Stimson, Fractures and Dislocations, 1899.
Hutchinson, Lancet, May 13, 1899.
McBurney, Annals of Surgery, March, 1896, XXII, 506.
Harte, Transactions of the American Surgical Association, 1895.
Deleus, Archives Générale de Medicine, 1884, volume XIII, page 272.
Poland, Traumatic Separation of the Epiphyses, 1898.
Smith, Transactions of the American Surgical Association, volume VIII.

FRACTURE OF THE PATELLA

Powers, Annals of Surgery, July, 1898.
Bull, New York Medical Record, XXXVII, 1890.
McBurney, Annals of Surgery, 1895, XXI, 312.
Pilcher, Annals of Surgery, 1890, XII.
Stimson, Annals of Surgery, 1895, XXI, 603; 1896, XXIV, 45.
Cabot, Boston Medical and Surgical Journal, CXXV.
Dennis, System of Surgery.
Lund, Boston Medical and Surgical Journal, 1896, CXXXV, 338.
Fowler, Annals of Surgery, January, 1891.
Macewen, Annals of Surgery, 1887, volume V, page 177.
Phelps, New York Medical Journal, June, 1890.
White, New York Medical Record, October 27, 1888.
Beach, New York Medical Record, March 15, 1890.

FRACTURE OF THE LEG

Cabot, The Boston Medical and Surgical Journal, January 3, 1894, page 6.
Lovett, Boston City Hospital Medical Reports, 1899, page 222.
Allis, Annals of Surgery, 1897.
Tiffany, Annals of Surgery, 1896, XXIII, 449.
Lane, Transactions of the Clinical Society, London, XXVII, 167.
Osgood, Robert, Transactions of the American Orthopedic Association, 1902.
Stimson, New York Medical Journal, June 25, 1892.

Smith, N. R., Treatment of Fractures of the Lower Extremity, Baltimore, Kelly and Piet, 1867.

GUNSHOT WOUNDS OF BONE

Makins, Geo. Henry, Surgical Experiences in South Africa, 1899–1900 (volume of 486 pages, published by Smith, Elder & Co., 1901).

Borden, W. C., The Use of the Röntgen Ray by the Medical Department of the United States Army in the War with Spain, 1898, Government Printing Office, 1900.

Kocher, T., Zur Lehre von den Schusswunden durch kleinkaliber Geschosse, Cassel, 1895, Th. G. Fisher & Co.

La Garde, Boston Medical and Surgical Journal, January 18, 1900, p. 57; October 25, 1900. Report of the Surgeon-General of United States Army, 1893.

Dennis, System of Surgery, volume I, p. 460.

Treves, F., London Lancet, 1900, I, 1359.

Dent, C., British Medical Journal, 1900, II, 632 and 634.

MacCormac, Sir Wm., London Lancet, 1900, I, 1485.

Thomson, Sir Wm., British Medical Journal, 1901, II, 265. London Lancet, II, 1901, 264.

Nancrede, Transactions of the American Surgical Association, 1899, 1900.

Hall, Edward J., London Lancet, 1901, I, 130, 1755.

THE AMBULATORY TREATMENT OF FRACTURES

Krause, Deutsche medicinische Wochenschrift, 1891, No. 13.

Korsch, Berliner klinische Wochenschrift, No. 2.

Bruns, Beiträge zur klinische Chirurgie, Band X, Heft II, 18.

Dollinger, Centralblatt für Chirurgie, 1893, No. 46.

Warbasse, Transactions of the Brooklyn Surgical Society, October, 1894.

Bardeleben, Verhandlungen der deutsche Gesellschaft für Chirurgie, XXIII. Kongress, 1894.

Albers, Verhandlungen der deutsche Gesellschaft für Chirurgie, XXIII. Kongress, 1894.

Krause, Verhandlungen der deutsche Gesellschaft für Chirurgie, XXIII. Kongress, 1894.

Pilcher, Transactions of the American Surgical Association, volume XIV, 1896.

Woodbury, New York Medical Record, 1897.

Roberts, Transactions of the American Surgical Association, volume XIV, 1896.

Woolsey, New York Medical Record, 1897.

Cabot, New York Medical Record, 1897.

Bradford, New York Medical Record, 1897.

THE EPIPHYSES

Quain, Dwight, Gray, Morris.

Poland, John, F.R.C.S., Traumatic Separation of the Epiphyses, 1898.

Brünne, Das Verhältniss die Gelenkkapselen zu die Epiphyse die Extremitäten-Knochen.

MASSAGE

Bennett, W. H., London Lancet, June 2, 1900; London Lancet, Feb. 5, 1898.

INDEX

ABSCESS of jaw, 61, 71
Acromial process of scapula, 121
  treatment, 123
Active motion after Colles' fracture, 242
  after fracture of femur, 302
    of leg, 378
  after separation of lower epiphysis of femur, 321
  in fracture of patella, 337
Ambulatory treatment:
  of fracture of shoulder, 143
    of thigh, 303
  of fractures, 462
    advantages claimed, 466
    conclusions, 468
    early advocates, 462
    materials for ordinary care of closed fractures, 469
    method of application of plaster splint, 464
    reports of cases, 463
American Surgical Association, conclusions expressing views of, upon medicolegal relations of X-rays; adopted in May, 1900, 438
Anesthetics, use of, in examination:
  of anatomical neck of humerus, 132
  of Colles' fracture, 226, 228
  of elbow, 162, 180, 191
  of hip, 263
  of leg, 353, 375
  of shoulder, 126, 130
Anesthetics, use of, in treatment:
  of Colles' fracture, 236
  of fracture of carpus, 247
    of forearm, 201
    of shaft of femur, 286
    of shaft of humerus, 154
    of surgical neck of humerus, 141
  of greenstick fracture of forearm, 214
  of open fracture of leg, 375
  of Pott's fracture, 387
Ankylosis of ankle-joint, 405
Arthritis after fracture of leg, 380
Asch tube, 49
Astragalus, 400
  open fracture, 404
    treatment, operative, 405
  treatment, 400
Atrophy, muscular, after fracture of humerus, 158

BANDAGE, dextrin, 460
    application, 460
    formula, 460
  elastic rubber, in fracture of patella, 330
  flannel, substituted for plaster splint, 379, 404
  plaster-of-Paris, 441
Bardeleben, quoted: law concerning ambulatory treatment of fractures, 463
Base-ball finger, 257
Base of skull, 26
    hemorrhage, 26
    symptoms, 26
Bed-sores, 270, 276, 366
  treatment, 270, 276
Bennett's fracture, 252
Bibliography, 471
Bladder (urinary), rupture of, 108
    symptoms, 108
    treatment, operative, 109
Blebs, treatment of, 359
Borden (W. C.), quoted:
  infection in gunshot wounds, 419
    treatment, 421
Bradford frame, 105, 312
    making of, 313
Brain in fractured skull, 17
    compression of, 18
    concussion and contusion of, 17
    laceration of, 18
      symptoms, 18
Bryant's method of measurement after fracture of neck of femur, 265
Buck's extension apparatus (modified), 288
    application of, 291
    materials required for, 288

Bullard, Dr. (Boston City Hospital), quoted: results of fracture of skull, 38

CABOT'S posterior wire splint, 310, 332, 364
application, 310, 367
covering, 365
making, 365
padding of, for reception of lower extremity, 366
Carpus, 246
symptoms, 246
treatment, 246
metacarpus, and phalanges, 246
Cauda equina, compression of, in fracture of spine, 77, 90
lesion of, 87
treatment, 87, 93
Clavicle, 110
anatomy, 110
operative treatment, 120
in ununited fractures, 120
prognosis, 119
symptoms, 111
in childhood, 112
treatment in adults, 113
modified Sayre dressing, 116
recumbent, 113
treatment in children, 117
Codman, Ernest Amory: Röntgen ray and its relation to fractures, 424
Colles' fracture, 223
anatomy, 223
differential diagnosis, 231
contusion of bones near wrist, 232
dislocation of wrist backward, 232
fracture of shaft of one or both bones low down, 233
separation of lower epiphysis of radius, 235
sprain of wrist, 231
lesions associated with, 236
operative treatment for resulting deformity, 245
prognosis and result, 244
"reversed," 244
symptoms, 226
treatment, 236
a method of reduction, 236
retentive apparatus, 239
application of, 240, 241
Coma, 30, 33
alcoholic, 30
from apoplexy, 30
from hemorrhagic internal pachymeningitis, 31
Coma from opium-poisoning, 30
in uremia, 30
Compression of brain, 18
symptoms, 18
Concussion and contusion of brain, 17
symptoms, 17
Condyle of humerus:
external, 173, 194
treatment, 182
internal, 172
treatment, 182
Contusion of bones near wrist, 232
Coracoid process of scapula, 129
Coronoid process of ulna, 198
symptoms, 201
Cystitis after fracture of spine, 81 92

DEFORMITY after Colles' fracture, 245
after fracture of clavicle, 119
of leg, 354
of metacarpal bones, 253, 257
of shaft of femur, 297
backward sagging of thigh, 298
eversion of foot, 297
outward bowing, 297
from separation of epiphysis of humerus, upper, 145
in Colles' fracture, 226
anteroposterior, 226
silver-fork deformity, 227
lateral, 227
slight deformity only, 228, 230
in fracture of both radius and ulna, 192, 210
of shaft of radius, 195
in fractures of vertebræ, 76
in greenstick fracture of bones of forearm, 192
in Pott's fracture, 385, 398
reversed Pott's deformity, 386
in separation of lower epiphysis of radius, 197
of nose from fracture, 44, 47, 51
from syphilis, 46
Dislocation of hip, 266
of humeral head, 131, 146
treatment, 146
operative, 147
of radius and ulna backward, with or without fracture of coronoid process of ulna, 169
treatment, 187
of wrist, backward, 232
Dollinger's method of application of plaster splint in ambulatory treatment of fractures, 464
Drainage in open fracture of leg, 377

Ecchymosis in fracture of leg, 355
Edema, causes of, after fracture of leg or thigh, 384
cerebral, 21
malignant, 321
Elbow, after-care of injuries, 188
omission of splint, or retentive apparatus, 189
method of examination, 162
carrying angle, 165
head of radius, 163
measurements, 165
movements at elbow-joint, 165
palpation of the three bony points, 163
summary of order of examination, 166
the three bony points of the elbow region, 163
prognosis, 189
traumatic lesions of, 168
of lower end of humerus, 168
of radius and ulna, 168
symptoms, 169
treatment, 181
acutely flexed position, 182, 187
method of using, 182
precautions in using, 184
Elbow-joint, treatment of, with fracture of shaft of humerus, 155
Embolism, 383
fat, 322
symptoms, 323
treatment, 323
Emergency method of putting up a fracture of the thigh or hip, 283
Emphysema in fracture of nasal bones, 46
of ribs, 95, 99
of superior maxilla, 56
Epicondyle, internal, 172
treatment, 182
Epiphyses, anatomical facts regarding the, 407
acromion process of scapula, 412
date of appearance of ossification in chief epiphyses of long bones (after Poland), 408
femur, lower epiphysis of, 409
humerus, lower epiphysis of, 411
upper epiphysis of, 409
importance of exact knowledge, 408
order of frequency of separation of epiphyses (after Poland), 408
radius, lower epiphysis of, 410
tubia, lower epiphysis of, 412
upper epiphysis of, 412
Epiphysis, fracture of, radial, lower, 235
separation of acromion, 121
Epiphysis, separation of femur, lower epiphysis, 314, 410
anatomy, 315, 410
complications, 316
diagnosis, 316
prognosis, 318
treatment, 318
fat embolism, 322
operative method of reduction, 320
reduction by manipulation when the fragment is displaced forward, 319
traumatic gangrene, septicemia, malignant edema, 321
humerus, 132
lower epiphysis, 175
diagnosis, 178
treatment, 188
upper epiphysis, 132, 140, 146, 409
prognosis, 144
treatment, 140
radius, 195
lower epiphysis, 197, 235, 411
treatment, 197, 209, 235
tibia, 351
lower epiphysis, 356, 412
upper epiphysis, 351
Ethmoid, cribriform plate of, 28
Extension weights after fracture of neck of femur, 271
of shaft of femur, 295
Extravasation of urine, 108, 109

Face, bones of, 44
malar bone, 52
maxilla, inferior, 59
superior, 56
nasal bones, 44
Feeding, after fracture of jaw, by mouth, 70
nasal, 58
Femur, 260
gunshot fracture, 422
mortality, 422
comparative, in different wars, 423
in South African war, 424
prognosis, 424
symptoms, 422
treatment, 423
neck of. See *Hip*.
shaft of, 280
after-treatment and progress, 301
measurement, 282
Dr. Keen's method, 283

Femur, shaft of, symptoms, 282
treatment, 283
Buck's extension apparatus, 288
emergency treatment, 283
method of examination, 287
transportation of a patient, 283
in childhood, 309
symptoms, 309
treatment, 309
Bradford frame, 312
Cabot's posterior wire splint, 310
prognosis, 304
results, 305
fractures of adult life, 307
of childhood, 306
of old age, 307
subtrochanteric fracture, 299
symptoms, 299
treatment, 299
operative, 300
supracondyloid fracture, 300
symptoms, 300
treatment, 300
Flat-foot, traumatic, 404
treatment, 404
Foot, bones of, 400
astragalus, 400
and os calcis, open fracture of, 404
metatarsal bones, 405
os calcis, 401
phalanges, 406
Forearm, bones of:
Colles' fracture, 223
olecranon, 214
radius and ulna, 192
Fragments of bone in open fractures, 376
slightly fixed, 376

GANGRENE of leg, after fracture of femur, 308
of lower leg, 361
treatment, 361
from separation of lower epiphysis of femur, 316, 321
traumatic, 321, 361
Greenstick fracture of bones of forearm, 192
treatment, 213
of clavicle, 112
Gunshot fractures of bone, 413
comparison of old and modern bullet, 418
explosive effect of bullet, 415
factors upon which amount of damage to bone is dependent, 413
Gunshot fractures of bone, factors upon which amount of damage to bone is dependent, resistance, 415
revolution of bullet, 414
shape of bullet, 413
velocity of bullet, 413
prognosis in fractures of femur 424
ricochet bullet, 417
the modern rifle, 413
treatment, 419
first field dressing, 419
fracture of femur, 423
infected wounds, 421
noninfected wounds, 420
operative, 421
wounds of entrance and exit, 417
of modern projectiles less grave, 419

HEAD injury, cases of, 39
I. Middle meningeal hemorrhage with fracture of skull, 39
II. Open depressed fracture of skull; paralysis of one-half of body, 41
III. Middle meningeal hemorrhage; fracture of skull, 43
Heel, care of, in treatment of fracture of leg, 366
of Pott's fracture, 394
Hematoma of cartilaginous septum of nose, 51
of scalp, 24
Hematomyelia, 87
Hemorrhage, extradural, 19, 88
sources of, 20
symptoms of, 19
in fracture of base of skull, 26, 28
of humerus, 150
of leg, 360
into pharynx, 29
into spinal cord, 86
hematomyelia, 87
middle meningeal, cases of, with fracture of skull, 39, 43
subconjunctival, 28, 29, 55
Hip, or neck of femur, 260
anatomy, 260
fracture in adults, 260
examination, 263
impacted and unimpacted. 261
measurement, 264
Bryant's method, 265
prognosis and result, 268

Hip, fracture in adults, results after, 268
symptoms, 261
treatment, 269
after-care of the simple traction method, 271
fixation method, 272
Thomas hip-splint, 273
general considerations, 269
operative treatment, 277
treatment of the fractured hip, 271
fracture in childhood, 277
immediate result, 280
late result, 280
symptoms, 280
treatment, 280
Hot-air treatment, 245, 404
Humerus, 125
after-care, 143, 147
anatomical neck of, 132, 146
treatment, 140
with dislocation of upper fragment, 146
after-treatment of operated cases, 147
treatment, 146
anatomy, 125
diagnosis, 129
examination of shoulder, 126
prognosis and result, 144
shaft of, 147
fracture in the newborn, 158
treatment, 158
(transverse) above the condyles, 173, 186
treatment, 186
malignant disease, 162
musculospiral nerve in fracture of the humerus, 159
prognosis, 157
symptoms, 148
treatment of fractures with considerable displacement, 156
after-care, 157
operative, 156
with little or no displacement, 151
after-treatment, 156
simple dislocation of humeral head, subcoracoid, 131
surgical neck of, fracture of, 140, 146
treatment, 140
with dislocation of upper fragment, 146
after-treatment of operated cases, 147
treatment, 146
Humerus, surgical neck of, oblique fracture, with great displacement, 146
treatment, 146
operative, 146

ICE-BAGS, 362
Ilium, 103
Infection in fracture of metatarsal bones, 406
of nasal bones, 46, 50, 51
of superior maxilla, 57
in gunshot fractures, 419, 420
of femur, 424
in open fracture of leg, 375

KEEN'S method of measuring lengths of lower extremities, 283
Kocher's classification of parts of long bones injured in gunshot wounds, 415
Krause, quoted: advantages of ambulatory treatment, 468
table containing average periods of healing, 467

LA GARDE, quoted: wounds of modern projectiles, 418
Lee-Metford (English) bullet, size, 418
velocity, 418
weight, 418
Leg, 346
anatomy, 346
examination of fractured leg, 351
general observations, 350
Pott's fracture, 384
prognosis, 380
results, 381
refracture, 384
thrombosis and embolism, 383
symptoms, 353
treatment, 356
after-care, 379
care of fracture of the leg after the permanent dressing has been applied, 377
fractures difficult to hold reduced, 370
fractures with considerable immediate swelling, 359
permanent dressing, 364
care of heel, 366
temporary dressing, 362
in fractures with little or no displacement or swelling, 357

Leg, treatment, open fractures, 374
permanent dressing, 374
temporary dressing, 374
wound of soft parts, 375
Limitation of motion after Colles' fracture, 244, 245
after fracture of bones of forearm, 212
of elbow, 190
of olecranon, 222
of patella, 340, 344
of scaphoid bone of wrist, 247, 249
after open fracture of astragalus and os calcis, 405
after separation of lower epiphysis of femur, 321

MacCormac (Sir William), quoted: treatment of gunshot fracture of femur, 422
Makins (George Henry), quoted: gunshot wounds in South African war, 416
gunshot fracture of femur, 422
prognosis, 424
treatment by amputation, 422
Malar bone, 52
complications, 55
examination, 52
symptoms, 53
treatment, 55
Malignant disease, 162
Massachusetts General Hospital, cases treated at:
results after fracture of femur, 305
of hip, 268
of leg, 381
of patella, 341
statistics concerning ambulatory treatment, 467
Massage after fracture of astragalus, 400
of bones of forearm, 210
of clavicle, 119
of elbow, 189
of humerus, 144, 147, 157
of leg, 378
of metacarpal bones, 257
of patella, 331, 336
with operative treatment, 345
of ribs, 99
of scapula, 124
of shaft of femur, 302
after Pott's fracture, 397
after separation of lower epiphyses of femur, 321
in Colles' fracture, 242, 245
in fracture of carpus, 248
of olecranon, 220
Massage in fracture of os calcis, 404
Materials for ordinary care of closed fractures, 469
Mauser bullet, revolution of, 415
size, 418
velocity, 418
weight, 418
Maxilla, inferior, 59
examination, 60
fracture of body of jaw, 62
of ramus upon same or opposite sides of inferior maxilla, 70
of coronoid and articular processes, 71
of ramus, just behind molar teeth, 69
symptoms, 60
treatment, 61, 62, 69, 70, 71
superior, 56
after-care, 58
diagnosis, 56
treatment, 57
Measurement in Colles' fracture, 225
in dislocation of humeral head, 131
in fracture of elbow, 165
of external condyle, 173
of humerus, 129, 150
of leg, 353
of neck of femur, 264
of shaft of femur, 282, 295, 301
in Pott's fracture, 386
in T-fracture into elbow-joint, 180
Metacarpal bones, 249
differential diagnosis, 253
symptoms, 249
treatment, 253
Metatarsal bones, 405
complications, 406
symptoms, 405
treatment, 406
Morphin, use of, 369
Musculospiral nerve in fracture of humerus, 159
prognosis, 160
symptoms of injury, 159
compression, 160
contusion, 159
treatment, 160
operative, 160

Nancrede, quoted: gunshot wounds of bones, 417, 421
Nasal bones, 44
anatomy, 44
complications, 46
prognosis, 51
symptoms, 46
treatment, 49
septum in fracture of nose, 47
dislocation, 47

Nasal septum, lesions, 48
horizontal fractures, 48
sigmoid deviations, 48
treatment, 49
vertical fractures, 48
Necrosis after fracture of humerus, with dislocation of upper fragment, 147
of leg, 381
of lower jaw, 61
of metatarsal bones, 406
of upper jaw, 57
after separation of lower epiphysis of femur, 316, 318
in open fractures of the phalanges, 259
Nerves, lesions of, 28, 29
after separation of lower epiphysis of femur, 316
in fracture of base of skull, 28 29
of humerus, 159
of the vertebræ, 74
spinal, anatomy, 74
Nonunion of fracture of clavicle, 120
operative treatment, 120
of hip, 268
of leg, 380
of fractures, 212
causes, 213
treatment, 213
operative, 213, 222
Nose, deformity of, from fracture, 44, 47, 51
from syphilis, 46
Nussbaum, von, quoted: first dressing of gunshot wounds, 419

OLECRANON, 214
after-care, 220
anatomy, 214
process, 171
summary of treatment, 222
symptoms, 214
treatment, 217
if fracture is open, 220
operative, 219
Orbital plate, 27
Os calcis, 401
open fracture, 404
treatment, operative, 405
results, 404
flat-foot, 404
symptoms, 402
treatment, 403

PARALYSIS in fracture of skull, 18, 34
in fractures of vertebræ, 76
cervicodorsal region, 80
dorsal, 79
Paralysis in fractures of vertebræ, last dorsal and lumbar, 77
midcervical region, 81
in lesions of spinal cord, 82
obstetrical, 159
of musculospiral nerve, in fracture of humerus, 148, 159
Passive motion after Colles' fracture, 242, 245
after fracture of astragalus, 400
of bones of the forearm, 210
of carpus, 248
of clavicle, 119
of elbow, 189
of femur (shaft), 302, 303
of humerus, 147, 157
of leg, 378
of olecranon, 221
after Pott's fracture, 397
after separation of lower epiphysis of femur, 321
in fracture of patella, with operative treatment, 345
Patella, 324
anatomy, 324
open fracture, 338
treatment, 338
operative interference in recent closed fractures, 342
conditions suitable, 344
danger of sepsis, 343
indications, 345
method of operation, 345
proper time to operate, 344
restoration of function of joint following operative treatment, 345
prognosis, 339
results, 341
symptoms, 328
treatment, 329
limitation and removal of effusion, 329
maintenance of reduction until union is satisfactory, 334
reduction of fragments, 332
restoration of function of joint, 336
summary of treatment by expectant or nonoperative method, 337
Pelvis, 103
complications, 106
rupture of urethra, 107
of urinary bladder, 108
visceral lesions, 106
examination, 103
prognosis, 109
treatment, 105

Phalanges, 257, 406
of the foot, 406
treatment, 406
of the hand, 257
open fracture, 259
operative treatment, 259
symptoms, 257
treatment, 257
Plaster-of-Paris bandage after separation of lower epiphysis of femur, 321
in fracture of leg, 357, 359
employment of, 441
application to patient, 458
dextrin bandage, 460
making of bandages, 441
removal of the plaster splint, 460
rolling the plaster, 441
shoulder cap, 141
splint, traction, early use, 462
method of application, 372
Pleurisy in fracture of ribs, 95
Pneumonia, asthenic hypostatic, 271
Poland, John (his "Traumatic Separation of the Epiphyses" quoted), 408
Pott's fracture, 384
anatomy, 384
lesions which may be present, 384
open fracture, 398
indications for amputation, 398
operative treatment of old fractures, 398
prognosis and results, 398
symptoms, 385
treatment, 386
care, after permanent dressing is applied, 396
Dupuytren splint, 387
lateral and posterior plaster-of-Paris splints (Stimson's splint), 394
posterior wire splint with curved foot-piece, 393
temporary dressing, 387
Pubic portion of ring of pelvis, 105

RADIO-ULNAR joint, inferior, involvement of, in Colles' fracture, 244
Radius and ulna, dislocation of, 169, 194
fracture of, 192
of coronoid process of ulna, 198
of neck and head of radius, 194
symptoms, 194
treatment, 188, 208
of neck or head of, 172, 194
Radius and ulna, fracture of shaft of radius, 195
symptoms, 195
treatment, 208
operative, 209
of shaft of ulna, 197
incomplete or greenstick fracture, 192
prognosis and result of treatment, 211
separation of lower epiphysis of radius, 195
symptoms, 192
treatment, 201
of open fractures, 211
subluxation of head of radius, 169, 194
Reflexes in fractures of the vertebræ, 76
dorsal, 80
Refracture of bones of the lower extremity, 384
Retention and incontinence, in fractures of the vertebræ, 77
Ribs, 94
anatomy, 94
complications, 95, 99
symptoms, 94
treatment, 95
after-treatment, 99
operative, 99
Roe's elevator, 49
Röntgen ray and its relation to fractures, 425
assistance of, in diagnosis, 432
in examination, 432
in knowledge of pathology and treatment of fractures, 431
Crooke's tube, 426
effects of X-rays, extent of, 427
accuracy and inaccuracy of pictures, 431
distortion of shadows, 427, 434
fluoroscope, 426, 434
forms of fracture in which X-ray gives great assistance, 433
elbow, 434
femur, upper extremity of, 435
foot, bones of, 436
patella, 435
shoulder-joint, 433
wrist, 435
medicolegal relations of X-rays; conclusions expressing views of American Surgical Association adopted in May, 1900, 438
use of, as a method of record in rare fractures, 433

Röntgen ray, use of, in demonstrating to students, 432
X-ray burns and dermatitis, 436
X-ray picture and photograph, comparison of, 426
Röntgen rays in Colles' fracture, 231, 232, 233, 238, 435
in fracture of astragalus, 400
of carpus, 246, 435
of coronoid process of ulna, 201
of elbow, 181, 434
of humerus, 130, 434
of neck and head of radius, 194
of neck of femur, 267
in gunshot fractures, 420
in knowledge of epiphyses, 407, 435

SAND-BAGS, 271, 293
Sayre dressing (modified) in fracture of clavicle, 116, 118
Scaphoid bone of wrist, 246
diagnosis, 246
Scapula, 121
acromial process, 121
body of scapula, 121
neck of scapula, 121
treatment in general, 123
Sepsis. See *Infection*.
Septicemia, 321
Shock after fracture of jaw, 58
of neck of femur in the aged, 268
of pelvis, 107
of shaft of femur, 308
of the vertebræ, 76, 93
after gunshot fracture of femur, 422
after rupture of urinary bladder, 108
after separation of lower epiphysis of femur, 316
Shortening of the leg after separation of lower epiphysis of femur, 318
in fracture of leg, 353, 380
of neck of femur, 262, 265, 268, 277, 278
correction, 275
of shaft of femur, 282, 305
prevention, 295
Skull, 17, 22
compression of brain, 18
concussion and contusion of brain, 17
diagnosis, 33
examination of patient, 31
general condition, 32
local condition, 32
fracture of base, 26, 59
of vault, 24
Skull, general observations, 33
hemorrhage, extradural, 19
laceration of brain, 18
later results of fracture, 38
operative interference, 36
prognosis, 38
subarachnoid serous exudation (cerebral edema), 21
treatment, 34
ear, 35
mouth, 36
nose, 35
scalp, 35
unconsciousness resulting from other than surgical causes, 30
Slings for Colles' fracture, 240
for fractured humerus, 155
Smith anterior wire splint, 369
Spinal cord, anatomy, 72
lesions of, 73, 82, 93
how to localize, 73
transverse and partial, 82
symptoms, 82
treatment, 85, 93
operative, 85, 87, 93
Spine, injury to, examination, 76
Splints for Colles' fracture, 239, 244
for fracture of astragalus, 400
of bones of forearm, after-care of wooden and tin splints, 207
in greenstick fractures, 214
internal right angle (of tin), 206, 209
palmar and dorsal (of wood), 205, 208
method of application, 206
plaster-of-Paris, 202, 208
after-care, 203
precautions in using, 202
of carpus, 248
of elbow, internal right angle, 186, 187
application of, 187
right-angle internal angular, 181
of humerus, coaptation, 156
internal angular, 156
plaster-of-Paris, 157
application of, 157
of jaw, buckle and strap, 69
chin-piece, 64
dental, 57, 62
making of, 67
temporary, 58
of leg, pillow and side, 362
plaster-of-Paris, 357, 363, 368, 372, 377
posterior wire and side, 364, 377
of metacarpal bones, 255

Splints for fracture of metatarsal bones, 406
of olecranon, internal right-angle, 218
long internal, 218
of os calcis, 404
of patella, 332
in open fracture, 336
plaster-of-Paris, 335
method of making, 335
of phalanges of foot, 406
of hand, 258
of shaft of femur, Buck's extension apparatus, 289
emergency, 283
application, 283
permanent dressing, 286
for Pott's fracture, Dupuytren, 387
application of, 391
defect of, 393
lateral and posterior plaster-of-Paris (Stimson's splint), 394
posterior wire, with curved foot-piece, 393
application of, 393
nasal, 50
Cobb's, 50
Coolidge's, 50
tin, 50
Sponge compresses in fracture of patella, 330
Sprain of wrist, 231
Sternum, 100
complications, 101
diagnosis, 101
treatment, 101
operative, 102
Stimson's splint, 394
Subarachnoid serous exudation, 21
Subluxation of head of radius, 169, 194
Suturing fractured bone, humerus, 156
jaw, 59
leg, 373, 376
radius and ulna, 209, 211
Synovitis in fracture of patella, 329
treatment by aspiration, 334
by massage, 331

TAYLOR hip traction splint, 303
application of, 303
use of, in ambulatory treatment of fracture of thigh, 303, 466, 468
steel back-brace, 102
Teeth, after fracture of jaw, 57, 60, 61
Temperature, pulse, and respiration in fracture of skull, 18, 34, 38
Temporal bone, fracture of petrous portion of, 28
Tenotomy of tendo Achillis, 372
Tetanus after a fracture, 223
treatment, 223
T-fracture into elbow-joint, 180
treatment, 182
Thomas hip-splint, 273
application, 275
description, 273
knee-splint, 462
Thomson (Prof. Elihu), quoted: effects of X-rays on the tissues; a personal experiment, 437
Three bony points of elbow region, 163
Thrombosis, 383
Tibia, oblique fracture of, 370
Trephining in fracture of vertebræ, 89
T-splint, 106, 271, 289

ULNA, shaft of, symptoms, 197
treatment, 209
Union of bones, time necessary for, after separation of lower epiphysis of femur, 321
in Colles' fracture, 243, 244
in fracture of astragalus, 401
of bones of forearm, 209
of elbow, 189
of humerus, 144
in the new-born, 159
shaft, with considerable displacement, 157
with little or no displacement, 156
of leg, 378
of metatarsals, 405
of olecranon, 222
of os calcis, 404
of patella, 334
with operative treatment, 345
of phalanges, 259
of shaft of femur, 301
in greenstick fracture of forearm, 214
in refractures, 384
Ununited fractures. See *Nonunion*.
Urethra, injury to, in fracture of pubic bone, 105
rupture of, in fracture of pelvis, 107
extravasation, 108
symptoms, 107
treatment, 107

VAULT of skull, 24
Vertebræ, fractures of, 72
anatomy, 72
dislocations of, 73
examination of an injury to the spine, 76

Vertebræ, general symptoms common to fractures of the, 76
gunshot fractures, 93
treatment, 93
lesions following injury to definite vertebræ; with table, 75
prognosis, 81
symptoms of fracture of different regions of the spine, the cord being involved, 77
injuries to cervicodorsal region, opposite cervical enlargement of spinal cord, 80
to the dorsal vertebræ, 79
to the first two cervical vertebræ, 81
to last dorsal and lumbar vertebræ, 77
operation, time for, 79
prognosis, 77
Vertebræ, symptoms of fracture, injuries to midcervical region, 80
treatment, 81
plaster-of-Paris jacket, 90
method of applying, 91
summary, 93
Vertical suspension in fracture of thigh in childhood, 312
Visceral lesions in fractures of pelvis, 106
V-shaped pad, in fracture of humerus, 141, 153

WIRING fractured bones of the jaw, 59, 62, 71
of the pelvis, 106
Wounds of open fractures, cleansing, 375, 399

LANE MEDICAL LIBRARY

This book should be returned on or before
the date last stamped below.

M101 Scudder, C.L. 1013
S436 The treatment of
1902 fractures.

NAME	DATE DUE

ATTIC
ATTIC